

Colon & Rectum Questions

Vinod A Winston, M.D
Department of Surgery
vwinston@lumc.edu

Question:

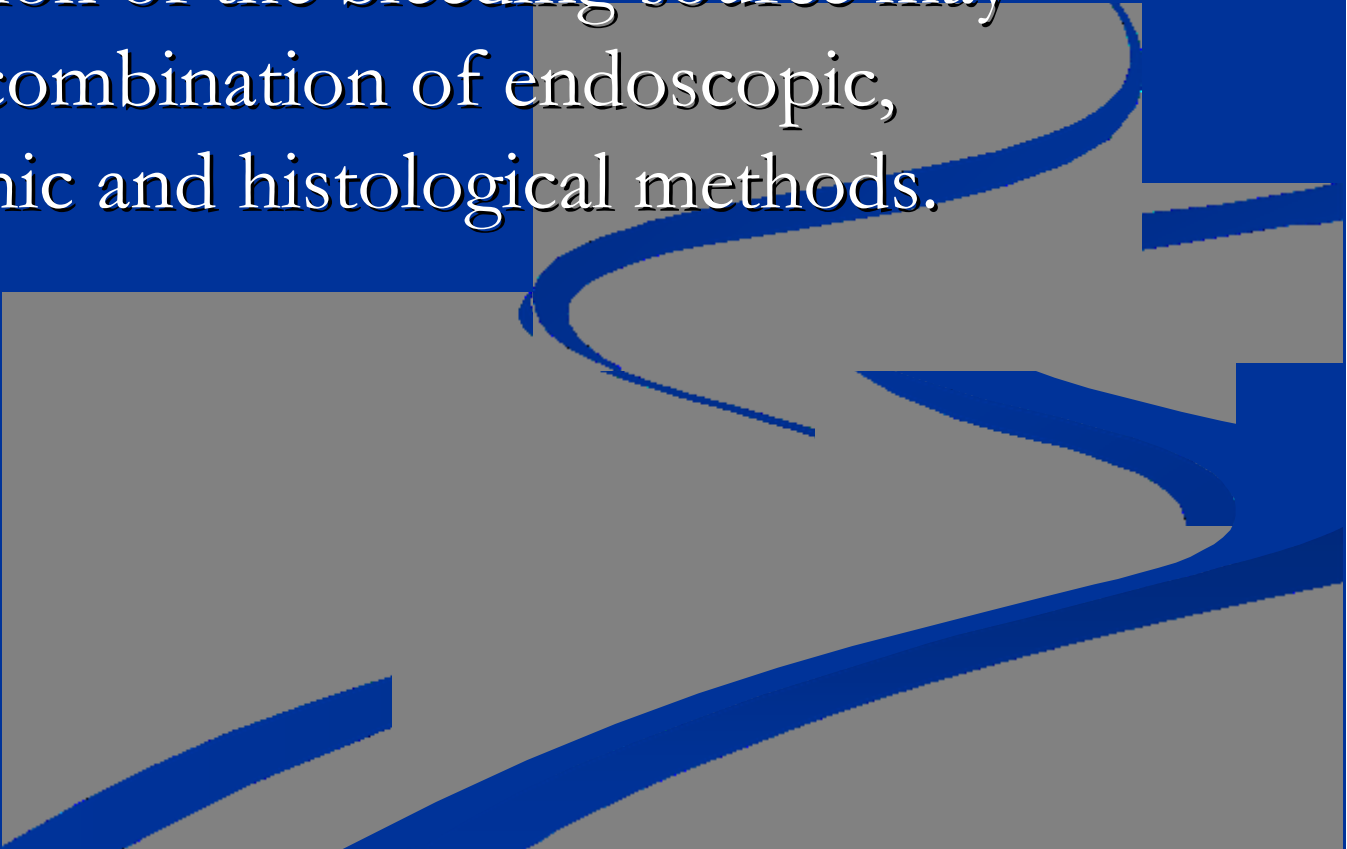
Which of the following is/are the most common causes of massive colonic bleeding?

- A. Cancer
- B. Ulcerative colitis
- C. Diverticulosis
- D. Diverticulitis
- E. Angiodysplasia



Answer: C, E

Diverticulosis and angiodysplasia can coexist. Both cause painless bleeding. Exact identification of the bleeding source may require a combination of endoscopic, radiographic and histological methods.

An abstract graphic in the bottom right corner of the slide. It features several thick, wavy, blue lines that flow from the right side towards the left, set against a background of gray and dark blue geometric shapes. The lines have a slight 3D effect with lighter blue highlights.

Question:

In the US, what is the most common cause of mechanical obstruction of the colon ?

- A. Adhesions
- B. Diverticulitis
- C. Cancer
- D. Volvulus
- E. Inguinal hernia



Answer : C

Whenever a patient presents with intestinal obstruction, one first attempts to define the level of obstruction (i.e. SB vs LB). LBO is often suggested by the gas pattern on plain X-rays and can be confirmed by a carefully performed enema with water-soluble contrast. **Barium should not be used.** One concern is causing peritonitis in the presence of a perforating lesion; another concern is inspissation proximal to a partially obstructing cancer, effectively converting a partial obstruction to a complete one.

A neglected obstruction from any cause can be fatal. Colon obstruction in the presence of a competent ileocecal valve creates a closed loop phenomenon; progressive distention of the colon between the point of obstruction and the ileocecal valve may lead to necrosis and perforation of the colon wall.

Question:

68 year old man is admitted to the ER having had three large maroon colored stools. On arrival, he passes more bloody stools and clots. He is pale, orthostatic and tachycardic. NG aspirates are bilious. After resuscitation is begun, which of the following is the most appropriate initial test?

- A. Angiography
- B. Nuclear medicine red blood cell scan
- C. Rigid proctoscopy
- D. Colonoscopy
- E. Barium enema

Answer: C

Proctoscopy may reveal an anorectal source of the bleeding. Colonoscopy is for a stable patient who is not bleeding profusely. RBC scan may be done if no obvious anorectal source responsible for the massive bleeding is noted. Bleeding has to be at rate of 0.1 ml/min, for a bleeding scan to be positive.

Question:

A definite increased risk of developing colon cancer is associated with which one or more of the following?

- A. Diet high in fiber
- B. Diet low in animal fat & protein
- C. Ulcerative colitis
- D. Familial polyposis
- E. Strong family history of colon cancer in several preceding generations

Answer: C, D, E

Diet low in fiber and high in animal fats and protein are associated with an increased risk of colorectal cancer.

In patients with familial adenomatous polyposis (FAP), 100% will develop colorectal cancer by 45 years of age.

Patients with hereditary non-polyposis colon cancer (HNPCC) has a 70%-80% lifetime risk of developing colorectal cancer.

Risk factors for the development of cancer in patients with ulcerative colitis include

- disease of long duration (increases by 1-2% per year after 10 years)
- total colonic involvement

Question:

Select the most common mode of spread of colon cancer

- A. Hematogenous
- B. Lymphatic
- C. Direct extension
- D. Implantation



Answer: B

The lymphatic route to regional mesenteric lymph nodes is the most common. This fact has surgical importance because it dictates the extent of resection necessary when operating with a curative intent.

Hematogenous spread to the liver, lung and other structures are possible.

Direct extension to adjacent structures can occur with or without distant metastasis; with the latter, en bloc resection of portions of these organs may be necessary.

If the cancer has broken through the serosal surface, locally or widely, can result, accounting for metastatic deposits

- in the rectovesical pouch (Blumer's shelf),
- to the peritoneum under the umbilicus (Sister Joseph's nodule),
- to the ovary (Krukenberg's tumor, originally described for metastasis from the stomach to the ovary).

Question:

Which of the following is the most important prognostic determinant of survival after treatment for colorectal cancer?

- A. Lymph node involvement
- B. Transmural extension
- C. Tumor size
- D. Histologic differentiation
- E. DNA content

Answer: A



Question:

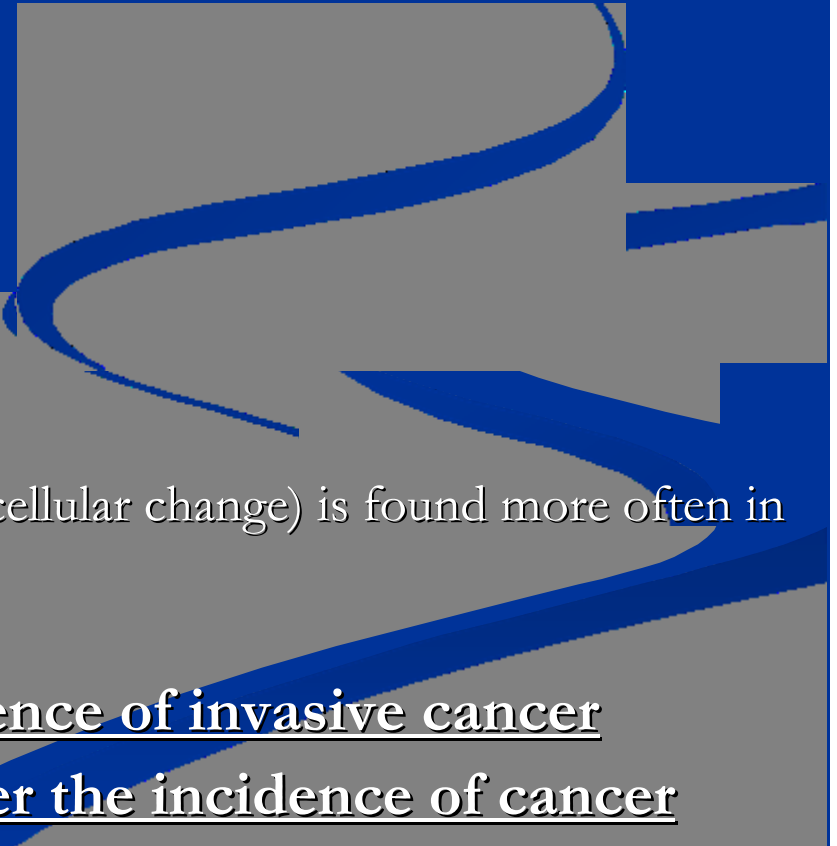
With regard to colorectal polyps, which of the following is/are considered precancerous ?

- A. Hyperplastic polyp
- B. Tubular adenoma
- C. Tubulovillous adenoma
- D. Villous adenoma



Answer: B, C, D

- Colorectal polyps can be
 - sporadic or hereditary
 - neoplastic (tubular, tubulovillous, villous adenomas) or non-neoplastic (hyperplastic, hamartomatous, pseudopolyps)
- Most common type of all colorectal polyps - Hyperplastic polyps
- Tubular adenoma : 65-80%
 - most common neoplastic polyp
 - are most often pedunculated
 - generally less atypia in tubular adenomas
- Tubulovillous : 10-25%
- Villous adenomas : 5-10%
 - are more commonly sessile
 - severe atypia or dysplasia (precancerous cellular change) is found more often in villous adenomas
 - 40-50% will harbor occult malignancy
- Bigger the polyp, higher the incidence of invasive cancer
- More the villous component, higher the incidence of cancer



Question:

With regard to ischemic colitis, which of the following statements is/are true?

- A. The most common symptoms are lower abdominal pain and bright red rectal bleeding
- B. Occlusion of the major mesenteric vessels is responsible for producing the ischemia in most cases
- C. The splenic flexure and descending colon are the most vulnerable areas, although any segment of colon may be involved
- D. Non-operative management is not justified because in significant percentage of cases perforation and peritonitis eventually develop

Answer:

A, C



Question:

An exploratory laparotomy is done for an unlocalized massive hematochezia. Pre-op angiography did not reveal a source of bleeding. At surgery a large right-sided diverticulum is seen with more blood pooling in the right colon than the left colon. The procedure of choice is

- A. Right hemicolectomy
- B. Right hemicolectomy with intra-op small bowel enteroscopy to rule out a small bowel source
- C. Do inferior mesenteric artery ligation and observation
- D. “Blind” total abdominal colectomy
- E. Do another angiogram in the OR to localize the bleed

Answer: D

Patient with hematochezia pose a challenging clinical problem. After ruling out an UGI source of bleed with EGD, all efforts to localize the source of bleed should be sought. At laparotomy, external exam of the small bowel and the colon cannot identify the source of bleed. Even the findings of right or left-sided diverticuli and the presence of pooling in any segment of colon does not adequately assist with localization. Intra-operative enteroscopy is rarely successful in the acute setting. The most appropriate step is blind total abdominal colectomy to resect the region of the bowel most likely to harbor the bleeding site, namely the colon, either from an angiodysplasia or bleeding diverticulum. Never do a blind segmental colectomy.

Q: A 68-year-old African American man presents to his primary care physician for a routine physical examination. The patient's medical history is significant for hypertension. The patient is found to have guaiac-positive stools and is subsequently referred for colonoscopy. Colonoscopy reveals a "golf ball"-size, near-obstructing tumor in the descending colon, not admitting the scope. The biopsy is positive for adenocarcinoma of the colon.

1. Which of the following is the next step in the management of this patient?

- A. Full metastatic workup first, and if negative, then plan for colon resection
- B. A course of radiation therapy prior to any resection
- C. Plan for pre-operative chemotherapy
- D. Do metastatic work up, but plan for colon resection anyway
- E. Schedule a barium enema to evaluate the proximal colon

Answer: D

The goals of surgical excision of colon cancer are to both

- cure the disease
- alleviate symptoms.

Even if there is metastatic disease at the time of surgery, it is important to remove the primary tumor to prevent complications (e.g., obstruction, bleeding). A metastatic workup is needed, but this patient needs colon resection as he has an impending obstruction. Surgery can be done laparoscopically or by laparotomy.

Patients with stage I and low-risk stage II cancers do not need additional therapy. Patients with high-risk stage II and stage III cancers can be treated with adjuvant chemotherapy. Radiation therapy is ineffective as adjuvant therapy for patients with colon cancer; and is only beneficial in patients with rectal cancer.

It is important to rule out a synchronous lesion by colonoscopy or double contrast barium enema (DCBE). DCBE is not advisable in this patient as an impending obstruction can become a complete obstruction if barium gets inspissated proximal to the near obstructing tumor. This patient needs to have a colonoscopy 3-6 months after colon resection.

2. After the appropriate evaluation, the patient undergoes surgery. No intraoperative evidence of metastases is identified. Postoperatively, the pathology report reveals that the tumor is an adenocarcinoma invading into the pericolonic fat, with 2 involved lymph nodes. After the patient recovers from surgery, which of the following is the most appropriate next step in his management?

- A. Abdominal CT scan every 6 months
- B. No further therapy is indicated, because the involved nodes were removed
- C. Chemotherapy with 5-fluorouracil (5-FU) based regimen
- D. Measurement of CEA levels yearly
- E. Colonoscopy every 6 months

Answer: C

The lesion described by the pathology report is a T3 N1 M0 lesion i.e., extending beyond the muscularis propria and into the pericolonic fat within the sleeves of the mesentery, and 1 to 3 positive nodes. This is a stage III tumor.

About 25% of patients with stage II tumors and 50% of patients with stage III tumors eventually die from growth of micrometastatic disease that was present at the time of primary tumor resection. Patients with stage III disease have improved disease-free and overall survival rates if treated with a combination of 5-FU and other agents.

60-80% of colon cancers that recur do so within 2 years of surgery, and 90% of the recurrences are evident by 3 years. Therefore, routine follow-up after a potentially curative operation should include

- history and physical examination, measurement of CEA levels, every 3 months for 2 years, then every 6 months for a total of 5 years.
- Chest/abdomen/pelvis CT scan is done annually for 3 years for high-risk patients.
- Colonoscopy should be done in 1 year, and repeat yearly if abnormal and every 3 years once it is normal.

Question:

A 65-year-old woman with no significant past medical history presents to the emergency department with a 2-day history of left lower quadrant abdominal pain. The patient denies nausea and vomiting, although she claims decreased oral intake. She also reports a low-grade fever and mild diarrhea. She describes a milder episode several years ago, which resolved on its own. On physical examination, the patient is found to have left lower quadrant tenderness with some mild guarding, but no rebound. She is hemodynamically stable, and her heart rate is 82 per minute. In the initial management of this patient, which of the following is the most sensitive diagnostic test?

- A. Complete blood count, SMA-7
- B. An obstructive series
- C. A barium enema study
- D. Abdominal/pelvic CT with oral contrast
- E. Abdominal ultrasound

Answer: D

A CT scan with oral contrast is the test of choice.

Although a WBC count may demonstrate an infectious etiology, it is a relatively nonspecific test. A normal WBC count does not exclude an infectious process, and it is common for patients to have an increased WBC count because of factors such as dehydration. The SMA-7 electrolytes are also nonspecific and are of limited use in determining the diagnosis of this patient's abdominal symptoms.

Abdominal films are most helpful for patients suspected of perforation or intestinal obstruction and for patients in whom the diagnosis is uncertain. AxR may demonstrate free air, which suggests an intestinal perforation. The use of ultrasound is limited in this situation. It is the test of choice if gallbladder pathology is suspected. The kidneys, liver, and pancreas may also be evaluated with ultrasound; however, intestinal pathology is not well visualized with ultrasound.

This patient most likely has an episode of acute diverticulitis. Because of the risk for perforation or peritonitis, barium enemas and sigmoidoscopy are usually reserved for patients who have recovered from an attack of acute diverticulitis.

Other considerations in the differential diagnosis should include ischemic colitis, irritable bowel syndrome, appendicitis, inflammatory bowel disease, and pyelonephritis. All these diagnoses will be better delineated with the use of CT scan.

Question:

A 60-year-old man presents for an annual physical examination. The examination is normal except for a palpable mass in the rectum on digital rectal examination. The patient denies any change in bowel habits and feels well. Rectal cancer is suspected. What is the next best step in the evaluation of this patient?

- A. Computed tomography scan of the abdomen and pelvis
- B. Double-contrast barium enema
- C. Flexible sigmoidoscopy with biopsy of the lesion
- D. Full colonoscopy with biopsy of the lesion
- E. Magnetic resonance imaging scan of the abdomen and pelvis

Answer: D

Full colonoscopy with biopsy of the lesion.

The patient has a rectal mass of unclear etiology. Double-contrast barium enema may reveal the mass but will not allow a biopsy to be obtained. A CT or MRI scan of the abdomen is warranted once a diagnosis of rectal cancer is made to assess the extent of disease, but ordering them at this stage is premature. Flexible sigmoidoscopy allows visualization and biopsy of the lesion, but a full colonoscopy would accomplish both of these goals and also allows examination of the entire colon to rule out any synchronous lesions that also may require treatment.

Question:

A 78-year-old woman with coronary artery disease and severe chronic obstructive pulmonary disease is admitted to the hospital with painless jaundice. CT scan reveals the presence of multiple lesions in the liver, suggestive of metastases, and a nearly obstructing upper rectal mass. Colonoscopy demonstrates a large, ulcerated tumor in the proximal rectum and a residual lumen of less than 1 cm in diameter. While in the hospital, the patient develops a large bowel obstruction. What is the best treatment modality for this patient?

- A. Immediate radiation therapy of the rectal mass
- B. Placement of a colonic decompression tube
- C. Emergency surgery with resection of the mass
- D. Emergency surgery with creation of a diverting colostomy
- E. Placement of a rectal self-expanding metal stent

Answer: E

Placement of a rectal self-expanding metal stent.

The patient has developed malignant large bowel obstruction secondary to her rectal cancer. A self-expanding metal stent allows both immediate bowel decompression and subsequent palliation of the tumor. A colonic decompression tube would relieve the acute obstruction but would not provide a long-term solution for the patient. Emergency surgery could be performed but would be less than ideal given the patient's comorbidities and advanced cancer. Radiation therapy is not a treatment for an acute large bowel obstruction.

Question:

A 55-year-old man is hospitalized with a first attack of acute diverticulitis. He has acute left lower abdominal pain with a palpable tender mass just above the left groin area. Steps in his management during the first 24 h after admission should include intravenous fluids and

- A. broad-spectrum antibiotic therapy
- B. diagnostic colonoscopy
- C. an enema to evacuate any retained stool
- D. nasogastric suction
- E. sigmoid resection once he is well-hydrated

Answer : A

Acute diverticulitis severe enough to warrant hospitalization requires intravenous fluid replacement and broad-spectrum antibiotic therapy. Unless there is small bowel obstruction from a loop of intestine adherent to the inflammatory mass, a nasogastric tube is not necessary. The patient should respond promptly to appropriate management. Emergency operation is not necessary. Once the process has subsided, colonoscopic examination or barium enema can be done electively.

Question:

A 57-year-old man is found to have a rectal mass 3 cm from the anal verge on digital rectal examination. Subsequent colonoscopy and biopsy confirm rectal adenocarcinoma. EUS examination demonstrates penetration of the tumor into, but not through, the muscularis propria, but shows significant perirectal lymph nodes. CT scan of chest/abdomen/pelvis demonstrates no metastases. The patient is staged as T2N1M0. What procedure should be attempted to remove the primary lesion in this patient?

- A. Endoscopic mucosal resection (EMR) to remove the lesion
- B. Endoscopic argon plasma coagulation (APC) therapy to cauterize and ablate the lesion
- C. Surgical transanal excision of the lesion
- D. Neo-adjuvant chemoradiation followed by transanal excision
- E. Neo-adjuvant chemoradiation followed by abdominoperineal resection (APR)

Answer: E

Neo-adjuvant chemoradiation followed by APR.

The patient has stage III rectal cancer (positive regional lymph node involvement), thus excluding limited attempts at excision of the lesion (endoscopic approaches or surgical transanal excision). An APR is the appropriate surgery for this patient. Opinion diverges about the use of neoadjuvant chemoradiation or adjuvant chemoradiation in a patient with Stage II or III rectal cancer. However, neoadjuvant therapy is preferred by most oncologists. Most patients (stage 2 and above) need adjuvant chemotherapy even if they had neoadjuvant chemoradiation.

Question:

A 70-year-old man is found to have distal rectal cancer during a screening colonoscopy. The patient undergoes preoperative staging and is found to have a 1.5-cm rectal mass that does not invade the muscularis propria of the rectal wall. There is no regional lymphadenopathy and no evidence of distant metastases. The patient is staged at T1N0M0. The patient is advised to undergo APR but refuses because it will lead to anal sphincter loss and permanent colostomy. Which of the following represents a viable alternate therapeutic option for this patient?

- A. Chemotherapy alone
- B. Radiation therapy alone
- C. Chemoradiation therapy
- D. Full-thickness surgical removal of tumor (transanal excision)
- E. Endoscopic ablation of the tumor with APC
- F. Tell the patient he needs an APR as he has cancer

APC – Argon Plasma Coagulator

Answer: D

Full-thickness surgical removal of the tumor. The patient has a mass lesion that should be removed entirely. Chemotherapy, radiation therapy, and combination chemoradiation therapy cannot guarantee complete destruction of the mass. Endoscopic ablation of the tumor with APC does not guarantee complete destruction and would not provide evidence of clear tissue margins. Only a full-thickness surgical removal of the tumor is an appropriate alternative to APR in this patient.

Question:

A 70-year-old man with severe atherosclerosis who takes 1 baby aspirin (81 mg) daily undergoes cardiac catheterization because of chest pain. Later in the day, he develops severe abdominal pain and passes a large amount of bloody diarrhea. Physical examination reveals no peritoneal signs. Which of the following is the most likely cause of the patient's bleeding?

- A. Colon cancer
- B. Diverticulitis
- C. Hemorrhoids
- D. Mesenteric ischemia
- E. Nonsteroidal anti-inflammatory drug enteropathy

Answer: D

Mesenteric ischemia.

Mesenteric ischemia and small bowel infarction can develop as a consequence of mesenteric artery embolization. Patients with atherosclerosis who are undergoing cardiac catheterization are at risk for embolic events triggered by dislodgement of plaque fragments within the aortic lumen by the catheters themselves. These patients often have intense pain without peritoneal signs, because the peritoneum is not inflamed.

Diverticulitis, NSAID enteropathy, hemorrhoids, and colon cancer are all unlikely causes of these findings post-catheterization.

Note: This is different from Ischemic colitis

Question:

A 65 year old woman had an attack of sigmoid diverticulitis diagnosed by CT scan and successfully treated by IV antibiotics 6 weeks ago. She is currently asymptomatic. Your next step is

- A. Barium enema
- B. Water-soluble contrast enema
- C. Repeat CT scan of abdomen and pelvis
- D. Colonoscopy
- E. Reassurance and advice to seek treatment early if she gets another attack of diverticulitis
- F. Sigmoid resection to prevent further attacks

Answer: D

After successful treatment of presumed diverticulitis, the patient should have a colonoscopic examination to exclude cancer, which may mimic diverticulitis. A barium enema or a water-soluble contrast enema is less useful than colonoscopy because the presence of numerous diverticula may obscure a small neoplasm. A repeat CT scan would not be adequate to rule out an intraluminal neoplasm. A single attack of uncomplicated diverticulitis does not warrant sigmoid resection (except in immunocompromised individuals and in certain uncommon situations). However, a single attack of complicated diverticulitis warrants sigmoid resection, either emergently or electively.

Question:

72 year old woman presents to the ER with left lower quadrant abdominal pain and tenderness, fever and leukocytosis. A CT scan suggests a diagnosis of diverticulitis with a pelvic abscess 5 cm in diameter. The most appropriate treatment at this time is

- A. A trial of broad spectrum IV antibiotics
- B. Percutaneous drainage of the pelvic abscess
- C. Laparotomy with drainage of the abscess
- D. Laparotomy, drainage of the abscess, sigmoid resection and colorectal anastomosis
- E. Laparotomy, drainage of the abscess, sigmoid resection and end colostomy (Hartmann's procedure)

Answer: B

The appropriate treatment is percutaneous drainage of the abscess, usually with ultrasound or CT guidance. IV antibiotics should be given in conjunction with draining of the abscess, but antibiotics alone is not adequate. Laparotomy is seldom required to adequately drain a pelvic abscess. Sigmoid resection can be safely accomplished after the acute infectious process has resolved. If percutaneous drainage is not feasible or not adequate, the patient requires an emergent laparotomy, drainage of the abscess, sigmoid resection with end colostomy. Primary anastomosis is not done during an acute attack as anastomosis may not heal.

Question:

Which of the following may be appropriate initial therapy for a 4 cm cancer of the anal canal ?

- A. Local excision
- B. Abdominoperineal resection
- C. Combined chemotherapy and radiotherapy
- D. Laser therapy
- E. Cryotherapy

Answer: C



Question:

A 58 year old man is referred for evaluation because he fainted at his job. He has no other significant history. His physical exam is unremarkable except that he is pale and is guaiac positive.

1) What are the possibilities ?

2) How do you proceed ?

Possible diagnosis:

UGI bleed, Ca of right colon, Ca of left colon

(there are lot of reasons for a person to faint such as TIA, CAD, arrhythmia, hypoglycemia, etc ... and the work up is extensive)

Treatment plan:

Colonoscopy first, then EGD

He needs both UGI & LGI endoscopy as he may have two problems simultaneously

Question:

A 63 year old man complaints of bloody bowel movements. The small amount of blood coats the stool and has been present on & off for 2 months. Lately, he has been constipated and stool have become of narrow caliber.

1. What is the likely diagnosis ?
2. What will aid in establishing the diagnosis ?

1. Ca of left colon

2. Colonoscopy & biopsy

Note:

If this patient has tenesmus, then think of
RECTAL CANCER

Question:

An 80 year old lady develops severe abdominal distention associated with colicky pain and nausea. She has not had passed stool or gas for the past 24 hours. Abdomen is tympanitic with hyperactive bowel sounds. AxR shows a very large gas shadow tapering towards the pelvis and distended loops of small & large bowel.

1. What is your diagnosis ?
2. What is the treatment plan ?

Diagnosis: Sigmoid volvulus

Treatment plan: Proctosigmoidoscopy to reduce the volvulus

If reduction was successful,

- place a rectal tube to prevent further twisting.
- obtain medical clearance and plan sigmoid resection after bowel prep in the next few days

If reduction was unsuccessful,

- patient needs emergent laparotomy & sigmoid resection

Note:

If this patient presented with symptoms & signs of ischemic colon (peritonitis, elevated WBC, acidosis, or if proctoscopy shows ischemic colon), patient needs emergent laparotomy.

Question:

A 75 year old man had three large bowel movements that he describes as made up entirely of dark red blood. The last one was 2 days ago. He is pale, but has normal vital signs. An NGT aspirate is clear green fluid without blood.

What is your treatment plan ?

Treatment plan:

The clear aspirate is meaningless as he is not bleeding right now. So it could have been an UGI or LGI bleed. If this was a younger patient, the source is likely (but never sure) to be from the UGI tract. In an older patient, the bleeding can be either from an UGI or LGI source.

Bleeding scan or angiography is not useful as there is no active bleeding now. He needs both upper & lower endoscopies.

Question:

A 60 year old man known to have hemorrhoids reports bright red blood in the toilet paper after defecation.

What is the likely diagnosis ?

What is next important step in the management?

Likely diagnosis:

Internal hemorrhoids

Next step in the management:

Rectal exam and rigid proctosigmoidoscopy.

This has to be done to r/o cancer of rectum

Irrespective of the findings of proctoscopy, this patient needs a full colonoscopy

Q: Match the clinical comment on the left with the disease process on the right

- | | |
|--------------------------------------|-----------------------|
| A. Anal involvement in 50% | a. Crohn's disease |
| B. Rectal involvement in nearly all | b. Ulcerative colitis |
| C. Small bowel involvement is common | c. Both |
| D. Chronic diarrhea, cramps, fever | d. Neither |
| E. Curative surgery available | |
| F. Toxic megacolon | |

Answer:

A-a B-c C-a D-c E-b F-c



Question:

A 28-year-old woman presents with a 3-month history of chronic right lower abdominal pain. The pain occurs daily without clear precipitants and is associated with bloating that spontaneously resolves. The patient occasionally has fevers that she cannot explain, but they typically resolve without treatment. She has 3 to 4 loose stools per day that contain mucus but not blood. She has lost 10 lb in the last 3 months despite a good oral intake. She also reports occasional eye pain with light sensitivity. On examination, her abdomen is focally tender in the right lower quadrant without peritoneal signs or palpable masses; the remaining examination is unremarkable. What is the most likely underlying diagnosis in this patient?

- A. Chronic appendicitis
- B. Crohn's disease
- C. IBS
- D. Systemic lupus erythematosus (SLE)

Answer: B

Crohn's disease.

This patient's history and physical examination are most consistent with Crohn's disease. Crohn's disease is an inflammatory condition that can occur anywhere in the gastrointestinal tract but most commonly affects the small bowel. This patient's RLQ abdominal pains are suggestive of involvement of the terminal ileum, an area frequently affected. Involved intestine can become strictured (causing bloating secondary to partial obstruction), develop abscesses, or form fistulas (e.g., enterocutaneous, enterovaginal, enteroenteric), which are often associated with fevers as well. Her ocular symptoms likely represent iritis, which is considered an extraintestinal manifestation of Crohn's disease.

Chronic appendicitis is unlikely to be associated with iritis but could cause many of this patient's symptoms. SLE could cause mesenteric vasculitis, which could mimic Crohn's disease but would likely present with more diffuse abdominal pain as opposed to focal right lower quadrant pain. IBS is unlikely given her alarm symptoms (i.e., fever, weight loss).

Question:

42 year old man has suffered from chronic ulcerative colitis for 15 years. He now weighs 130 lbs and has had multiple admissions for exacerbations of the disease, requiring high dose steroids. He is now on a low dose of steroids, sulfasalazine and immuran. He is admitted with a temperature of 104, abdominal pain and distention. He appears ill, his abdomen is markedly tender & his WBC count is 18,000.

1. What is your diagnosis ?
2. What is your next step ?
3. What other investigation do you want to do now ?
4. What is your treatment plan ?

Diagnosis is toxic megacolon.

He needs to be resuscitated. Admit to ICU. Do all labs and cultures. Patient can go into shock.

Abdominal X-ray needs to be done

- look for free air
- pneumatosis intestinalis
- diameter of the transverse colon

Treatment plan :

- Start on high dose steroids.
- If x-ray shows free air or pneumatosis, he requires immediate surgery
- Needs frequent clinical evaluation.
- Will require AxR every day to monitor the diameter of transverse colon.
- If condition worsens or if no improvement is noted in 24-48 hours, needs subtotal colectomy with end ileostomy emergently.
- Antibiotics may not help with the colitis, but may reduce consequences of infections due to the disease process.

Question:

40 year old man with Crohn's disease has had two prior bowel resections, including an ileocecectomy, for complications related to Crohn's disease. He has about 150 cm of small bowel remaining and currently admitted for a high-grade bowel obstruction that has not responded to conservative measures. At laparotomy, three strictures are noted over a length of 50 cm. The management should be

- A. Three separate bowel resections with primary anastomosis
- B. Resection of the 50 cm of small bowel with reanastomosis
- C. Insertion of a long intestinal tube extending past the most distal stricture
- D. Three stricturoplasties
- E. A bypass of the strictured segment by a side-to-side jejunocolic anastomosis

Answer: D

The guiding principle in the surgical management of Crohn's disease is to resect a portion of bowel specifically involved in the complicated process. Repeated wide resections result in no greater remission of symptoms or cure and can lead to devastating short bowel syndrome. Hence, resection of the 50 cm of small bowel would not be prudent given the prior resections. Bypass is infrequently used. Insertion of long intestinal tube would be a short term solution, but would not alleviate the problem. The best option in this patient with previous bowel resections would be to perform stricturoplasties that effectively widen the lumen but avoid resection.