

THE ESSENTIAL COMPANION TO CADAVER DISSECTION

A REGIONAL DISSECTION GUIDE FOR MEDICAL HUMAN GROSS ANATOMY

**Structure of the Human Body
Stritch School of Medicine
2009**

**Frederick H. Wezeman, Ph.D.
Loyola University Chicago Stritch School of Medicine
Loyola University Medical Center
Maywood, Illinois**

© Copyright 2008 Frederick H. Wezeman

This dissection guide was designed as an aid to human cadaver dissection by first year medical students. The four fundamental tools of learning gross human anatomy (the cadaver, a dissection guide, a textbook, and an atlas) are amplified in their relevance by the use of additional resources now widely available. These include web-sourced radiographic, MRI, and CT images, as well as numerous software programs. In addition, students are advised to use simulation models, plastinated specimens, and prosections to augment their learning.

The dissection of a human body is a privilege given to few. For hundreds of years it has been a pivotal learning experience during the education of a physician. Designed to be part of the first year of all medical curricula, the knowledge gained is foundational to subsequent medical education. No physician has ever entered the field of medicine without adequate training in the anatomical sciences. Recent changes in undergraduate medical curricula are now integrating gross anatomy in the later years of medical school training, and at the graduate medical education level many programs require residents to complete review courses in gross anatomy. The necessity of retained knowledge of gross anatomy is therefore consistently emphasized.

I hope that you, as a student, learn as much of this wonderful subject as possible throughout the years of your medical education and continue to increase your knowledge of human structure throughout your career. You and your patients will then be well-served.

Frederick H. Wezeman, Ph.D.
Professor, Orthopaedic Surgery and Rehabilitation
Professor, Cell Biology, Neurobiology and Anatomy
Associate Dean, The Graduate School
Loyola University Stritch School of Medicine
Maywood, Illinois
2009

Introduction

As valuable as detailed dissection manuals may be, too frequently they are adorned with excessive text, bullet points, figures, highlights and clinical correlations that make them more like a textbook and, as such, arguably less utilitarian during dissection.

This companion is an efficient guide to dissection with a specific focus on giving straightforward “next step” instructions. By virtue of its intended purpose, it leaves the responsibility of gathering primary visual information about structure to the student’s parallel use of an atlas or other resources.

Adopt a consistent approach to the dissection and work together as a team. Instruct each other in the small group learning environment by quizzing each other and supporting each other’s learning. Participate equally in dissection. Be professional toward the faculty, each other, and the cadaver.

Follow the faculty member’s instructions regarding the use of sharp and blunt dissection techniques. Use proper dissection instruments at all times. A faculty member will demonstrate proper techniques and you should try to mimic those techniques. As you gain experience your dissection time will reduce; initially, your progress will be slow.

The named structures in this manual can be considered collectively as a “find list”, although it is cautioned that it is incomplete. Other structures that you will be held responsible for are identified in the required text and recommended atlases.

Note: The dates and goals as shown are intended as a guide to “pace” the dissection for the duration of the course, AY 2009-10. In order to stay on schedule during the course students should, at a minimum, complete the dissection of a region on or about the date given in the companion. Students should be prepared to spend additional dissection time outside of the formally scheduled lab times.

Superficial Back

October 12

Goals:

- 1. Orient yourself to the cadaver in the prone position, identifying bony landmarks on the back.**
- 2. Adopt proper dissection technique for removing skin.**
- 3. Dissect the superficial musculature of the back.**

Place the cadaver in the prone position. It may be necessary to untie (cut) any rope used to tie the hands together so that the arms can be placed at the side of the body.

Palpate (feel with your finger tips) the surface anatomy of underlying structures on the back. Identify the spine of the 7th cervical vertebra (C7). Palpate and count the spinous processes of the thoracic vertebrae down to the first lumbar vertebra if possible. Palpate the scapula's borders and the spine of the scapula. Some cadavers are obese or the fixation makes the skin very firm and palpation cannot be done accurately. In that case, palpate a friend's back and identify the spinous process of C7. Palpate the posterior crest of the ilium.

Identify the parts of the axial and appendicular skeleton. Study the structure of the thoracic vertebrae using bone box specimens or a complete hanging skeleton. Locate and name the parts of an individual vertebra; using an intact spine on a hanging skeleton identify the intervertebral foramina where the spinal nerves exit from the spinal column.

Remove **ONLY** the skin from the back from the base of the skull to the lumbar region. Reflect large skin flaps; these will be useful later on to maintain the moisture in the back tissues throughout the course. As the skin is removed note that small vessels and nerves penetrate deeper structures to supply the skin and subcutaneous tissues. Look closely at a small nerve and a small vessel to note the difference in appearance and feel. The small vessels and nerves on the back can be cut during skin removal.

The musculature of the back is in two layers. The first layer encountered is comprised of the trapezius and latissimus dorsi muscles. As you begin to learn the musculature of the body you must memorize the following for each muscle: a) name and its correct spelling, b) origin, c) insertion, d) action of the muscle, e) innervation (nerve supply), and f) blood supply. Create the habit of memorizing these in lab; it will greatly reduce the time spent looking these details up later in the day or in the evening when you are studying. *Use lab time to both dissect and memorize.*

Find the borders of each muscle using an atlas and then on the cadaver. Clean a border to orient yourself to the muscle. Blunt dissect the lower surface of the muscle at each border and lift it slightly away from deeper structures to reveal its extent. The flat sheet-like trapezius is the shape of a trapezoid; the latissimus tapers to a large strong tendon that inserts on the humerus. Do not

cut the latissimus dorsi. Identify its nerve, the thoracodorsal nerve, and its blood supply, the thoracodorsal artery on its inferior surface.

Make a cut through the origin of the trapezius parallel and one inch lateral to the spinous processes. Reflect the muscle laterally to reveal the second layer of muscles beneath it. Identify the nerve to the trapezius (cranial nerve 11, CN11, the spinal accessory nerve) and its blood supply.

4. Dissect the deep layer of muscles, nerves and vessels of the back.

The second (deeper) layer of back muscles is comprised of the rhomboid major and minor muscles, and the levator scapula muscle. Quiz each other on the 6 things you need to know about each of these muscles. Dissect the scapular attachment only of the levator scapula; its superior portion is in the neck region. Reflect the rhomboids by a cut ½ inch lateral to their origins. Carefully lift them from underlying structures. Locate the dorsal scapular nerve and artery and the accompanying transverse cervical artery as they make their way into the muscles from above.

Note: Because many of the cadavers are old people, their muscles will be thin, having perhaps not been used in many years. Age is a factor in declining body mass, along with disease, lack of exercise, immobilization, and poor nutrition. On the other hand, many cadavers will be large, obese, and well-muscled. Many combinations of these factors will be noted. Please observe other cadavers during the course; you will be tested in lab exams on all of them and you should be able to recognize structures regardless of the attributes of the cadaver.

Deep Muscles of the Back and Suboccipital Triangle

Cut the latissimus dorsi muscle about 3 inches from the midline and reflect the proximal segment toward the vertebral spines. Identify the posterior superior and posterior inferior serratus muscles. Note the attachments of the posterior layer of the thoracolumbar fascia, then incise it longitudinally from the level of the second rib to the ilium. Reflect this fascia and observe the underlying erector spinae muscles beneath. Identify the lumbar, thoracic, and cervical portions of the iliocostalis and longissimus muscles. Determine the position and attachments of the spinalis muscle.

Displace the longissimus muscles laterally and remove the spinalis muscles along the vertebral spines to expose the transversospinal group of muscles, the semispinalis, multifidus, and rotatores. These will not be individually dissected. Collectively these muscles stabilize the vertebral column and control small movements between vertebrae.

Review the unique osteology of the atlas and axis, the first 2 cervical vertebrae. On skeletal material observe the morphology of the remaining cervical vertebrae including the body, spinous process, lamina, pedicle, transverse process, dens (odontoid process), foramina, and articulating facets. Place a wood block under the chest and flex the head.

October 14 (As of this date you should have progressed this far in the dissection)

The suboccipital triangle at the base of the skull is exposed by reflecting the cervical portion of the trapezius from its origin by a vertical incision 1 inch lateral to the cervical spinous processes. Identify the underlying splenius muscle. Reflect the splenius muscle from the nuchal ligament at the base of the skull and from the cervical spinous processes. Deep to the splenius lies the semispinalis capitus muscle and through it will pass the greater occipital nerve as it courses superficially to supply the scalp accompanied by the occipital artery. Dissect the nerve from the muscle and then divide the semispinalis capitus by a horizontal incision. Reflect the cut ends of the muscle and expose the underlying suboccipital triangle musculature, nerves, and vessels.

Dissection of this region can be difficult from this point on. Deep to the semispinalis capitus trace the suboccipital nerve to its deeper level of emergence from the inferior border of the obliquus capitus inferior muscle. This muscle-nerve relationship is a landmark for the remaining structures to be found in this area. Identify the spinous process of the axis (C2) and the posterior tubercle and transverse process of the atlas (C1). The obliquus capitus superior, rectus capitus posterior major, and obliquus capitus inferior muscles define a triangular space through which the suboccipital nerve will pass; clean and identify this nerve. The greater occipital nerve (C2) emerges from beneath the inferior border of the obliquus capitus inferior muscle; use this relationship as a landmark in this region.

Identify the rectus capitus posterior minor muscle medial to the rectus capitus posterior major muscle. Dissect more deeply in the triangle to the level of the posterior arch of the atlas. Clean and identify the vertebral artery lying in a groove on the superior surface of the posterior arch. This artery is part of the vascular supply to the brain. Numerous veins will be encountered in this region and can be removed.

Spine and Spinal Cord

Goals:

- 1. Perform a laminectomy from C7-L4.**
- 2. Dissect the spinal cord.**

Identify the various types of vertebrae and note their structural differences. Identify articulating surfaces and joints, processes and the vertebral body. Name the anterior and posterior elements of an individual vertebra and observe how the vertebrae move during flexion, extension, and rotation of the spine.

Be able to number the spinous processes of the lumbar vertebrae in anticipation of being asked where you might insert a needle to obtain cerebrospinal fluid (CSF) by a lumbar puncture. Try to number these on a friend's back by palpating them individually.

Clean away the erector spinae group including the iliocostalis, longissimus, and spinalis, and the transverse group including the multifidi, rotatores, interspinalis, and intertransversarii to fully expose the spines and laminae of the thoracic and lumbar vertebrae from C7 to L4. Using an electric cast saw (Stryker), cut through the laminae at each level, on each side. Remove the spinous processes and laminae without tearing underlying tissues; this procedure will open the vertebral canal and expose the spinal cord and meninges. Identify the ligamentum flava.

Identify the dura mater, the outermost covering of the spinal cord. Cut it longitudinally from C7-L4 using a scissors. Identify the dorsal and ventral spinal roots and the continuation of the dura mater on them as they emerge from the vertebral canal (dural sleeve). Dissect the underlying arachnoid and note the subarachnoid space that contains CSF. Probe the surface of the cord and the adherent pia mater. From L1-L2 the pia extends inferiorly as the filum terminale. Note the delicate denticulate ligaments of pia mater as they extend laterally to anchor the cord and resist torsion of the cord.

Lift the dura beneath (anterior to) the spinal cord and observe the posterior longitudinal ligament of the vertebrae. The anterior longitudinal ligament cannot be observed at this time.

Note where the spinal cord ends (L2) as the conus medullaris, and the anatomy of the cauda equina beneath this level, relating this to the reason for a lumbar puncture to obtain CSF below the level of L2. Also note the vascularity of the meninges and the cord if it is apparent in your cadaver. These arise from the vertebral arteries and the segmental spinal branches of the deep cervical, intercostal, lumbar, and sacral arteries.

Using a chisel, remove bone from the area of an intervertebral foramen to expose a dorsal ganglion associated with the dorsal root. Review the formation of a spinal nerve and the distribution of the primary rami.

Deltoid and Scapular Region

October 15 (As of this date you should have progressed this far in the dissection)

Goals:

- 1. Dissect the muscles, nerves and vessels of the shoulder region including the scapula.**
- 2. Observe the articulation between the head of the humerus and the glenoid cavity of the scapula.**

Review the osteology of the shoulder region, including the proximal humerus, scapula, and clavicle. Motions at the shoulder joint reflect the actions of numerous muscles and the shallowness of the glenoid that permits an extreme range of motion compared to other movable joints.

Identify the spine of the scapula, acromium, coracoid process, glenoid, supraglenoid tubercle, surfaces, fossae, angles, suprascapular notch, and borders of this bone. Observe how the scapula articulates with the clavicle and the sternum; observe how the humerus articulates with the scapula.

Remove the skin from the arm to the level of the elbow being very careful not to remove important superficial veins or nerves that will be studied later.

Clean the posterior margin of the deltoid to its point of insertion on the humerus. Reflect the deltoid by detaching it from its origin on the spine of the scapula and the acromium and lifting it laterally. As you reflect the deltoid, try to observe the subdeltoid bursa on the deep surface overlying the acromium. This is the first bursa you will have seen in dissection. This bursa may be continuous with the subacromial bursa that lies between the acromium and the tendons of muscles inserting in the rotator cuff.

As the deltoid is reflected note its innervation by the axillary nerve and its vascular supply by the anterior and posterior humeral circumflex arteries.

Remove the fascia from the dorsal surface of the scapula to expose the supraspinous and infraspinous muscles. At the lower lateral region of the scapula identify the teres major and teres minor muscles. Clean the margins of these four muscles as far as possible toward their respective tendons which are converging on the shoulder joint and the humerus.

Cut transversely through the supraspinatus muscle near the origin of the levator scapula muscle and lift the muscle from the supraspinatus fossa. Continue to reflect it carefully to the point of the scapular notch. The notch is bridged by the suprascapular ligament that creates a small tunnel (the notch). Identify the suprascapular nerve that traverses the notch beneath the ligament and the suprascapular artery that travels over the ligament. These structures then pass through the great scapular notch and enter the infraspinatus muscle.

With the scapula abducted, note the undersurface which has two muscular layers. By placing your hand between the ribs and the scapula you will be in contact with the serratus anterior muscle that originates on the upper 9 ribs and inserts on the medial (vertebral) border of the scapula. This muscle is innervated by the long thoracic nerve.

Clean and separate the heads of the triceps muscle on the dorsum of the arm. Clean and separate the tendon of the teres major as it passes to its point of insertion on the humerus. Identify the space bordered by the humerus laterally, the teres minor and major above and below, and the long head of the triceps medially (quadrangular space containing the axillary nerve and the posterior circumflex humeral artery). Also identify the more medial triangular space bounded by the teres major and minor and the long head of the triceps and its contents (circumflex scapular artery).

By cleaning these spaces and the adjacent muscles you will begin to see the vascular anastomoses around this region of the scapula. Review the entire vascularity of this region. It reflects the anastomotic connections of various branches of the subclavian and axillary arteries.

Locate the coracoacromial ligament and the conoid and trapezoid portions of the coracoclavicular ligament. On one side only, open the capsule of the shoulder joint by a longitudinal incision on the posterior surface and observe the humeral head and glenoid surface.

Identify the glenoid labrum. Identify the tendons of the rotator cuff muscles, the subscapularis, supraspinatus, infraspinatus, and teres minor muscles (“SSIT” muscles) that stabilize the head of the humerus in the glenoid fossa and rotate the humerus. Note the subacromial bursa overlying the rotator cuff.

Note the appearance of the articular cartilage on the head of the humerus and the glenoid. Review the direction(s) of travel of the humeral head during disarticulation.

Breast and Pectoral Region

Goal:

1. Dissect the breast and the pectoral region.

Place the cadaver in the supine position. Remove the skin from the jugular notch to the xiphoid process of the sternum laterally to the midaxillary line, preserving skin around the nipple. Do not skin below the costal margin.

Observe the structure of the male and female breast. Incise the female nipple and observe the termination of the lactiferous ducts from the gland. Dissect beneath the breast to note its position superficial to the pectoral musculature. Note the amount of fat and connective tissue interspersed with glandular tissue. Review the lymphatic drainage pathways from the breast and observe lymph nodes during the dissection of the region and in all future dissections.

Reflect the superficial fascia from the pectoral and axillary regions leaving cutaneous nerves intact. Clean the margins of the pectoralis major muscle and separate its clavicular portion from the sternal portion. Expose the cephalic vein in the groove between the deltoid and pectoralis major muscle. Detach the sternal portion from its origin and reflect it, retaining the lateral and medial pectoral nerves and the branches of the internal thoracic and thoracoacromial arteries entering from beneath the muscle.

Observe that the clavipectoral fascia encloses the pectoralis minor muscle. Cut this fascia along its attachment to the clavicle and turn back the cut edge to expose the subclavius muscle. Note that a deep layer of this fascia passes deep to the muscle and attaches to the clavicle.

Isolate but do not cut the pectoralis minor muscle. Note its innervation from the medial and lateral pectoral nerves and the branches of the thoracoacromial artery to this muscle.

Identify the serratus anterior's origin on the lateral thoracic wall and note once again its insertion relative to the location of the subscapularis muscle.

Superficial Posterior Triangle

October 20 (As of this date you should have progressed this far in the dissection)

Goals:

- 1. Dissect the posterior triangle of the neck including the cutaneous distribution of the cervical plexus.**
- 2. Dissect the roots and trunks of the brachial plexus.**

Remove the skin from the neck to the lower border of the mandible being careful not to remove the external jugular vein that lies superficial to the sternocleidomastoid muscle. Do not cut this muscle at this time.

Identify the sternocleidomastoid muscle and its posterior border, the upper border of the clavicle, and the anterior margin of the trapezius muscle. Carefully remove the skin from this posterior triangular area of the neck being very cautious at the posterior midpoint of the sternocleidomastoid muscle where cutaneous nerves of the cervical plexus become superficial. Do not dissect anterior to the sternocleidomastoid muscle at this time.

Carefully dissect the dense fascia of the posterior triangle. The ventral rami of cervical nerves 2-4 combine to form a portion of the cervical plexus giving rise to the lesser occipital, great auricular, transverse cervical, and supraclavicular nerves which penetrate the fascia and are cutaneous in distribution. This is the first nerve plexus you will dissect; later you will dissect plexuses of ventral rami in the lumbar and sacral regions.

Lower cervical (4-8, plus thoracic nerve 1) ventral rami (roots) communicate to form the brachial plexus, the nerves of which are motor and sensory to the upper limb. The roots for this portion of the cervical plexus emerge from between the anterior and middle scalene muscles in the floor of the posterior triangle. Clean and identify the superior, middle and inferior trunks of the brachial plexus and their contributions from the roots.

At this time begin to appreciate the difference between medium-sized arteries and their companion veins. On the anterior surface of the anterior scalene muscle identify the phrenic nerve. Using the electric saw, remove the middle third of the clavicle and identify the underlying subclavian artery and subclavian vein as they cross over the first rib.

Observe the inferior belly of the omohyoid muscle crossing from posterior to anterior above the clavicle and deep to the trapezius and sternocleidomastoid muscles. Dissect above the inferior belly of the omohyoid to expose the spinal accessory nerve (CNXI) lying on the levator scapula muscle, and the transverse cervical and suprascapular arteries and veins. These two arteries arise from the thyrocervical trunk of the subclavian artery medial and deep to the anterior scalene muscle. Identify the dorsal scapular nerve emerging from behind the middle scalene muscle.

Axilla and Arm

October 22 (As of this date you should have progressed this far in the dissection)

Goals:

- 1. Dissect the muscles of the arm (brachium).**
- 2. Dissect the brachial plexus and branches of the axillary and brachial artery.**

Remove skin from the arm to the elbow. With the arm abducted clean the axilla carefully without severing superficial nerves or vessels. Note the presence of lymph nodes in the axilla and appreciate their significance in this region. Recognized groups are the lateral, pectoral, subscapular, central, and apical. Metastatic carcinoma from the breast travels to these groups.

At this point in the dissection you will be told that only large veins and their major tributaries are named. All other small veins can be removed during cleaning an area. Preserve the cephalic, basilic, and median cubital veins of the arm. Into which vein in the arm is a venapuncture made to remove a blood sample?

Expose the axillary vein. Identify the axillary sheath beneath it which contains the axillary artery. Carefully isolate the branches of the axillary artery from the level of the clavicle to the elbow. Locate the three divisions of the axillary artery based on the insertion of the pectoralis minor muscle. Identify the superior thoracic, thoracoacromial, lateral thoracic, subscapular, anterior humeral circumflex, posterior circumflex, and deep brachial arteries. Assign each to a division of the axillary artery. Dissect the branches of the subscapular artery, the circumflex scapular and thoracodorsal. Continue dissection down the brachial artery down to the level of the elbow. Along its course clean and identify the superior and inferior ulnar collateral arteries. Follow the deep brachial artery from its origin as far distally as possible where it will anastomose with the radial recurrent branch of the radial artery.

The connective tissue sheath around the axillary artery and vein and the brachial artery and vein may be dense and difficult to dissect in some cadavers. Use a scissors to separate the vessels from the sheaths. It is not necessary to retain the deep veins of the arm if the dissection due to the presence of dense connective tissue sheaths is difficult; focus your attention on the arterial vascular distribution.

Clean and identify the lateral, medial and posterior cords of the brachial plexus after you have cleaned and identified the roots, trunks and division of the plexus. At the level of the trunks, dissect the suprascapular nerve and nerve to the subclavius muscle from the superior trunk. Higher up, and emerging from the level of the roots, dissect the long thoracic nerve that will innervate the serratus anterior muscle.

The nomenclature for the cords is based on their relationship to the axillary artery. You will encounter numerous small diameter long nerves in the axilla. Take care not to cut them. Identify the following major landmark nerves that will facilitate learning the brachial plexus in situ: the median nerve, musculocutaneous nerve, and ulnar nerve. First identify the musculocutaneous nerve; it penetrates the landmark coracobrachialis muscle. Pick up this nerve and note that at its

superior limit is a connection to the median nerve. Pick up this nerve also and note that at its superior limit is a connection to the ulnar nerve. By holding these three nerves identify the “M” (“W”) formed by the contributions to the formation of these nerves from the lateral and medial cords. Identify the medial antebrachial cutaneous nerve running parallel to the ulnar nerve. Also identify the small lateral and medial pectoral nerves from the lateral and medial cords; these will emerge from the plexus at the level of the insertion of the pectoralis minor muscle.

Displace the lateral and medial cords and observe the posterior cord and its branches, the upper, middle (thoracodorsal) and lower subscapular nerves and the axillary nerve. Distally the radial nerve (posterior cord) leaves the axilla at the lower border of the latissimus dorsi to enter the posterior compartment of the arm.

Separate the flexor muscles of the arm using blunt dissection. Isolate the brachialis muscle. Observe the two heads of the biceps brachii muscle and the origin of the long head from the supraglenoid tubercle of the scapula. Follow the biceps brachii to its tendon insertion on the radius. Dissect and then cut the bicipital aponeurosis taking care not to cut the biceps tendon..

On the posterior aspect of the arm, separate the long, lateral, and medial heads of the triceps brachii muscle. Follow the course of the radial nerve by cutting the lateral head of the triceps muscle. Note the relationship between the radial groove on the humerus and the medial and lateral heads of the triceps. Observe the position of the radial nerve and the branches of the profunda brachii artery. Determine where the ulnar nerve enters the posterior compartment and its relationship to the medial condyle of the humerus.

Forearm

Goals:

- 1. Dissect the forearm (antebrachium) muscles and tendons.**
- 2. Dissect the elbow joint.**

Identify the olecranon of the ulna and the lateral and medial epicondyles of the humerus as landmarks. Observe the relationship of the radius and the movements of it as the hand is pronated and supinated. Define the structures constituting the elbow joint.

Identify the morphological features of the radius and ulna. Identify the head, tuberosity, and styloid process of the radius. Identify the head, styloid process and coronoid process of the ulna.

Remove skin and superficial fascia of the forearm from the elbow to the wrist taking care to preserve cutaneous nerves. Incise the antebrachial fascia on the anterior surface from the cubital fossa down to the wrist and reflect it. Establish the boundaries of the cubital fossa. Clean the brachioradialis muscle and displace it laterally to expose the radial artery and nerve. Dissect the superficial and deep branches of the radial nerve. The deep radial nerve will penetrate the supinator muscle to enter the posterior compartment; follow the superficial radial nerve to the level of the wrist. Dissect medial to the deep radial nerve and locate the radial recurrent artery, radial artery, ulnar artery, and anterior and posterior ulnar recurrent arteries. Variations may exist for the level of bifurcation of the brachial artery into the radial and ulnar arteries, and the

anastomoses around the elbow may be difficult to dissect. Follow the radial and ulnar arteries to the level of the wrist.

Be aware that vascular pattern variations are not necessarily anomalies, and many may be encountered throughout the body. Observe other cadavers so that you are familiar with vascular pattern variations.

On the ventral (anterior, flexor) surface of the forearm note that the muscles arise from a common origin at the medial epicondyle of the humerus and the upper anterior surfaces of the radius and ulna. Starting on the lateral side, clean and separate the brachioradialis muscle down to its tendon. This muscle however arises from the lateral surface of the humerus. Now dissect in the medial direction toward the group of muscles arising from the medial epicondyle and separate the pronator teres, flexor carpi radialis, palmaris longus, and flexor carpi ulnaris muscles and their tendons. Mobilize these muscles and spread them to reveal the muscles lying below: the supinator, flexor digitorum superficialis, flexor digitorum profundus, flexor pollicis longus and pronator quadratus.

Do not cut the tendons in the forearm.

Note that the interosseous membrane lies between the radius and ulna deep to the muscles of the forearm. Probe to its proximal (uppermost) limit. Identify the bifurcation of the brachial artery and dissect the ulnar artery to the common interosseous artery at the upper border of the interosseous membrane. Dissect the branches of the common interosseous artery, the anterior and posterior interosseous arteries.

Follow the median nerve from the arm past the cubital fossa and dissect its anterior interosseous branch. Continue dissection of the median nerve to the level of the wrist. Dissect medial to the median nerve and identify the ulnar nerve in the forearm and follow it to the level of the wrist.

On the dorsal (posterior, extensor) surface of the forearm note that the muscles also arise mainly from a common origin, the lateral epicondyle of the humerus. Clean and identify the extensor carpi ulnaris, extensor digitorum, extensor digiti minimi, extensor carpi radialis brevis and longus muscles and their tendons, and the anconeus muscle. A deeper group will be revealed by spreading these muscles apart once the tendons are mobilized below the deep fascia and retinaculae. Clean and identify the portion of the supinator that lies on the dorsal side of the forearm, and the abductor pollicis longus, extensor pollicis brevis, extensor pollicis longus, and extensor indicis muscles.

Skin the dorsal surface of the hand and fingers and follow the tendons of the extensor muscles to their points of insertion. Lying on the surface of the deep group of muscles locate and clean the posterior interosseous nerve and artery. Note the relationship of the extensor retinaculum at the wrist and the associated synovial sheathes of the long tendons passing into the hand.

On one side, remove muscle from around the elbow joint capsule. Expose the bands of the ulnar collateral ligament, radial collateral ligament, and the annular ligament.

Hand

October 27 (As of this date you should have progressed this far in the dissection)

Goals:

- 1. Identify the carpal bones.**
- 2. Dissect the carpal tunnel and its contents.**
- 3. Dissect the hand muscles, nerves, and vessels.**

On skeletal material identify the carpal bones and their anatomical positioning. Observe their articulations with the radius and ulna as well as with the metacarpal bones. Identify the carpal-metacarpal, metacarpal-phalangeal, proximal and distal interphalangeal joints. Specifically identify the extent and attachments of the flexor retinaculum on the ventral surface of the hand. This participates in forming the carpal tunnel, through which passes the tendons of the flexor digitorum superficialis and flexor digitorum profundus and flexor pollicis longus muscles as well as the median nerve.

Start hand dissection on the dorsal surface after removal of the skin. Dissect the long extensor tendons to each digit and free them from their extensor expansions en route to the distal aspects of each finger. Move them aside and dissect and identify the four dorsal interossei muscles between the metacarpals by cleaning their margins. Follow the radial and ulnar contributions to the dorsal carpal arch. All non-muscular structures on this dorsal surface lie very superficially. Clean the radial artery and follow it into the region of the first dorsal interosseous muscle after giving off its superficial branch.

Remove the skin and fascia of the hand. Make longitudinal incisions to the ends of each digit through the fibrous digital sheath using a scissors to release the tendons of the flexor digitorum superficialis and flexor digitorum profundus muscles.

Do not cut the tendons in the hand.

Cut the flexor retinaculum proximally to distally exposing the contents of the carpal tunnel. Dissect the median nerve in this compartment and identify the recurrent median branch of the median nerve entering the thenar eminence distal to the flexor retinaculum.

Follow the ulnar artery into the palm and clean the deep branch of the ulnar artery lying at the lateral aspect of the flexor retinaculum. Proximal to the flexor retinaculum locate and dissect the superficial branch of the radial artery and the continuation of the radial artery as it dives deep to the thenar muscles (and continues into formation of the deep palmar arch). Dissect the superficial palmar arch and its branches (common palmar digital), branches of the ulnar nerve, and additional branches of the median nerve.

Dissect the fascia overlying the thenar muscle group and identify the thenar muscles: flexor pollicis brevis, abductor pollicis brevis, and opponens pollicis. Clean the margins and tendinous components of each muscle. Deep and distal to the thenar muscles dissect the two heads of the adductor pollicis muscle, transverse and oblique.

Dissect the fascia overlying the hypothenar muscle group and identify the hypothenar muscles: flexor digiti minimi, abductor digiti minimi, and opponens digiti minimi. Clean the margins and tendinous components of each muscle.

Deep to the branches of the median nerve dissect the deep palmar arterial arch lying across the metacarpals distal to their bases. Clean the palmar metacarpal arteries that run distally and anastomose with the common palmar digital arteries from the superficial palmar arch. Dissect the princeps pollicis and radialis indicis arteries arising between the first and second metacarpals.

Identify the four lumbrical muscles arising from the tendons of the flexor digitorum profundus. Deep to these lie the three palmar interosseous muscles originating on metacarpals and inserting on proximal phalanges.

Thorax

October 29 (As of this date you should have progressed this far in the dissection)

Goals:

- 1. Dissect an intercostal space.**
- 2. Remove the chest wall to expose the thoracic and pericardial cavities.**

Examine a disarticulated rib and identify its parts and articular processes. Identify the parts of the sternum. On the skeleton differentiate true, false, and floating ribs. Locate the sternal angle and establish its costal and vertebral levels. Identify the superior and inferior thoracic apertures, and identify the costal arches and the infrasternal angle.

Study the intercostal musculature by dissecting an intercostal space. Identify the external and internal intercostal muscles. Expose the nerves and vessels in the intercostal space. Remove the muscles in the first five intercostal spaces just lateral to the sternum to expose the internal thoracic artery on each side. Continue the removal of the muscles between the mid-axillary line and the sides of the sternum. Using blunt dissection technique, free the entire length of the internal thoracic artery from its adherence to the fascia underlying the thoracic wall on each side.

Using blunt dissection technique push the parietal pleura downward away from the under-surface of the ribs and sternum without tearing the pleura.

Make a cut with the bone saw across the sternum at the level of the sternal angle and the sixth costo-sternal junction and cut ribs two through five in the mid-axillary line on each side. Remove the sternum and the rib portions in one piece leaving the internal thoracic vessels and pleura intact.

Pleura and Lungs

Goals:

- 1. Observe the lungs in situ.**
- 2. Remove the lungs and dissect the major structures at the hilum.**

On each side cut the parietal pleura longitudinally along the mid-clavicular line and transversely at the ends of this incision. Reflect the flaps and identify parietal and visceral pleura. Adhesions may be noticed; the lungs should lie free within the pleural cavity. Mobilize the lungs by moving your hands around each lung, probing the costodiaphragmatic recess laterally and inferiorly and the cupula extending above the first rib.

Note the attachment of the lung and the pulmonary ligament of the pleura which extends inferior to the root of the lung. Name the structures that pass into and out of the lung at the root (pulmonary vessels and primary bronchus). The hardness felt in palpating the root is due to the presence of clotted blood in these large vessels.

Observe at this time the position of the heart contained within the pericardium. Do not open the pericardium at this point in your dissection. Dissect the phrenic nerves lying on the lateral aspect of the pericardium.

After the lungs have been successfully freed from adhesions, retract the lung laterally and use a scissors or scalpel to transect the root of the lung. Remove both lungs. Identify the surfaces and fissures of the right and left lung noting the differences in lung size and the number of lobes. Observe the cut ends of the structures at the hilum and identify pulmonary arteries, pulmonary veins, and bronchi.

Using the large blunt probe, stroke the lung tissue away from the hilum and expose one to two inches of each structure noting the branching patterns and changes in the diameter of the pulmonary vessels and lobar bronchi as the technique is carried deeper into the lung tissue. Identify the epiarterial bronchus on the right lung. Note lymph nodes at the hilum of the lungs and appreciate their significance in this location.

Heart

October 30 (As of this date you should have progressed this far in the dissection)

Goal:

- 1. Open the pericardium and examine the heart in situ.**

Incise the pericardium with a longitudinal cut from the base of the great vessels to the level of the diaphragm. Cut laterally from this incision on each side at the base and at the level of the diaphragm; open the pericardium as if you are opening the pages of a book.

Observe the amount of fat associated with the pericardium and also its thickness. Observe the heart *in situ* and the amount of fat associated with its surface. Identify the parietal and visceral pericardium. The heart should lie free within the pericardium; break any adhesions between the visceral and parietal pericardium. Note the size of the heart and evidence of any surgical procedures (e.g. coronary bypass surgery) by noting the presence of staples, clips or sutures.

Some cadavers will have implanted pacemakers. Note the course taken by the leads (wire) from the subcutaneous implant to the heart chamber. The lead will traverse the superior vena cava and the right atrium and will terminate in the wall (myocardium) of the right ventricle.

Mobilize the heart by running your hand over its surfaces and lifting the organ. Probe the extent of the reflection of parietal pericardium at the base of the heart. Place three fingers beneath the heart and push them upward into the oblique pericardial sinus. Your fingers will stop at the pericardial reflection between the left and right pulmonary veins. Identify the great vessels entering and leaving the heart at the base. Pass a finger beneath the pulmonary trunk and the aorta from left to right emerging between the superior vena cava and the arch of the aorta. Your finger traverses the transverse pericardial sinus which is important in surgical procedures and ligation of these major vessels.

Before removing the heart observe its orientation, borders, apex, base, and rotation that brings the right side of the heart anterior.

Dissect the vagus nerve on both sides distal to the origins of the recurrent laryngeal nerves.

Goals:

- 1. Remove the heart and dissect the coronary vasculature.**
- 2. Open the heart chambers and dissect the interior of the heart.**

Cut through the ascending aorta and the pulmonary trunk one inch superior to the point of their exit from the heart. Cut the inferior vena cava close to the diaphragm, and cut the superior vena cava one inch above its junction with the right atrium. Lifting the heart, expose the right and left pulmonary veins and cut them. Remove the heart and remove clotted blood from the great vessels.

Grossly and on the organ surface differentiate between right and left atria and their auricular appendages, pulmonary trunk, aorta, superior and inferior vena cavae, right and left ventricles, coronary sulcus and interventricular sulci. Also identify the coronary sinus and the four pulmonary veins on the posterior surface.

First, perform a dissection of the anterior surface of the heart. At the origin of the ascending aorta dissect through the reflecting parietal pericardium and clean the origin of the left coronary artery. Dissect its division into the circumflex and anterior interventricular arteries. Along the initial course of the circumflex identify and clean the left marginal artery. Continue cleaning the anterior interventricular artery as far toward the apex of the heart as possible. Identify the great cardiac vein.

Isolate the right coronary artery arising from the aorta opposite the origin of the left coronary artery. Dissect and clean along the course of the right coronary and identify the right marginal artery. Variability in the amount of fat on the heart surface will influence the quality of this dissection. Preserve the coronary veins accompanying the coronary arteries. Identify the small cardiac vein.

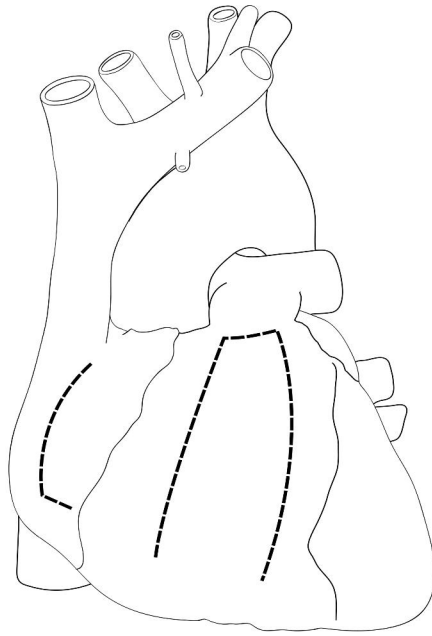Second, perform a dissection of the posterior surface of the heart. Follow the circumflex artery between the left atrium and left ventricle and dissect its major branch, the posterior ventricular artery. On the right side continue dissection of the right coronary and its branch, the posterior interventricular artery. Attempt to dissect additional branches of the coronary distribution including the anterior right atrial branch and the artery to the atrioventricular node. Identify the middle cardiac vein and the coronary sinus. Identify the point of termination of the coronary sinus in the right atrium.

The interior of the heart must be dissected following incisions through the myocardium into the chambers. The ease with which this is accomplished depends greatly on first identifying the coronary sulcus and the interventricular sulci and proper identification of the major vessels at the base of the heart that will serve as landmarks.

The opening of the heart chambers will follow the flow of blood through the heart.

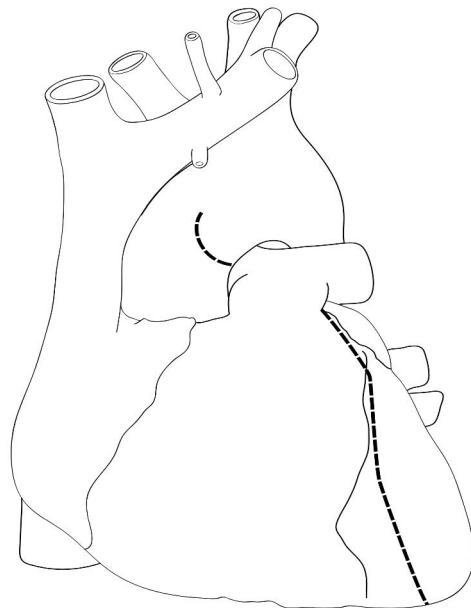
To open the right atrium make an incision at the junction of the superior vena cava and the atrium. Use a scissors and cut downward toward the inferior vena cava. Before reaching the inferior vena cava extend the cut horizontally toward the coronary sulcus. Open the muscular flap and remove clotted blood from this chamber. Observe the interior of the right atrium identifying the opening of the coronary sinus, the crista terminalis, the interatrial wall and fossa ovale, and pectinate muscles. Observe the tricuspid (atrioventricular) valve.

To open the right ventricle make a 1 cm. horizontal incision at the base of the pulmonary trunk. From the right end of this incision use a scissors to cut downward toward the acute margin of the heart 1 cm to the left and parallel to the coronary sulcus. Again use a scissors to cut from the left end of the primary incision downward 1 cm to the right and parallel to the anterior interventricular sulcus. Extend the cut toward the acute margin. Open this muscular flap and remove clotted blood from the right ventricle with care. Do not rupture or sever the chordae tendinae and papillary muscles that might be entwined with the clots. Observe the semilunar valve at the apex of the conus arteriosus, and the interventricular septum. Measure the thickness of the myocardium of this chamber. Of what significance is this thickness?



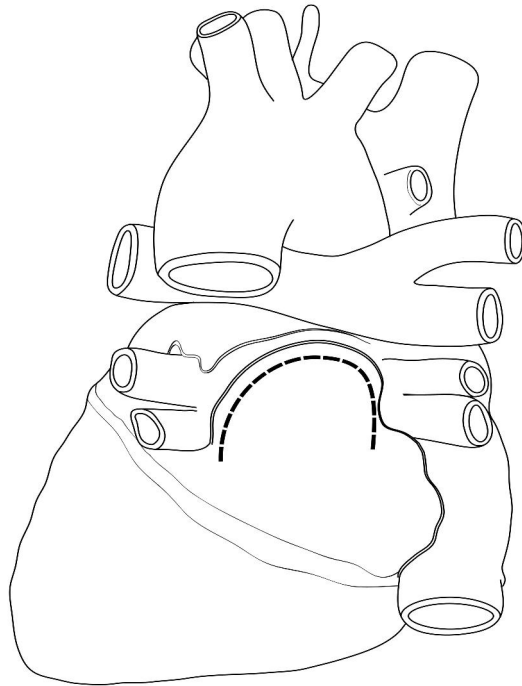
Opening cuts, right atrium and right ventricle
- - - - -

To open the left ventricle cut downward through the wall of the arch of the aorta following the course of the aorta as it emerges from the left ventricle. The cut will carry through the aortic semilunar valve into the ventricular wall on the anterior surface of the heart. Continue the cut to the left of the anteriorinterventricular sulcus to the apex of the heart. The cut will pass through the circumflex artery. Open the left ventricle and remove the clotted blood without damage to the chordae tendinae and papillary muscles. Observe the aortic semilunar valve, its lunules and nodule, and the ostia of the right and left coronary arteries above the level of the semilunar valve. Confirm the patency of the openings of the coronary arteries. Measure the thickness of the myocardium of this chamber. Of what significance is this thickness?



Opening cuts, left ventricle
- - - - -

To open the left atrium use a scissors to cut the posterior wall from the inferior left pulmonary vein to the inferior right pulmonary vein in an inverted “u” shape without cutting the entry point of the veins. This cut will run parallel to the extent of the pericardial reflection for the oblique pericardial sinus that you observed with the heart in situ. Open this muscular flap and remove clotted blood from the left atrium with care. Observe the interatrial wall and the bicuspid (mitral) atrioventricular valve.



Opening cuts, left atrium

Identify the location of the sinuatrial and atrioventricular nodes and the septomarginal trabeculum (moderator band) of the right ventricle. Identify the membranous and muscular portions of the interventricular septum. Investigate any septal defects between the atria and the ventricles.

Posterior Mediastinum

November 2 (As of this date you should have progressed this far in the dissection)

Goals:

- 1. Dissect the posterior mediastinum including the thoracic sympathetics.**
- 2. Dissect the azygos system of veins and lymphatic structures of the thorax.**

Incise the posterior wall of the pericardium to expose the descending aorta and esophagus. Follow the right and left vagus nerves as they become anterior and posterior on the esophagus, respectively. Follow the vagus nerve proximally on each side to the level of the recurrent laryngeal branch. On the left side, dissect the ligamentum arteriosum and note the relationship of the left recurrent branch of the vagus to it.

From the right side, mobilize the esophagus and descending aorta and dissect the azygos vein to its point of entry into the superior vena cava. Dissect the tributaries into the azygos, the hemiazygos and accessory hemiazygos veins on the left side of the vertebral column.

Locate the fragile thoracic duct lying on the anterior surface of the vertebral bodies after careful dissection through the pleura. Follow it distally to the cisterna chylifera and proximally to its entry at the juncture of the jugular and subclavian veins.

Remove pleura from the lateral aspect of the vertebral column exposing the thoracic sympathetic trunk and associated ganglia. Identify the greater (from T5-9) and lesser (from T10-11) splanchnic nerves. With the parietal pleura removed, dissect a pair of posterior intercostal arteries and an intercostal nerve. Note their segmental arrangement along the descending aorta.

Superior Mediastinum

Goals:

- 1. Dissect the great vessels arising from the arch of the aorta.**
- 2. Dissect the nerves and viscera of the superior mediastinum.**

Using a bone saw vertically divide the remaining portion of the sternum and reflect it and the attached clavicle and first rib laterally to expose the superior mediastinal region.

Identify the superior vena cava formed by the right and left brachiocephalic trunks. Identify the arch of the aorta and its branches, the brachiocephalic artery, left common carotid artery, and left subclavian artery. Identify the right and left subclavian veins and right and left internal jugular veins.

Nestled beneath the arch of the aorta dissect the pulmonary trunk and division into the left and right pulmonary arteries. Isolate the ligamentum arteriosum connecting the left pulmonary artery with the aorta.

Differentiate the phrenic nerves on each side from the vagus nerves, following each from superior to inferior levels in this region.

Clean and separate the trachea and the esophagus, noting their anterior-posterior relationship. Identify the tracheal bifurcation. Observe the cartilaginous tracheal rings.

*******EXAM*******

Note: The first exam consists of a written and laboratory component. The exam will cover all material to this point in the course (above this dotted line). The class will be divided in half, the first half taking the written test and the second half taking the lab test. The groups will then switch; the exams are identical for each group. The exams will include radiology, embryology, and cross-sectional anatomy. The questions for the written portion are multiple choice; the

questions for the lab are identification of tagged structures on the cadavers, identification of images displayed on the computer screens, and identification of structures on models, plastinated specimens and other resource materials. You will have two hours to complete the written exam. The lab exam is timed, with one (1) minute for each question. You are not allowed to touch any tag or item on the lab exam.

Anterior Abdominal Wall

November 6 (As of this date you should have progressed this far in the dissection)

Goals:

- 1. Dissect the muscles, nerves and vessels of the anterior abdominal wall.**
- 2. Dissect the inguinal region.**
- 3. Dissect the external genitalia.**

Remove skin from the level of the costal margin to the pubic symphysis and laterally on each side down to the iliac crest. Carefully remove the skin in the region of the inguinal ligament and preserve cutaneous nerves in this region. A significant deposit of superficial fascia (Camper's fascia) may be in the upper and/or lower abdominal region. Note the deep layer of fascia in this region (Scarpa's fascia).

Locate anterior and lateral cutaneous branches of thoracic nerves 7-12. Note small cutaneous arteries and veins and review the origin and distribution of the superficial epigastric and superficial circumflex iliac arteries and veins. Learn the position of the umbilical venous plexus and recall the location of the thoracoepigastric veins.

Study the external oblique muscle. Identify its fleshy and aponeurotic portions. Note that the caudal portion of the aponeurosis is reinforced and forms the inguinal ligament while its medial portion contributes to the sheath of the rectus abdominis muscle. Identify the linea alba and linea semilunaris. Detach a portion of the fleshy component and lift it to expose the underlying internal oblique muscle.

Study the internal oblique muscle. Identify its fleshy and aponeurotic portions. Through an incision into it, separate the fleshy component from the underlying transverse abdominis muscle.

Dissect the nerves coursing between the external oblique and transverse abdominis muscles. Locate the iliohypogastric and ilioinguinal nerves. Isolate a portion of the transverse abdominis muscle and note the change in muscle fiber direction from that of the internal and external oblique abdominal muscles.

Open the rectus abdominis muscle sheath by a longitudinal incision through the deep fascia enveloping the muscle, separate the upper layer of this fascia from the underlying muscle and note the direction of its fibers. Note the transverse connective tissue fibers in the muscle above and below the umbilicus.

Lift the rectus abdominis muscle and dissect the inferior epigastric artery and vein from its undersurface, following these diagonally and inferiorly in the sheath. Note the posterior layer of the rectus sheath and identify the arcuate line.

Identify the parietal peritoneum as the continuous layer beneath the transverse abdominis and rectus abdominis muscles and their aponeuroses. Do not cut the peritoneum at this point in the dissection and do not enter the abdominal cavity.

Carefully dissect inferiorly along the inguinal ligament from the anterior superior iliac spine to the pubic tubercle. Locate and clean the margins of the superficial inguinal ring. Expose the spermatic cord and dissect the ilioinguinal nerve exiting the inguinal canal. Identify the iliohypogastric nerve penetrating the fascia medial to the ring. Identify the medial and lateral crus of the inguinal ring. Note that the round ligament of the uterus traverses the inguinal canal and passes through the superficial inguinal ring in the female.

Do not dissect below the inguinal ligament at this time (i.e. into the region of the femoral triangle)

Male: Make an incision from the superficial inguinal ring to the scrotum and isolate the spermatic cord and testes. Dissect the three fascial investments of the spermatic cord and testis: external spermatic fascia, cremasteric fascia and muscle, and the internal spermatic fascia. The internal spermatic fascia is continued around the parietal layer of the tunica vaginalis testis. Within the internal spermatic fascia of the cord surrounded by loose connective tissue identify the ductus deferens, deferential artery, testicular artery, and pampiniform plexus of veins.

Cut through the fascial layers of the testis and demonstrate the visceral and parietal layers of the tunica vaginalis testis and the cavity between them. Note the size and shape of the testes and identify the head, body, and tail of the epididymis.

Skin the penis and separate the corpora cavernosa penis. Free the retropubic tissue from the posterior surface of the symphysis pubis and make a longitudinal cut through the symphysis. If necessary remove $\frac{1}{4}$ inch of bone from each pubis to expose the anterior surfaces of the urinary bladder and prostate gland. Incise the anterior wall of the bladder longitudinally and continue the incision to open the prostatic, membranous, and spongy portions of the urethra. Identify in the prostatic urethra the urethral crest, seminal colliculus, prostatic utricle, openings of the ejaculatory ducts, and the ducts of the prostate gland.

Female: Dissect from the superficial inguinal ring to the labia majora and identify the round ligament of the uterus inserting into the subcutaneous tissue of the labia majora.

Free the retropubic tissue from the posterior surface of the symphysis pubis and make a longitudinal cut through the symphysis. If necessary remove $\frac{1}{4}$ inch of bone from each pubis to expose the anterior surface of the urinary bladder. Observe the length of the female urethra. Identify the mons pubis, labia majora, labia minora, clitoris, urethral opening, and vaginal opening.

Abdominal Viscera

November 9 (As of this date you should have progressed this far in the dissection)

Goals:

- 1. Observe and know the *in situ* relationships of the abdominal viscera.**
- 2. Dissect the abdominal vessels, nerves and viscera.**

Incise the peritoneum from the xiphoid process to the pubic symphysis and cut transversely below the diaphragm to expose the abdominal contents.

Note the size and position *in situ* of the organs and name those observed before dissection continues. Identify the greater omentum and mobilize it by breaking adhesions to the underlying organs and the peritoneum. Identify the right and left lobes of the liver, gall bladder (if present) and spleen (if present) and note their *in situ* positions. Identify the falciform ligament and the ligamentum teres of the liver.

Pick up the small intestines (jejunum and ileum) *en masse* and place them toward the left side of the body cavity. Trace the root of the small intestine. Identify the ileocecal junction, cecum, appendix and ascending colon. Lift and move the bulk of the small intestine to the right side and identify the descending, sigmoid colon, and upper portion of the rectum. Lift the greater omentum and identify the transverse colon and its continuation onto the greater curvature of the stomach.

Do not remove the intestines.

Identify the lesser curvature of the stomach. Lift the liver and observe the porta hepatis on the visceral surface. Grasp the free margin (hepatoduodenal ligament) of the lesser omentum and place a finger behind the bile duct, hepatic artery, and hepatic portal vein thereby entering through the omental (epiploic) foramen into the lesser omental bursa. Dissect the lesser omentum consisting of the hepatoduodenal and hepatogastric ligaments attaching to the duodenum and lesser curvature of the stomach.

Mobilize the liver by cutting the coronary and triangular ligaments attaching it to the diaphragm. Cut the falciform ligament along its attachment to the anterior abdominal wall. Using a scissors cut the inferior vena cava where the hepatic veins enter. Identify the caudate and quadrate lobes.

Identify the gall bladder and blunt dissect it from its fossa between the right and quadrate lobes.

Depending on the size and mobility of the liver it may be necessary at this time to remove a large portion of it for purposes of continuing the dissection. If necessary, remove the liver with the exception of a portion of it at the porta hepatis connecting it to structures in the hepatoduodenal ligament (hepatic portal vein, bile duct, hepatic artery).

Identify the lesser curvature of the stomach and dissect in the midline to the level of the abdominal aorta. Immediately inferior to the aortic hiatus expose the celiac trunk and its

branches, the left gastric, splenic, and common hepatic arteries. Immediately superior to the celiac trunk clean and dissect the right and left inferior phrenic arteries. Trace the main tributaries of the celiac to the organs that they supply.

Dissect the celiac ganglion and plexus adjacent to the celiac trunk. Dissect and identify the contributions to this ganglion by the anterior and posterior vagal trunks and thoracic splanchnic nerves (greater lesser and least). Also note the concentration of periaortic lymph nodes.

Dissect through the lienorenal and gastrosplenic ligaments and mobilize the spleen. Dissect the splenic artery and vein and its branches at the hilum of the spleen. Identify the left gastroepiploic artery. Dissect the splenic vein from the spleen to its junction with the superior mesenteric vein; this junction defines the origin of the hepatic portal vein. Dissect the entry of the inferior mesenteric vein into either the superior mesenteric vein or the splenic vein. Follow the splenic artery from the spleen back to the celiac trunk.

Dissect the common hepatic artery. Identify the right gastric artery and the gastroduodenal artery at the first portion of the duodenum. Follow this artery along the greater curvature of the stomach as the right gastroepiploic artery. Dissect the anterior and posterior superior pancreaticoduodenal arteries. Note that the venous tributaries of the celiac vascular supply drain to the hepatic portal vein.

Identify the pancreas: head neck body, tail, uncinata process. Dissect the superior mesenteric artery and vein. Dissect the splenic artery and vein from the gland. Note the extent of the pancreas and the position and relationship of the tail to the spleen, the body to the stomach, and the head to the duodenum. Identify the first through fourth portions of the duodenum and locate the suspensory ligament of the duodenum (ligament of Treitz) at the duodenal-jejunal junction.

Dissect the entrance of the bile duct at the second portion of the duodenum. Follow the bile duct proximally to the cystic duct and the common hepatic duct. Dissect and identify the relationships of these ducts to the liver and gall bladder. Incise the duodenum along its greater curvature and place a probe into the opening of the bile duct at the major papilla. Confirm that the main pancreatic duct joins the bile duct at the ampulla.

Dissect the hepatic artery distal to the gastroduodenal artery. Identify the cystic artery and right and left hepatic arteries.

November 11 (As of this date you should have progressed this far in the dissection)

Dissect immediately inferior to the celiac trunk and identify the superior mesenteric artery and its branches.

Using a blunt probe or closed scissors stroke the mesentery of the small intestine and expose the branching arterial and venous vessels. Clean the branches from the intestine to their origin. Identify ileojejunal, ileocolic, right colic, and middle colic arteries. Dissect the ileocolic artery and clean the appendicular artery if present. Clean and identify the region of anastomosis between the middle colic artery and the left colic branch of the inferior mesenteric artery.

At the level of the aorta dissect the inferior mesentery artery. Place the small intestines to the right and dissect the ventral surface of the aorta at the level of the third portion of the duodenum. Identify the left colic, sigmoid, and superior rectal branches using the same blunt exposure technique. Follow the inferior mesenteric vein back to its contribution to the portal vein.

With the intestines displaced to the right incise the parietal peritoneum to expose the abdominal aorta, inferior vena cava, and bifurcation of these vessels at the level of the sacral promontory.

Posterior Abdominal Viscera

Goal:

1. Dissect the kidneys and associated retroperitoneal viscera.

Carefully incise the perirenal fascia and expose the right and left kidneys. Preserve the adrenal glands at the upper pole of each kidney. Lift the kidney from its fascia and carefully bluntly dissect the hilum and clean the renal artery, renal vein, and the ureter. On the left side dissect the renal vein and clean the entrance of the left gonadal vein. Continue dissection of the left renal vein across the midline to the inferior vena cava.

After incising the perirenal fascia and fat lift the right kidney and dissect the hilum and clean the renal artery, renal vein, and the ureter. On the right side dissect the renal vein to the inferior vena cava. Note differences in the length of the right and left renal arteries and veins.

On both sides, isolate and identify the adrenal gland and dissect its vasculature: superior adrenal branches from the inferior phrenic arteries, middle adrenal artery from the aorta, and inferior adrenal artery from the renal artery.

Locate and dissect the right and left gonadal (ovarian/testicular) arteries and the middle sacral artery at the bifurcation of the aorta.

Posterior Abdominal Wall

November 12 (As of this date you should have progressed this far in the dissection)

Goals:

- 1. Dissect the abdominal surface of the diaphragm.**
- 2. Dissect the muscles and nerves of the posterior abdominal wall.**

Lift and spread the diaphragm observing the features from the abdominal side. Identify the central tendon, vena caval foramen, esophageal hiatus, aortic hiatus, right and left crus, and the medial and lateral arcuate ligaments. On the thoracic surface view the innervation by the phrenic nerves on each side.

Dissect any remaining peritoneum holding the ascending and descending colon to the dorsal body wall. Move the viscera right or left to expose the dorsal body wall. Identify the psoas major and minor, quadratus lumborum and iliacus muscles. At the 12th rib, dissect the subcostal nerve.

Clean and identify the iliohypogastric and ilioinguinal nerves and the lateral femoral cutaneous nerve.

Dissect the genitofemoral nerve passing through the substance of the psoas muscle.

Carefully cut the psoas transversely at L2 and L4 and remove it to expose the underlying lumbar plexus nerves. Do not cut the genitofemoral nerve passing through the muscle. Identify the remaining nerves of the lumbar plexus: lumbosacral trunk, femoral nerve, obturator nerve. Also clean and identify the lumbar sympathetic trunk. Dissect a pair of lumbar arteries and note their distribution.

Pelvis

November 16 (As of this date you should have progressed this far in the dissection)

Goals:

- 1. Dissect the female reproductive organs.**
- 2. Dissect the deep inguinal ring and its contents.**
- 3. Dissect the lumbar plexus and iliac arteries.**
- 4. Dissect the perineum.**

In an intact female cadaver observe the uterus, fallopian tube, ovaries, broad ligament, mesovarium, mesosalpinx, and round ligament. Note the position of the uterus relative to the urinary bladder and rectum. Identify the rectouterine pouch.

In the male, clean the ductus deferens from the deep inguinal ring to the base of the bladder. In the female clean the round ligament from the uterus to the deep inguinal ring.

Dissect the ureter on each side from the peritoneum and follow its course to the posterior base of the bladder. Identify the retropubic space on the anterior surface of the bladder.

Return to the sacral promontory and expose the common iliac, internal iliac, and external iliac artery and veins. Additional dissection of the distribution of the internal iliac artery will be done after hemisection of the pelvis (see removal of the leg instructions below). Dissect the external iliac artery and vein to the level of the inguinal ligament. Clean and identify the deep circumflex iliac and inferior epigastric arteries.

Dissect the femoral nerve from the lumbar plexus to the level of the inguinal ligament. Dissect the obturator nerve to the opening of the obturator canal in the fascia of the obturator internus muscle.

Perineum

The perineum is separated from the pelvic cavity by the pelvic diaphragm (levator ani and coccygeus muscles). Abduct the legs and remove skin and superficial fascia from the perineum to expose the membranous layer of the perineal fascia (Colles' fascia). This layer, the perineal membrane, forms the inferior boundary of the superficial perineal pouch.

At the free edge of the urogenital triangle identify the superficial transverse perineal muscle. Incise the perineal membrane and identify the deep transverse perineal muscle. In the superficial pouch of both the female and male identify the ischiocavernosus and bulbospongiosus muscles.

The deep perineal pouch contains branches of the pudendal nerve and pudendal artery. Clean and identify the dorsal nerve and artery of the clitoris in the female cadaver, and the dorsal nerve and artery of the penis in the male cadaver. Follow these nerves and arteries posteriorly to their origins, the pudendal nerve and internal pudendal artery. These emerge from the ischioanal fossa inferior to the sacrotuberous ligament and can be visualized upon removal of the fatty superficial fascia in the fossa (best done with the cadaver in the prone position with legs abducted). In this position, note the boundaries of the perineum and the anal and urogenital triangles which are identical in the male and female.

The pelvic dissection will continue after hemisection of the pelvis and removal of one of the legs. Prior to this procedure, clean and identify as much of the internal iliac artery as possible tracing the proximal portion of the anterior and posterior divisions. Room for dissection in the pelvis prior to removal of a leg will limit the extent of identifications.

Place the cadaver in the supine position. First make a double ligature around the rectum and cut between these ligatures to sever the rectum. Do not spill fecal contents into your dissection. Spread the legs and make a midsagittal incision through the soft tissues of the perineum including the external genitalia.

November 17 (As of this date you should have progressed this far in the dissection)

Goals:

- 1. Hemisect the pelvis and remove the leg.**
- 2. Dissect the iliac arteries, sacral plexus, and muscles of the inner wall of the pelvis.**
- 3. Dissect the urinary bladder**

To remove one of the legs make a saw cut using a hacksaw through the pubic symphysis in the midsagittal plane. Continue the saw cut through the sacrum to L4-5. Incise laterally on one side through the abdominal wall immediately above the iliac crest. Remove the leg.

The inner muscular pelvic wall consists of the obturator internus, piriformis, levator ani and coccygeus muscles. On the surface of the piriformis identify the roots of the sacral plexus and the descending lumbosacral trunk. Dissect the contributions of these roots to the sciatic nerve and the pudendal nerve. Dissect and identify the superior and inferior gluteal nerves, and the nerve to the piriformis. Dissect the posterior femoral cutaneous nerve. Dissect the sacral sympathetic trunk (the ganglion impar will have been sacrificed due to hemisection of the coccyx). The coccygeal plexus is a small network of nerves formed by the ventral rami of S4 and S5 nerves and the coccygeal nerves. It supplies the coccygeus and part of the levator ani muscle.

Clean and identify the arterial branches of the anterior and posterior divisions of the internal iliac artery. Above the two divisions dissect the iliolumbar and lateral sacral arteries. Dissect the posterior division and identify the superior and inferior gluteal arteries. Note their relationships to the roots of the sacral plexus and the piriformis muscle. Dissect the anterior division noting its division into visceral branches and the obturator artery. Dissect the obturator artery to the obturator canal in the fascia of the obturator internus muscle accompanied by the obturator nerve. Clean and dissect the remaining visceral branches in both the male and (intact) female. Identify the umbilical artery where it distally is obliterated and exists as a ligament. Prior to its obliteration identify the origin and course of the superior vesicle arteries and uterine artery (female). Clean and identify the internal pudendal artery, inferior vesical artery, and middle rectal artery. Identify the vaginal artery, a branch of the uterine artery in the intact female.

Observe the hemisected pelvic viscera and identify: uterus and vagina, urinary bladder and urethra, rectum and anus, prostate gland, seminal vesicles and ejaculatory ducts, and the external genitalia. Follow the ureters to the base of the bladder and locate the ureteric orifices with a blunt probe. Identify the internal urethral orifice and trigone. Trace the urethra in the male through the prostate gland. Trace the female urethra to the external orifice. Note the relationship of the prostate gland to the rectum (the prostate can be palpated by a digit placed against the anterior wall of the rectum). Dissect the ductus deferens to the base of the bladder.

Gluteal Region and Posterior Thigh

November 18 (As of this date you should have progressed this far in the dissection)

Goals:

- 1. Dissect the gluteal muscles, vessels, and nerves.**
- 2. Dissect the sciatic nerve.**
- 3. Dissect the vessels, nerves and muscles of the posterior thigh.**
- 4. Dissect the hip joint.**

Turn the cadaver (or detached lower limb) into the prone position and remove skin covering the gluteal region and thigh. Preserve the lateral femoral cutaneous nerve, posterior cutaneous nerve of the thigh, and great saphenous vein. Note branches of other cutaneous nerves: superior and inferior cluneal nerves, cutaneous branches of the obturator nerve, and anterior cutaneous branches of the femoral nerve.

Clean and dissect the iliotibial tract and remove fascia lata overlying the flexor muscles of the thigh. Identify the tensor fascia lata muscle originating at the iliac crest. Identify the inferior border of the gluteus maximus muscle and use a scissors to cut through its origin adjacent to the ilium and sacrum. Take care not to cut through the underlying sacrotuberous ligament. Reflect the gluteus maximus. Identify the piriformis muscle below which the sciatic nerve and posterior femoral cutaneous nerve of the thigh travels. Also using the piriformis as a landmark dissect the superior and inferior gluteal nerves and arteries. Divide and reflect the gluteus medius and identify the underlying gluteus minimus muscle. Dissect the muscular bellies and tendons of the superior and inferior gemellus muscles and the obturator internus muscle. Inferior to the inferior

gemellus clean and dissect the quadratus femoris muscle. Deep to this lateral rotator group dissect the tendon of the obturator externus muscle.

Expose the pudendal nerve and artery from the iliac fossa to the ischiorectal fossa, following its course toward the anal and urogenital triangles through the greater and lesser sciatic foramina.

Using blunt dissection, separate the posterior thigh muscles (hamstrings). Follow the sacrotuberous ligament to the ischial tuberosity where these muscles originate. Separate the long and short heads of the biceps femoris muscle, and the semimembranosus and semitendinosus muscles. Identify the underlying adductor magnus muscle and follow the course of the sciatic nerve through the thigh into the popliteal fossa where it divides into the tibial nerve and the common fibular (peroneal) nerve. Dissect the popliteal artery and vein as they emerge from the adductor hiatus of the adductor magnus muscle.

On one side incise the hip capsule and expose the head of the femur in the acetabulum. Identify the ligamentum teres of the head of the femur. Observe the surfaces of the articular cartilage. Review the anatomy of the hip articular capsule and arrangement of its fibers as it relates to flexion and extension at the hip.

Medial Thigh

November 19 (As of this date you should have progressed this far in the dissection)

Goals:

- 1. Dissect the muscles of the medial thigh.**
- 2. Dissect the muscles of the anterior thigh.**
- 3. Dissect the popliteal fossa.**

The medial musculature of the thigh adducts the leg. Clean and dissect the gracilis muscle. Separate and identify the pectineus muscle from the adductor group and reflect it. Identify the adductor longus muscle and divide it to expose the underlying adductor brevis muscle. Identify the adductor magnus muscle and note the entrance of the femoral artery and vein into the adductor hiatus. Follow and dissect the obturator nerve traveling from the pelvis and identify its anterior and posterior branches passing around the obturator externus muscle and its terminal afferent branches to the adductor muscles.

Anterior Thigh

Clean the superficial fascia from the fascia lata and dissect the saphenous vein to its entry into the femoral vein at the saphenous opening. Reflect the fascia lata and expose the femoral triangle and femoral sheath. Identify the lateral border of the adductor longus muscle and the medial border of the sartorius muscle and the inguinal ligament; these define the boundaries of the femoral triangle. Incise the femoral sheath and dissect the femoral artery and vein and the femoral nerve in the femoral triangle. Dissect and identify the deep femoral artery from which arise the lateral and medial femoral circumflex arteries.

Clean and identify the rectus femoris muscle and the vastus lateralis, vastus intermedius, and vastus medialis muscles (quadriceps muscles, “quads”). Observe the innervation by the femoral nerve, and dissect the saphenous nerve branch of the femoral nerve in its superficial location. Note the formation of the quadriceps femoris tendon and its continuation beyond the patella to the tibial tuberosity as the patellar ligament.

Popliteal Fossa

Remove the skin from the knee to the ankle, preserving cutaneous nerves and superficial vessels. With the cadaver or leg in the prone position dissect the popliteal artery and its anastomotic branches, the superior medial and lateral genicular arteries and the inferior medial and lateral genicular arteries above and below the joint line, respectively. Continue to dissect the popliteal artery to its point of division into the anterior and posterior tibial arteries immediately inferior to the popliteus muscle and at the uppermost portion of the interosseous membrane between the tibia and fibula. Note the penetration of the anterior tibial artery through this membrane.

Dissect the division of the sciatic nerve into the tibial nerve and the common fibular nerve. Dissect the lateral and medial sural cutaneous nerves and follow them distally noting the point at which they merge to form the sural nerve.

Leg

November 20 (As of this date you should have progressed this far in the dissection)

Goals:

- 1. Dissect the muscles, nerves, and vessels of the leg.**
- 2. Dissect the knee joint.**

Separate and identify the four muscles in the anterior compartment of the leg: tibialis anterior, extensor hallucis longus, extensor digitorum longus, fibularis tertius. Trace the deep fibular nerve accompanying the anterior tibial artery and the superficial fibular nerve. Remove skin from the ankle to the toes and follow the tendons of the anterior muscles beneath the superior and inferior extensor retinacula into the foot. Trace the distal portion of the anterior tibial artery; as it enters the foot it is called the dorsalis pedis artery.

Separate and identify the two muscles of the lateral compartment of the leg: fibularis brevis and fibularis longus. Dissect the superficial fibular nerve that innervates these muscles. Trace the tendons of these muscles as they pass under the retinacula into the foot.

Separate and identify the seven muscles of the posterior compartment of the leg, all of which are innervated by the tibial nerve: gastrocnemius, soleus, plantaris, popliteus, tibialis posterior, flexor digitorum longus, flexor hallucis longus. Reflect the gastrocnemius by cutting through its two heads. Reflect the soleus and dissect the tibial nerve. Identify the fibular artery as a branch

of the posterior tibial artery and dissect it to the level of the lateral malleolus. Dissect the posterior tibial artery to the level of the medial malleolus. Identify the tendons of the tibialis posterior, flexor digitorum longus, and flexor hallucis longus and note their course behind the medial malleolus along with the tibial nerve and posterior tibial artery.

Review the osteology of the distal femur and proximal tibia and fibula. On one side cut the quadriceps tendon and make incisions on each side of the patella to reflect the patella inferiorly. Reflect the muscles and identify the tibial collateral ligament and the fibular collateral ligament. Flex the knee. Within the joint identify lateral and medial meniscus and the anterior and posterior cruciate ligaments. Observe the cartilaginous surfaces of the femoral condyles and tibial plateau noting roughness or absence of cartilage which might indicate degenerative joint disease (arthritis).

Foot

November 23 (As of this date you should have progressed this far in the dissection)

Goals:

- 1. Know the tarsal bones.**
- 2. Dissect the muscles, nerves, tendons, and vessels of the foot.**

Remove skin from the dorsal and plantar surfaces of the foot and toes. Make a horizontal incision through the plantar aponeurosis at the base of the toes. In the midline of the sole of the foot, incise the plantar aponeurosis longitudinally and reflect it to reveal the underlying flexor digitorum brevis muscle. Cut transversely through the flexor digitorum brevis and reflect it. Dissect the medial plantar nerve and the lateral plantar nerve and trace these back to the medial malleolus where they arise from the tibial nerve. Dissect the branches of these nerves into first the common plantar digital nerves and then the proper plantar digital nerves.

On the lateral side of the sole of the foot dissect and identify the abductor digiti minimi muscle, and dissect and identify the abductor hallucis muscle on the medial aspect of the sole of the foot. Mobilize these muscles but do not cut them. More deeply situated is the tendon of the flexor digitorum longus muscle; dissect it and identify the four lumbrical muscles arising from the tendon. Dissect and identify the quadratus plantae muscle and note its attachment to the tendon of the flexor digitorum longus muscle. Medial to the first lumbrical locate the tendon of the flexor hallucis longus muscle. Trace all tendons to their points of insertion.

Continue to dissect at a deeper level to identify the flexor digiti minimi, flexor hallucis brevis and the adductor hallucis muscles. Note that the adductor hallucis muscle has two heads, a transverse head and an oblique head. Palpate the flexor hallucis brevis tendons at the base of the proximal phalanx of the great toe for the presence of sesamoid bones.

At the deepest level identify the four dorsal and three plantar interosseous muscles, noting that the reference axis for abduction and adduction is through the second toe.

Study the bones of the foot and the ligaments of the foot, and note the dense arrangement of ligaments in the cadaver. Specifically dissect the medial ligament complex inferior to the medial malleolus. The deltoid ligament consists of four components. Observe these components in an atlas and expose the complex in the cadaver. Do not cut these ligaments. Study the ligaments of the lateral side of the foot. On the medial aspect of the base of the foot identify the plantar calcaneonavicular ligament, also known as the spring ligament.

*******EXAM*******

Note: The second exam covers all material since the previous exam, including radiology, embryology, and cross-sectional anatomy. The format for the exam will be the same as that for the previous exam.

Skull and Cranial Cavity

December 1 (As of this date you should have progressed this far in the dissection)

Goal:

1. Identify the osteology of the skull and skull base and the location of all cranial nerves that exit the skull.

Review the osteology of the head, including sutures, foramens, and processes. Since most cadavers have undergone prior removal of the brain, remove the remaining skin over the cranium and open the cranial cavity. Identify the dura adherent to the endocranium and its associated dural venous sinuses and the route of drainage from these sinuses to the internal jugular vein. Identify the falx cerebri and tentorium cerebelli and their attachments.

Identify the location and route of travel of the twelve cranial nerves as they enter/exit the skull (olfactory, optic, oculomotor, trochlear, trigeminal, abducent, facial, vestibulocochlear, glossopharyngeal, vagus, spinal accessory, hypoglossal). Using a forceps strip the dura from the fossae of the inner surface of the skull and identify the major foramens through which the nerves pass.

Eye and Orbit

December 2 (As of this date you should have progressed this far in the dissection)

Goal:

1. Dissect the orbit and its contents.

Using a hand saw make two vertical cuts through the frontal bone one each through the medial and lateral superior orbital margin. Carefully remove the frontal bone piece and the attached roof portion of the orbit exposing the periorbital tissues. Insert a probe beneath the lesser wing of the sphenoid into the middle cranial fossa and break through the overlying bone with a small chisel to expose the optic canal. Using a scissors incise the periorbital tissue and dissect the underlying frontal nerve.

Carefully remove the periorbital tissue and use small instruments for the remainder of this dissection. Dissect the frontal nerve and its division into the supratrochlear nerve and supraorbital nerve, the lacrimal nerve and the trochlear nerve, all of which lie superior to the extraocular muscles. Dissect the lacrimal gland.

Differentiate the nerves from branches of the ophthalmic artery. Dissect the levator palpebrae superioris muscle. Divide and reflect the levator palpebrae muscle. Clean the margins of the superior rectus muscle and the superior oblique muscle. Divide and reflect the superior rectus muscle and identify its innervation from the oculomotor nerve. Dissect the superior oblique muscle to the trochlea and follow the course of its tendon to the point of insertion in the sclera.

On the lateral surfaces of the eyeball identify the lateral rectus muscle and the medial rectus muscle and their innervations from the abducent nerve and oculomotor nerve, respectively. Dissect the nasociliary nerve toward the medial wall of the orbit and its branching long ciliary nerves to the posterior of the eyeball. Between the optic nerve and lateral rectus muscle dissect the ciliary ganglion and the short ciliary nerves connecting the ganglion to the posterior eyeball. Identify the anterior ethmoidal nerve.

From the anterior, incise the conjunctiva and dissect the inferior oblique muscle and the inferior rectus muscle. Follow the tendon of the inferior oblique to its insertion in the sclera.

Identify the conjunctiva, sclera, iris and pupil. Identify the superior and inferior lacrimal papillae and the lacrimal caruncle. Using a text or atlas, study the pattern of drainage of lacrimal fluid across the eye into the lacrimal sac and nasolacrimal duct.

Neck

December 3 (As of this date you should have progressed this far in the dissection)

Goals:

- 1. Dissect the carotid sheath and its contents, the suprahyoid and infrahyoid muscles, thyroid gland and ansa cervicalis.**
- 2. Dissect the carotid artery and its branches, and nerves of the neck.**

Remove the platysma muscle from the neck and clean the external jugular vein. It is formed from the retromandibular vein and the posterior auricular vein. Dissect the facial vein and the anterior jugular vein. Note variability in these tributaries. The anterior jugular vein and the facial vein join the external jugular vein.

Clean the sternocleidomastoid muscle. On one side cut transversely at its midpoint and reflect it. Dissect the omohyoid muscle (superior and inferior bellies) and its fascial sling that divides the muscle attached to the proximal part of the clavicle. Observe the musculature above and below the hyoid bone. Below the hyoid dissect the sternohyoid muscle. Cut through the sternohyoid muscle at its midpoint and reflect it. Dissect but do not cut the sternothyroid muscle and the thyrohyoid muscle. In the midline dissect the margins of the isthmus portion of the thyroid gland and clean the borders of the gland laterally to the left and right lobes. Identify the tracheal cartilaginous rings below the isthmus portion of the thyroid. Identify the thyroid cartilage of the larynx superior to the thyroid gland but inferior to the hyoid bone. Identify the laryngeal prominence and thyroid cartilage incisure and the thyrohyoid membrane.

Above the hyoid bone dissect the mylohyoid muscle and the anterior belly of the digastric muscle. Note the fascial sling of the tendon of the digastric muscle that divides the anterior and posterior bellies of the digastric muscle.

Elevate the superior portion of the transected sternocleidomastoid muscle and dissect the spinal accessory nerve tracing it distally to the trapezius muscle. Dissect the hypoglossal nerve and clean it proximally to locate the superior root of the ansa cervicalis lying on the carotid sheath. Continue to expose the inferior root of the ansa cervicalis and branches of the ansa to the “strap” muscles.

Expose the common carotid artery and internal jugular vein by dissecting through the carotid sheath. Identify the vagus nerve and the superior laryngeal nerve arising from the vagus nerve. Follow the superior laryngeal nerve to its branches, the internal laryngeal nerve that will penetrate the thyrohyoid membrane, and the external laryngeal nerve to the cricothyroid muscle of the larynx.

Dissect the vagus nerve distally and identify the recurrent laryngeal nerve. Trace the recurrent laryngeal nerve as it passes proximally to the larynx. Note its relationship to the thyroid gland in the course of its travel to the larynx.

Dissect the common carotid artery to the level of the greater horn of the hyoid bone where it bifurcates to the external carotid artery and the internal carotid artery. Identify the internal carotid artery. Dissect the branches of the external carotid artery: superior thyroid artery, ascending pharyngeal artery, lingual artery, occipital artery, facial artery, posterior auricular artery, maxillary artery, superficial temporal artery. Some of the more distal branches will not be visible until a portion of the mandible is removed and the deep face is dissected.

Remove the middle one-third of the clavicle taking care to preserve the omohyoid muscle. Clean and dissect the internal jugular vein to its entry into the subclavian vein. Dissect the common carotid artery to its origin from the brachiocephalic artery/arch of the aorta. Distal to the origin of the common carotid artery dissect the vertebral artery and thyrocervical trunk. Identify the inferior thyroid artery, transverse cervical artery, and suprascapular artery arising from the thyrocervical trunk. Dissect the internal thoracic artery and the costocervical trunk which arise in the root of the neck medial to the first rib.

Clean and identify the anterior, middle, and posterior scalene muscles. Dissect the phrenic nerve lying on the anterior scalene. Trace the nerve into the thorax. Dissect the roots and trunks of the brachial plexus emerging from between the anterior and middle scalene muscles. Dissect the cervical sympathetic chain and identify the superior cervical ganglion.

Using fingers push behind the viscera of the neck anterior to the cervical vertebral column at the level of the thyroid cartilage. Lift the viscera forward; the fingers are within the retropharyngeal space. Work the fingers superiorly to the base of the occipital bone, and inferiorly to the superior thoracic aperture. This space extends into the superior mediastinum.

Superficial Face

December 4 (As of this date you should have progressed this far in the dissection)

Goals:

- 1. Dissect the superficial face muscles, nerves and vessels.**
- 2. Dissect the parotid gland and facial nerve.**

Carefully remove the (thin) skin from the face, forehead and neck. In the superficial fascia locate the parotid gland. In the neck observe the platysma muscle within the superficial fascia. Dissect the parotid duct arising from the anterior of the gland and follow its course across the masseter muscle where it turns medially and pierces the buccinator muscle of the cheek and enters the oral cavity.

Dissect the superficial muscles of the face. Identify the occipitofrontalis, orbicularis oculi, levator labii superioris alaeque nasi, nasalis, levator labii superioris, levator anguli oris, zygomaticus minor and major, orbicularis oris, depressor anguli oris, depressor labii inferioris mentalis, and buccinator muscles.

Dissect through the parenchyma and dense connective tissue of the parotid gland and identify the five main branches of the facial nerve: temporal, zygomatic, buccal, mandibular, and cervical branches. Differentiate these motor nerves from sensory branches arising from the supraorbital foramen of the frontal bone, infraorbital foramen of the maxilla, and the mental foramen of the mandible (branches of the trigeminal nerve).

Deep Face

December 4 (As of this date you should have progressed this far in the dissection)

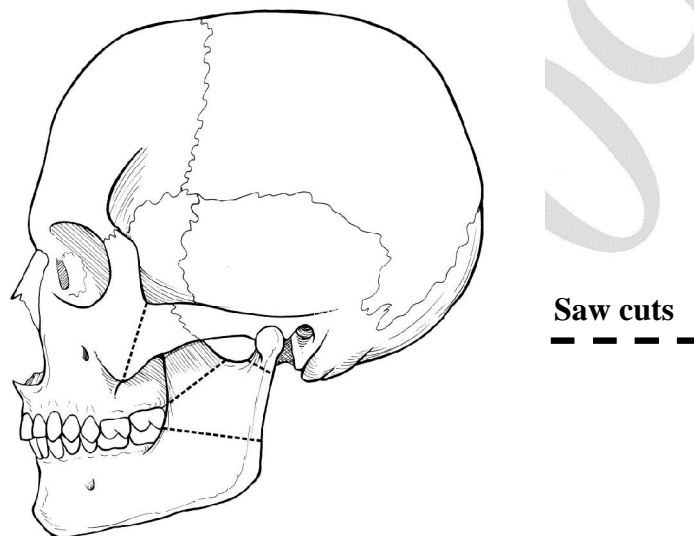
Goals:

- 1. Remove a portion of the mandible to enter the deep face.**
- 2. Dissect the external carotid artery to its terminal branches.**
- 3. Dissect the muscles, nerves, and vessels of the deep face.**

Reflect the facial nerve branches and the parotid duct. Clean the masseter muscle away from the ramus of the mandible exposing the mandible surface. Place a blunt probe beneath the zygomatic arch and depress the temporalis muscle by drawing the probe several times from left to right beneath the arch.

Using an electric saw, cut the zygomatic arch adjacent to the temporomandibular joint and also near the orbit. Refer to the cut lines as shown on the diagram. Remove the arch. Identify the head and coronoid process of the mandible.

Cut the head of the mandible and the coronoid process with a saw. Make a horizontal cut across



the ramus at the level of the last molar tooth. Carefully remove this trapezoid-shaped portion of the ramus taking care not to injure the underlying structures, particularly the inferior alveolar nerve and inferior alveolar artery which enter the mandibular foramen on the medial surface of the mandible. Upon removal of this piece of bone the dissection of the distal branches of the external carotid artery can be completed.

Dissect the temporalis muscle and its attachment on the coronoid process of the mandible. Reflect the muscle superiorly along with the detached coronoid process.

Identify and dissect the lateral and medial pterygoid muscles deep to the mandible. Dissect the inferior alveolar nerve and lingual nerve, both of which lie on the surface of the medial pterygoid muscle.

Carefully remove the lateral pterygoid muscle preserving adjacent arteries and nerves. Once removed, clean the superficial temporal artery and dissect the proximal portion of the maxillary artery. Dissect the distal portion of the maxillary artery and its branches: the middle meningeal artery, deep temporal arteries, buccal artery, posterior superior alveolar artery, and the sphenopalatine artery upon entering the pterygopalatine fossa.

Dissect the remaining major branches of the mandibular nerve: buccal nerve, lingual nerve, and auriculotemporal nerve. Follow the lingual nerve proximally and dissect the chorda tympani

nerve (from the facial nerve) which joins the lingual nerve to travel to the tongue. Dissect and identify the nerve to the mylohyoid arising from the inferior alveolar nerve.

Dissect along the maxillary artery to its third portion, identifying vessels arising from it just prior to its entry into the pterygopalatine fossa. Dissect the posterior superior alveolar artery and its accompanying posterior superior alveolar nerve. Trace this nerve back to the infraorbital nerve which enters the inferior orbital fissure.

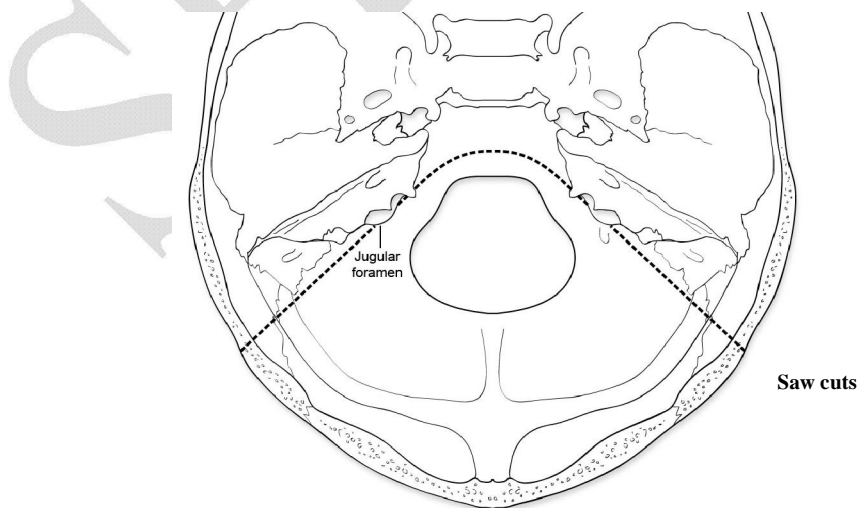
Palpate the styloid process. Differentiate it from the muscles arising from the styloid process: stylohyoid muscle, stylopharyngeus muscle, styloglossus muscle. Dissect the glossopharyngeal nerve which pierces the stylopharyngeus muscle. Differentiate these muscles from the posterior belly of the digastric muscle. Note the structural relationship of the styloglossus and hyoglossus muscle as they converge on the tongue. The lingual nerve lies lateral to the point at which these two muscles converge as does the submandibular ganglion, submandibular gland and submandibular duct. Note that the lingual nerve “hooks” underneath the duct at the anterior border of the hyoglossus muscle. Distinguish the lingual nerve from the hypoglossal nerve passing deep to the posterior belly of the digastric muscle.

December 7 (As of this date you should have progressed this far in the dissection)

Objective: Separate the visceral component of the neck from the vertebral component.

Objective: Dissect the larynx.

Division of the occiput will facilitate the following dissection of the visceral neck. Identify the jugular foramen from the inside of the skull. Make saw cuts through the occipital bone on each side from lateral to medial at an angle to the posterior margin of the jugular foramen. Chisel through the basilar part of the occipital bone on an arc from one jugular foramen to the other. Place a finger in the retropharyngeal space and probe upward to the cut. Dissect through the soft tissues and separate the visceral neck anteriorly.



The posterior muscles of the pharynx can now be dissected. Identify the superior, middle and inferior pharyngeal constrictor muscles and the pharyngeal raphe. Inferior to the constrictors identify the proximal esophagus. Dissect the stylopharyngeus muscle and stylohyoid muscle originating on the styloid process. Dissect the posterior belly of the digastric muscle arising from the mastoid process.

At the jugular foramen dissect and identify the glossopharyngeal nerve, vagus nerve, and spinal accessory nerve and trace their extent. Medial to the jugular foramen dissect the hypoglossal nerve from the hypoglossal foramen and follow it anteriorly.

Make a longitudinal midsagittal incision through the pharyngeal constrictor muscles to expose the oropharynx and larynx. Identify the cricoid cartilage, arytenoids cartilages, and epiglottis. Carefully remove the mucous membrane from the laryngeal muscles: transverse and oblique arytenoids muscles, posterior cricoarytenoid muscle, and aryepiglottic muscle. Remove a thyroid cartilage lamina and expose the thyroarytenoid muscle, thyroepiglottic muscle, and lateral cricoarytenoid muscle. Identify the true and false vocal fold.

Oral and Nasal Cavity

December 9 (As of this date you should have progressed this far in the dissection)

Goals:

- 1. Dissect the oral cavity.**
- 2. Dissect the nasal cavity.**

Using a saw, make a midsagittal cut through the head from the frontal bone through the nasal region and hard palate, tongue, and mandible. Separate the halves using a scalpel to complete soft tissue separation.

Remove the nasal septum to reveal the lateral nasal wall. Identify the superior, middle and inferior nasal concha. Probe the frontal and sphenoidal sinuses and place a flexible probe into the opening of the sphenoid sinus at the level of the superior concha. At the anterior border of the sphenoidal sinus dissect the sphenopalatine foramen and the nasopalatine nerve and sphenopalatine artery entering the nasal cavity at this point. Probe the opening of the pharyngotympanic tube and identify the torus tubarius. Identify the salpingopalatine and salpingopharyngeal fold; under the mucosa of these folds lie the muscles of the same name(s).

Identify the soft and hard palate. Dissect above the soft palate and identify the tensor veli palatini muscle and its tendon turning around the hamulus of the medial pterygoid plate, and the levator veli palatine muscle.

In the posterior oral cavity identify the palatoglossus muscle and the palatopharyngeal muscle. Between the folds of mucosa overlying these muscles identify the tonsillar bed (palatine tonsil).

Remove the mucosa from the tonsillar bed and dissect the styloglossus muscle and the glossopharyngeal nerve deep to the bed.

Return to the posterior region of the nasal cavity and use a probe to identify the sphenopalatine foramen. With the probe in the foramen, chip open the medial wall of the greater palatine canal to expose the greater palatine nerve, lesser palatine nerve, and descending palatine artery. Note the distribution of the nerves on the inferior surface of the hard and soft palate. Trace the nerves proximally to the pterygopalatine ganglion. Chip bone away from the floor of the sphenoid sinus and expose the pterygoid canal containing the nerve of the pterygoid canal.

Ear

December 10 (As of this date you should have progressed this far in the dissection)

Goal:

1. Dissect the petrous portion of the temporal bone to expose the middle ear and its contents.

Identify the superior surface of the petrous part of the temporal bone and remove the dura mater. Identify the facial nerve and vestibulocochlear nerves entering the internal acoustic meatus. Carefully chip away the petrous part of the temporal bone creating a window lateral to the meatus exposing the nerves. Do not remove bone over the internal acoustic meatus, leaving it as a landmark.

Expose the facial nerve to its geniculate ganglion. Dissect the greater petrosal nerve and the lesser petrosal nerve arising from the ganglion. Continue to expose the facial nerve as it goes posteriorly from the ganglion. Chip bone to open the cochlea at the junction between the facial nerve and the greater petrosal nerve.

Continue to chip bone from the roof of the middle ear and expose the malleus, incus, and stapes. On the lateral wall of the middle ear identify the tympanic membrane and the chorda tympani nerve. Identify the oval window, round window, and the tensor tympani muscle.

*******EXAM*******

Note: The third exam covers all material since the previous exam, including radiology, embryology, and cross-sectional anatomy. The format for the exam will be the same as that for the previous exams.