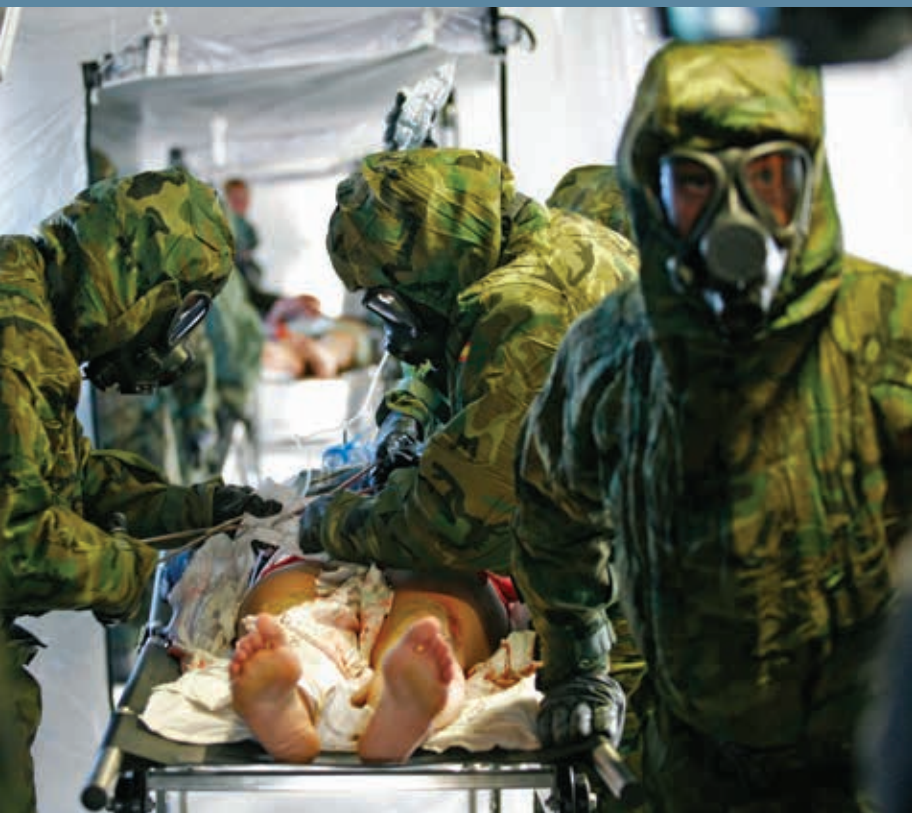

Vascular / Endovascular Surgery Combat Manual



Stone
AbuRahma **Campbell**

Compliments of W. L. Gore & Associates, Inc.

This publication, compliments of W. L. Gore & Associates, Inc. (Gore), is intended to serve as an educational resource for medical students, residents, and fellows pursuing training in vascular and endovascular surgery. Readers are reminded to consult appropriate references before engaging in any patient diagnosis, treatment, or surgery, including Prescribing Information (including boxed warnings and medication guides), Instructions for Use, and other applicable current information available from manufacturers.

Gore products referenced within are used within their FDA approved / cleared indications. Gore does not have knowledge of the indications and FDA approval / clearance status of non-Gore products, and Gore does not advise or recommend any surgical methods or techniques other than those described in the Instructions for Use for its devices.

Gore makes no representations or warranties as to the surgical techniques, medical conditions, or other factors that may be described in this publication.

The opinions and advice expressed herein are those of the authors alone, and do not reflect the opinions or advice of Gore or the West Virginia University.

PERCLOSE®, PROSTAR®, SPARTACORE®, STARCLOSE®, and SUPRACORE® are trademarks of Abbott Laboratories. OMNI FLUSH and SIMMONS SIDEWINDER are trademarks of AngioDynamics. ICAST is a trademark of Atrium Medical Corporation. ASPIRIN® is a trademark of Bayer HealthCare, LLC. MORPH® is a trademark of BioCardia, Inc. AGGRENOX® and PRADAXA® are trademarks of Boehringer Ingelheim Pharma GmbH & Co. KG. AMPLATZ, GREENFIELD®, and WALLSTENT® are trademarks of Boston Scientific Corporation or its affiliates. COUMADIN® and GLUCOPHAGE® are trademarks of Bristol-Myers Squibb. CARDIVA CATALYST is a trademark of Cardiva Medical, Inc. BIRD'S NEST®, COOK®, CELECT, LUNDERQUIST®, PTX®, TX2®, ZENITH®, and ZILVER® are trademarks of COOK® Medical. GENESIS, OPTEASE®, PALMAZ®, and TRAPEASE® are trademarks of Cordis Corporation. FLAIR®, FLUENCY®, and VECTRA® are trademarks of C. R. Bard, Inc. EFFIENT® is a trademark of Eli Lilly and Company. POWERLINK® is a trademark of Endologix, Inc. ANCEF® is a registered trademark of GlaxoSmithKline. ANCURE® is a trademark of Guidant Corporation. DACRON® is a trademark of INVISTA. SYVEK® is a trademark of Marine Polymer Technologies, Inc. SAFEGUARD® is a trademark of MAQUET. BENADRYL® is a trademark of McNEIL-PPC. ANEURX®, ENDURANT®, EVS, PIONEER®, and TALENT are trademarks of Medtronic, Inc. HIBICLENS® is a trademark of Mölnlycke® Healthcare US, LLC. NOVOSEVEN® is a trademark of Novo Nordisk A/S. PLETAL® is a trademark of Otsuka America Pharmaceutical, Inc. SOLU-MEDROL® and SOLU-CORTEF® are trademarks of Pfizer. LOVENOX® is a trademark of sanofi-aventis U.S. LLC. PLAVIX® is a trademark of Sanofi. CLO-SUR PLUS P.A.D is a trademark of Scion Cardio Vascular, Inc. ANGIO-SEAL, FEMOSTOP, and VASOSEAL are trademarks of St. Jude Medical, Inc. GLIDEATH® and GLIDEWIRE® are trademarks of Terumo Medical Corporation. ANGIOMAX® is a trademark of The Medicines Company. VECTRA® is a trademark of Thoratec Corporation. D-STAT® and DUETT are trademarks of Vascular Solutions, Inc. VANCOCIN® is a trademark of ViroPharma Incorporated. ZOSYN® is a trademark of Wyeth Pharmaceuticals Inc.

VASCULAR/ENDOVASCULAR SURGERY COMBAT MANUAL

Patrick A. Stone, MD, FACS

Editor and Chief

Associate Professor of Surgery

Ali F. AbuRahma, MD, FACS

Section Editor Open Vascular Reconstructions

Professor of Surgery

John E. Campbell, MD

Section Editor Vascular Medicine and Endovascular Surgery

Assistant Professor of Medicine and Surgery

Contributing Authors

Saadi Alhalbouni, MD

Vascular Surgery Fellow

Mark C. Bates MD, FACC, FSCAI, FSVM

Professor of Medicine and Surgery

James R. Campbell II, MD

Assistant Professor of Surgery and Medicine

D. Daniel Dearing, MD

Vascular Surgery Fellow

Stephen M. Hass, MD, JD

Assistant Professor of Surgery

Albeir Y. Mousa, MD

Associate Professor of Surgery

Aravinda Nanjundappa, MD, FACC

Associate Professor of Medicine and Surgery

Mohit Srivastava, MD

Assistant Professor of Surgery

West Virginia University: Charleston Division

Department of Surgery: Division of Vascular and Endovascular Surgery

VASCULAR SURGERY RULES OF ENGAGEMENT

1. When talking to families postoperatively, explain your biggest concerns about the case — no one likes surprises.
2. When you talk to patients, always do it sitting down.
3. If you do it perfect it might work.
4. Make claudicators beg for intervention.
5. Arterial access appears simple but can be deadly.
6. If you have not seen it done before, there is a reason why.
7. Amputation survival is equivalent to metastatic cancer.
8. Close the skin like it is your baby's face. Patients judge you more on the outside appearance than what you did on the inside.
9. If it can get infected, it will.
10. Statistics apply to everything — the numbers always catch up to you eventually.
11. If you don't like what it looks like today — you sure won't tomorrow.
12. When things are going bad, i.e. there's blood in the water, don't wait to see the sharks to call for help.
13. The first scary experience you will encounter: when you look across the table and realize you are the most experienced surgeon in the room.
14. If your stats are too good, just operate on a health care professional's family member.

And never forget that the devil made staples, pseudomonas, and some closure devices!

TABLE OF CONTENTS

Chapter	Page
1 History and Physical Examination — James R. Campbell	1
2 Commonly Prescribed Medications — James R. Campbell	7
3 Noninvasive Imaging — Patrick A. Stone	14
4 Endovascular BASICS — John E. Campbell and Patrick A. Stone	22
5 Radiation Safety — Mark C. Bates and Aravinda Nanjundappa	38
6 Endovascular Complications — John E. Campbell	43
7 Closure Devices and Their Complications — Aravinda Nanjundappa and Mark C. Bates	50
8 Aneurysm Disease — Patrick A. Stone	54
9 Peripheral Artery Occlusive Disease — Patrick A. Stone	76
10 Dialysis Access — Stephen M. Hass	94
11 Central Venous Access — Stephen M. Hass	104
12 Carotid Artery Occlusive Disease — Ali F. AbuRahma	109
13 Brachiocephalic Disease — Saadi Alhalbouni	116
14 Vascular Surgical Site Infection — Patrick A. Stone	121
15 Renal Artery Occlusive Disease — John E. Campbell and Mark C. Bates	124
16 Amputations — Patrick A. Stone	131
17 Mesenteric Ischemia — Patrick A. Stone	135
18 Thoracic Outlet Syndrome (TOS) — Mohit Srivastava	140
19 Venous Disease — Albeir Y. Mousa and Patrick A. Stone	147
20 Compartment Syndrome — Mohit Srivastava	159
21 Vascular Trauma — D. Daniel Dearing	164
Appendix 1 Contrast Allergy Pre-Procedure Protocol	176
Appendix 2 Outpatient Coumadin® (warfarin sodium) Order Set	177
Appendix 3 Reversing Excessive Warfarin-Associated AC	178

Refer to goremedical.com/combatmanual for key sources and studies.



CHAPTER 1

HISTORY AND PHYSICAL EXAMINATION

James R. Campbell II

INITIAL GLOBAL ASSESSMENT

Examination should begin as the patient enters the office:

Can the patient ambulate independently/on supplemental O₂/ appears fragile/or is morbidly obese?

This first initial assessment helps determine very quickly how invasive of a procedure the patient can tolerate in the event intervention is considered, i.e. does the patient look good and pass the sniff test?

HISTORY OF PRESENT ILLNESS

Always ask a patient why they have been referred, i.e. “What is their chief complaint?”

This clarification is important since physician referrals can be made for something entirely different than the patient’s actual chief complaint.

Where are symptoms and how long have they occurred?

What are the aggravating/alleviating factors?

To treat or not to treat is always based on the patient’s history.

REVIEW OF SYSTEMS/PAST MEDICAL/SURGICAL HISTORY

Cardiac-related morbidity is the # 1 cause of death following vascular interventions.

All previous surgeries must be known in detail, including non-vascular, so that appropriate pre-op can be performed.

Cardiac: MI, CHF, valvular disease, any previous coronary interventions including PTCA and/or CABG. This includes dates of procedures.

Procedural specifics: Drug-eluting stent requiring long-term clopidogrel and/or conduits used for coronary bypass procedures such as saphenous veins or radial arteries.



Pulmonary: COPD with or without home oxygen, lung mass, hx of pulmonary embolus, shortness of breath with exertion, cough.

Renal: Previous central venous catheters/dialysis access, and if so, at what locations. Known renal insuff: MAJOR cause of perioperative M&M. Know GFR: important for medication dosing.

Gastrointestinal: Mesenteric ischemia: weight loss, food fear, and/or postprandial abdominal pain. GI bleeding with previous aortic surgery — consider aorto-enteric fistula.

Infectious disease: Previous MRSA or other resistant bacterial infections.

Neurologic: Previous stroke? When: After 120 days most studies consider asymptomatic.

Hematologic: History of HIT, any bleeding (after dental procedures) or hypercoagulable disorders.

Urology: Hematuria, urethral stricture, or urinary retention.

Allergies, Social, and Family History

- **Allergies:** medications/contrast agents/list any intolerance to medications (intolerance does not equal allergy!).
- **Alcohol abuse:** CIWA protocol, and banana bag, etc.
- Classic occupational injuries: i.e. hypothenar hammer syndrome, etc.
- Medical power of attorney: who to call in case of change of condition.
- **Religious beliefs affecting medical care:** i.e. refuse blood transfusions, etc.

MEDICATIONS

All medications must be reviewed in detail. If patients do not know their medications, then pharmacies or primary care doctors must be contacted for verification. We will review medications in further detail in the next chapter.



PHYSICAL EXAMINATION

A full head-to-toe examination should be performed; however specific attention should be paid to the following areas:

Vitals

Head and neck: Carotid bruit ($\frac{1}{3}$ rule: $\frac{1}{3}$ normal, $\frac{1}{3}$ disease, $\frac{1}{3}$ severe disease), signs of previous neck irradiation, scars to identify previous neck surgery or central venous catheter placement, pulsation of carotid arteries, widened pulse — ? aneurysm, decreased pulse with proximal stenosis, or facial drooping. Remember that a bruit with a systolic and diastolic component is associated with severe carotid disease.

Cardiac: Murmurs? Valvular dysfunction — ECHO prior to general anesthesia.

Irregular pulse? Atrial fibrillation.

Distant heart sounds? Severe lung disease/pericardial effusion.

Lungs: Crackles, wheezes, or rhonchi? CHF or pneumonia.

Poor air movement — undiagnosed COPD.

Abdominal: Bruits, abdominal scars, pulsatile mass, and/or abdominal distension.

Lower extremity: Look, feel, listen. Prior to touching the patient many facts can be assessed:

Do the limbs look symmetric:

- **Venous disease:** Is one leg more swollen than the other?
Are there scars from previous vein harvest? Large varicosities?
- **Arterial:** Is one limb mottled or have pallor, while the other limb is normal?

Is there classic stigmata of chronic arterial or venous disease?

- **Venous:** Lipodermatosclerosis, and/or ulcers over gaiter region?
- **Arterial:** Hair loss, dependent rubor, digital ischemia with gangrene?

Touch the limb: Is it cool in comparison to the other limb, are there palpable pulses and good capillary refill? Document pulse examination. Pitting edema?



If no palpable pulses: Use a continuous wave doppler and listen. Categorize to multiphasic, monophasic, or absent. Venous signal should also be assessed (i.e. absent in stage III acute limb ischemia).

Upper extremity prior to dialysis access:

- **Ask patient which is the dominant arm:** All things equal, start with the nondominant arm.
- **Blood pressure in both arms:** It is unwise to use an extremity that has significant inflow disease defined by a 20 mmHg difference in blood pressure between the two arms.
- **Inspect chest wall:** Are there scars from previous access or chest wall collaterals? (i.e. Is there a suspicion for central vein stenosis or occlusion?)
- **Is there an AICD, pacemaker, or hx of previous catheters?** If so, perform a venogram if access is planned on the ipsilateral side. Follow Dialysis Outcome Quality Initiative (DOQI) guidelines.

LABORATORY EVALUATION

Prior to major operations:

- CBC — Is there anemia, thrombocytopenia, leukocytosis?
- BMP — Evaluates renal function, fluid status, metabolic state, and for hyperkalemia or hypokalemia.
- PT, aPTT, INR — In all patients, not just patients on anticoagulants. Patients can have undiagnosed liver disease or other syndromes that affect the coags.
- CXR — Routine assessment prior to open vascular procedures to rule out active pulmonary disease.
- EKG

CRITICAL PART OF PREOP CHECK LIST:

Imperative points needed to start a procedure (from central line on the floor to complex open intervention):

1. Prior to arriving in preoperative area
 - NPO after midnight
 - Bowel prep when indicated: abdominal procedures including clear liquids only the day before
 - Type and cross matched when indicated or type and screen
 - Cardiac clearance: when indicated



- Laboratory results reviewed:
 - Preg. test completed in all female patients of child-bearing age
 - Potassium levels should be normal prior to any endovascular/open cases
 - Creatinine level and eGFR: Hydration in patients with impaired renal function prior to contrast-based procedures
 - Premedication of patients with contrast allergies: Refer to appendix
 - Administration of cardioprotective medications: ASA, Beta blocker, statins prior to open surgery
2. Informed consent: The attending physician is responsible, however at times housestaff will be responsible that documentation is achieved on the chart, i.e. a signed consent form. The housestaff should ask if the patient has any questions that haven't been answered. The consent should be placed on chart and witnessed by nursing staff, not performed by nursing staff!!! Informed consent must include:
- Risks of intervention: Please refer to complication section of each chapter.
 - Alternates: Observation, endovascular or surgery.
 - Expected benefits: i.e. pad procedures: Walk further, alleviate rest pain, heal wounds, etc.
3. Mark and sign all required documents: Which includes the consent form, and correctly mark the surgical site, confirm with the patient the correct side!!!
4. Assure an updated history and physical is on the chart, and signed.
5. Common reasons surgery cancelled or delayed and residents blamed:
- Did not make patient NPO.
 - Did not check pregnancy test in female of child-bearing age.
 - Coags not checked or corrected.
 - BMP not checked and patient needs potassium level prior to starting procedure.
 - Dialysis not arranged and patient in dialysis instead of surgery: d/w nephrologist either dialyze a day early or after case... communication!!!
 - Cardiac clearance not done and cardiology will not clear until done, i.e. stress test.
 - Family not told patient going to surgery or time changed and patient wants to wait till family arrives.



CHECK LIST FOR POST OPERATIVE MANAGEMENT.

1. See the patient (evening after surgery).
2. Assure proper medications ordered. ASA beta blocker statins, antibiotics.
3. Make sure antibiotics stopped within 24 hours of surgery unless active infection and foley removed (NSQIP guidelines).
4. Check all cultures daily and narrow antibiotics when indicated.
5. Must check pulses and incisions daily for signs and symptoms of complications, i.e. hematoma, infections, etc.
6. Order and check labs pertinent to specific interventions, i.e. creatinine following contrast-based procedures.
7. Assess for development of surgery specific complications, i.e. neuro deficit, hematoma following CEA.
8. Update family of discharge planning, if none available then CALL.
9. Confirm plan for antiplatelet and or anticoagulation regimen: ASA/clopidogrel/Warfarin.
10. Signout with on call staff pending laboratory evaluations/tests-inform on call house staff if this/then what (transfusion triggers, etc.).



CHAPTER 2

COMMONLY PRESCRIBED MEDICATIONS

James R. Campbell II

ANTICOAGULANTS

Unfractionated Heparin: From ancient Greek (hepar: liver). Heparin is one of the oldest drugs currently still in widespread clinical use. Heparin is naturally occurring in mast cells. Discovered in 1916.

- **Indication:** Cardiovascular anticoagulation, deep venous thrombosis/PE.
- **Dosing:**
 - Bolus — 60–80 units/kg, depending on diagnosis
 - Infusion — 18 units/kg/hr., adjusted to keep a PTT of 50 to 80 sec
- **Mechanism of action:** mostly factor Xa
- **Half-life:** 1 to 1½ hours
- **Complications:** Major concerns are bleeding and heparin induced thrombocytopenia (HIT).

Low molecular weight heparin (LMWH): i.e. LOVENOX® (enoxaparin sodium injection). Factor X inhibitor. No monitoring of the PTT coagulation parameter.

- **Indications:** Cardiovascular anticoagulation, VTE prophylaxis and treatment.
- **Treatment dose:** 1 mg/kg subq q12 hours or 1 ½ mg/kg subq daily. Prophylaxis is 40 mg subQ daily, or 30 mg subq bid daily.
- Must be renal adjusted if creatinine clearance is less than 30. For dialysis patients LOVENOX® (enoxaparin sodium injection) has not been approved and is not recommended.
- Possibly poses a smaller risk of bleeding than unfractionated heparin.

This manual does not include all the information needed to use the drugs listed herein safely and effectively. See full prescribing information and any boxed warnings for these drugs.



- Less risk of osteoporosis in long-term use.
- Less risk of heparin-induced thrombocytopenia.

The anticoagulant effects of heparin are typically reversible with protamine sulfate, while the effect on LMWH is limited.

COUMADIN® (WARFARIN SODIUM)

It is a synthetic derivative of coumarin, a chemical found naturally in many plants — it decreases blood coagulation by interfering with vitamin K metabolism.

- **Indication:** Atrial fibrillation, DVT/PE, high risk vascular reconstructions.
- **Mechanism of action:** Inhibits the synthesis of vitamin K-dependent clotting factors: II, VII, IX and X, and proteins C and S.
- **Complications:** Bleeding, rash, osteoporosis.

PATIENT EDUCATION IMPERATIVE

- Discuss the influence of dietary vitamin K on INR.
- Discuss potential drug interactions (prescription, over-the-counter, herbal).
- Discuss the need to avoid or limit alcohol consumption.
- Explain need for birth control measures for women of childbearing age and document you did.
- Specify when to take warfarin and what to do if they miss a dose.
- Must notify patient's PCP that the patient is taking warfarin and make sure that appropriate follow-up is arranged for dose titration and INR testing.
- Warfarin should be started at a dose of 5 mg per day. Randomized trials have shown that patients are more likely to have a therapeutic INR three to five days after starting warfarin with a 5 mg dose than with a 10 mg dose.

Recommend a lower starting dose in:

- Elderly patients.
- Those with low body weight or low albumin levels.
- Patients with congestive heart failure or liver disease.
- Patients taking certain medications, e.g. amiodarone, trimethoprim-sulfamethoxazole, or metronidazole.

This manual does not include all the information needed to use the drugs listed herein safely and effectively. See full prescribing information and any boxed warnings for these drugs.



The initial increase in the INR (the anticoagulant effect) is primarily a response to decreased levels of circulating factor VII, which is the factor with the shortest half-life—approximately six hours. Factor IX also has a relatively short half-life.

However, the antithrombotic effect (the body's ability to prevent further thrombus formation) may not be achieved for up to five days. This effect depends on the clearance of circulating prothrombin, which has an elimination half-life of about 60 hours.

DIRECT THROMBIN INHIBITORS

Intravenous

Lepirudin: Hirudin derivative, indicated for heparin-induced thrombocytopenia with thrombosis. Renal excretion.

Argatroban: Indicated for heparin-induced thrombocytopenia with thrombosis. Metabolized by the liver.

ANGIOMAX® (bivalirudin): Hirudin derivative. Indicated for unstable angina or angioplasty.

- Commonly used in complex interventions for consistent anticoagulation rather than the peaks and troughs that are seen with heparin bolus.

Oral

PRADAXA® (dabigatran etexilate mesylate)

- **Indication:** Alternate to warfarin for atrial fibrillation.
- **Dosing:** 150 mg bid: renal dosing.
- **Mechanism of action:** Direct thrombin inhibitor.
- **Half-life:** 12–17 hours.
- **Reversing:** Activated charcoal to prevent residual drug in the stomach to be absorbed, consideration of one to two sessions of hemodialysis trying to get PRADAXA® (dabigatran etexilate mesylate) out of the blood system; recombinant factor VIIa (NOVOSEVEN® [coagulation factor VIIa (recombinant)]) intravenously; FFP does not appear effective.

This manual does not include all the information needed to use the drugs listed herein safely and effectively. See full prescribing information and any boxed warnings for these drugs.



ANTIPLATELETS

ASA

Indications: For primary and secondary prevention of cardiovascular events.

Dosing: 81 mg – 325 daily.

Mechanism of action: ASPIRIN® (acetylsalicylic acid) causes irreversible inhibition of cyclooxygenase-1 (COX-1), resulting in decreased synthesis of thromboxane A₂.

The peak effect of ASPIRIN® (acetylsalicylic acid) on platelets occurs quickly (within one hour). Platelets are non-functional for the rest of their life span (7–10 days).

Therefore, if no antiplatelet effect is desired, ASPIRIN® (acetylsalicylic acid) therapy should be discontinued 7–10 days prior to surgery.

Clopidogrel bisulfate

Indication: Acute coronary syndrome. Recent MI, Stroke or PAD. PLAVIX® (clopidogrel bisulfate) has been shown to reduce the rate of a combined endpoint of new ischemic stroke (fatal or not), new MI (fatal or not), and other vascular death.

Dosing: Loading dose 300–600 mg. Maintenance dose thereafter is 75 mg daily.

Mechanism of action: Irreversibly inhibits platelet activation through blockade of adenosine diphosphate (ADP) receptors found on platelets.

Concomitant PPI administration can reduce effect of drug, also patients who are poor metabolizers with CYP2C19 have higher coronary complications than normal metabolizers.

Dextran

Indication: Volume expander, following non-cardiac vascular surgery as IV antiplatelet agent.

Dosing: 20–25 ml/hour typically given for 24 hours.

Structure: Complex, branched glycan (polysaccharide made of many glucose molecules) composed of chains of varying lengths (from 10 to 150 kilodaltons).

This manual does not include all the information needed to use the drugs listed herein safely and effectively. See full prescribing information and any boxed warnings for these drugs.



Mechanism of Action: It has antiplatelet activity. Also there is an effect on primary and secondary hemostasis. It interferes erythrocyte aggregation and with fibrin polymerization. It decreases blood viscosity as well.

Frequently used following CEA and infrainguinal bypass. Caution in patients with CHF and renal failure. Severe anaphylaxis has been reported.

AGGRENOX® (aspirin/extended-release dipyridamole)

Indication: Secondary prevention of stroke (20% less likely to have secondary stroke than 50 mg bid ASA only).

Mechanism of Action: Thromboxane synthase inhibitor. Dipyridamole inhibits PDE in tissues and inhibits the uptake of adenosine into platelets and augments the increase in cGMP.

Half-life: 10 hours.

Dosing: (25 mg ASA/200 mg dipyridamole) bid.

Side effects: Headache, and GI complaints.

Thienopyridines¹: EFFIENT® (prasugrel)

Indication: Acute coronary syndrome.

Dosing: 60 mg loading and 10 mg daily. No dosing adjustments for renal impairment.

Mechanism of action: ADP inhibitor. Irreversible inhibition of platelet.

Complications: Increased risk of neurologic events in patients with history of TIA / stroke. TTP potential side effect.



CLAUDICATION AGENTS:

PLETAL® (cilostazol)

Indication: Medical management of claudication (studies report increase in walking distance from 25-100% of baseline).

Dosing: 50 or 100 mg bid.

Mechanism of action: Phosphodiesterase inhibitor, mild antiplatelet-reversible inhibition.

Complication: Contraindicated in CHF patients. Most common reason for drug cessation is gastrointestinal symptoms. The most effective medication to increase walking distances in patients with peripheral vascular disease.

COMMONLY PRESCRIBED ANTIBIOTICS

ANCEF® (cefazolin)—1st generation cephalosporin-Bactericidal

Indication: Preoperative prior to open vascular surgery.

Dosing: Wt based typically 1–2 grams given q 6–8 hours for up to 24 hours after operation. < 60 min prior to incision, in OR every 3–4 hours.

VANCOCIN® (vancomycin)—bactericidal

Indication:

1. Surgical prophylaxis in patients with PCN allergy.
2. Treatment of suspected or documented MRSA infection. Consider addition of gentamicin 4 mg/kg secondary to lack of gram neg. coverage with vanc. if needed.

Dosing: *Periop:* Wt based, second dose give if operation exceeds 6 hours.

Treatment dosing: Wt based with troughs checked after third dose.

*Serial BMP's-renal dysfunction not uncommon.



ZOSYN® (piperacillin/tazobactam)—Extended spectrum PCN (bactericidal)

Indication: Treatment of suspected or confirmed polymicrobial gram positive/negative infections.

Dosing: Wt based/renal clearance. Normal renal function: 3.375 g IV q 6 hours.

*Pseudomonas coverage, and anaerobe coverage. Once microbes specified then narrow coverage.

DIABETIC MEDICATIONS

GLUCOPHAGE® (metformin hydrochloride)

An oral medication in a class of drugs called biguanide. Does not cause hypoglycemia. Must be stopped 24 hours before any IV contrast and should be stopped prior to surgery secondary to risk for lactic acidosis. Can be reinitiated 48 hours post-operative if no acute kidney injury.

Sulfonylureas

Increases insulin production. Should be stopped 48 to 72 hours prior to surgery secondary to risk for hypoglycemia. Post-operatively these medications can cause hypoglycemia if initiated with poor caloric intake by patient. Should always be held in NPO patient!



CHAPTER 3

NONINVASIVE IMAGING

Patrick A. Stone

BASIC CONCEPTS

As vascular surgeons we love numbers and statistics. If you can only remember two numbers related to Doppler criteria, they would include the velocities **< 50 cm/sec** (seen with slow flow from either severe proximal stenosis or occlusion) and **> 300 cm/sec** (elevated velocities detected within or adjacent to a stenosis).

BASICS

Doppler Equation:
$$\text{Frequency} = \frac{2F_t V \cos \Theta}{C}$$

Frequency shift = 2 x frequency transmitted x velocity x cosign of beam angle/Speed of sound in tissue (1540 meters/sec).

Velocity criteria for vascular beds developed at 60 degree angle.

Frequency of probe: Inversely related to depth of beam penetration.

Continuous wave Doppler: Detects all velocities across vessel.

Pulse wave Doppler: Detects only sampled velocities.

Duplex:

B- Mode: Used to image soft tissue structures.

Pulse Doppler: Sample velocities at visualized location.



Carotid Artery

Routine components of vascular imaging include gray-scale and Doppler US interpretation of the ICA²:

Plaque characteristics: Heterogenous plaques are more likely to be symptomatic.

Differentiate ECA vs. ICA: ECA with branches and high resistance with minimal diastolic flow, whereas the ICA has low resistance.

Duplex Velocity Criteria for Native Carotid Artery³

PSV = Peak systolic velocity (cm/sec)

EDV = End diastolic velocity (cm/sec)

PRIMARY PARAMETERS		ADDITIONAL PARAMETERS		
ICA PSV	Stenosis Severity	ICA/CCA PSV ratio	ICA EDV	STENOSIS SEVERITY
< 125	none	< 2	< 40	normal
> 125	< 50%	< 2	< 40	< 50%
125–230	> 50%	2–4	40–100	"50–69"
> 230	> 50%	> 4	> 100	"> 70"

- The CCA typically has a combined waveform of the internal and external carotid artery. When the ICA is occluded, a more peripheral appearing waveform is seen in the CCA with little diastolic flow termed-externalization of CCA waveform. Also the absence of color flow or doppler signal in ICA are common findings.
- Low velocities in CCA < 50 cm/sec? Ostial carotid stenosis.
- Current criteria is for de-novo stenosis, there is no consensus for post CEA with patch or stenting. *Contralateral critical stenosis or occlusion generally falsely elevates PSV of the ipsilateral artery by 10–15%. Up to 25% of patients will be reclassified following CEA of the contralateral artery, therefore repeat imaging should be considered prior to contralateral endarterectomy.

Subclavian artery:

No defined criteria for subclavian artery stenosis.

Asymmetry in brachial blood pressures > 20 mmHg with reversal of blood flow in the vertebral arteries demonstrate anatomic subclavian steal.



Peripheral

An ankle brachial index (ABI) should be performed as an initial screening exam for peripheral arterial occlusive disease and as the AHA recommended examination following lower extremity revascularization procedures.

This is performed by using a hand-held continuous wave doppler probe and a manual sphygmomanometer. When the pulse is identified with the doppler probe at the ankle over the artery (dorsalis pedis or posterior tibial), inflate the cuff over the calf until the signal is lost. When the signal returns after slowly deflating the cuff, this number represents the examined tibial vessel's pressure. The procedure is repeated on the other tibial vessel as well as the other limb. The highest tibial pressure is used against the highest of the brachial blood pressures to calculate the ABI.

Ankle Brachial Index (ABI)

Best predictor of long-term limb loss and survival in patients with PAD.
 ≥ 1.3 signifies poor/noncompressible tibial arteries

0.9 to < 1.3 normal

< 0.9 to 0.7 mild PAD

< 0.7 to 0.4 moderate PAD

< 0.4 severe PAD

If the patient is diabetic and the arteries are non-compressible, i.e. pressure > 250 mmHg, then toe pressures are recommended as a baseline examination.

Toe Brachial Index (TBI)

Normal TBI > 0.75.

- Toe pressures > 50 mmHg in diabetic patient should permit healing of a digit amputation.
- Toe pressures < 30 mmHg unlikely to heal in either a diabetic or nondiabetic patient.

Segmental Pressures

Classic examination includes four cuffs: high thigh, low thigh, calf, and ankle. A 20 mm drop in blood pressure between two cuffs is considered significant. The high thigh should be at least the same as the brachial pressure, if less than brachial blood pressure, then consider inflow disease.



Peripheral arterial duplex:

Analysis of Lower Extremity Doppler Arterial Waveform Patterns

The Doppler arterial waveforms obtained from the lower extremity may be classified into categories as an aid in interpretation.

TYPE	TYPICAL WAVEFORM	FINDINGS
0		Triphasic
I		Biphasic
IV		Monophasic

Normal: Triphasic waveform.

Mild disease: Lose reversal of flow first, resulting in a biphasic waveform pattern.

Severe disease: Monophasic waveform appreciated.

> 200 cm/sec = 50%–75% stenosis and VR 2.0–3.4

> 300 cm/sec = > 75% stenosis and VR > 3.5

AAA

Recommended follow-up examination for AAA:

3.5–4.4 cm, annually

4.5–5.4 cm, every 6 months

≥ 5.5 cm, CT scan and offer repair



Renal

> 60% stenosis: PSV > 180 cm/sec and Renal Aortic (RAR) > 3.5

Other significant components on exam:

- > 1 cm difference in kidney length either of the same kidney on serial exams or in comparison to contralateral kidney.
- Renal Resistive Index(RI): > 0.7 indicative of parenchymal disease
- Normal kidney length: 9–12 cm

Mesenteric

Visceral imaging is obviously difficult to perform and visualize in obese patients or in patients who have not fasted⁴.

Celiac: PSV > 200 cm/sec = > 70% stenosis

EDV > 55 cm/sec > 50% stenosis

New criteria by our institution PSV > 320 cm/sec = 70% stenosis

Retrograde hepatic artery flow:

Specificity of nearly 100% for celiac artery stenosis/occlusion

SMA: PSV > 275 cm/sec = > 70% stenosis

New criteria by our institution > 400 cm/sec

EDV > 45 cm/sec — > 50% Stenosis

IMA: No accepted criteria.

Venous

Reflux: > 0.5 sec is consistent with significant reflux.

Retrograde flow while standing with valsalva maneuver.

Also assess for deep venous reflux and thrombosis.

Assessment of diameter of greater and lesser saphenous vein is helpful.

Identifying dual saphenous and poly-branched systems prior to intervention.



DVT

Acute: Non-compressible vein, limited or no color flow, faintly echogenic, homogenous in nature, no collaterals.

Chronic: Often has collaterals and is not dilated, has partial degree of occlusion, heterogeneous.

AV Access Mapping

Bilateral upper extremity BP: If > 20 mmHg difference, use extremity with better b.p.

Diameters of radial and brachial artery: If < 2 mm, not suitable.

Vein diameter ≥ 2.5 mm from planned access site. For example, if cephalic vein is 2.5 mm at wrist but at 1 mm mid-forearm, then inadequate.

Saphenous Vein Mapping Prior to Infrainguinal Reconstructions

Examination should include diameter from ankle to groin: > 3 mm ideal for segment to be used for bypass.

*If previously harvested for CABG then consider upper extremity mapping.

POST-INTERVENTION IMAGING

Carotid: Routinely we have performed carotid duplex examination within 30 days of intervention to document a new patient baseline. Subsequent imaging should be at 6 months and then again at 12 months, assuming no critical abnormalities are detected after interventions or in de novo lesions.

As a group we have continued to recommend surveillance at the following intervals:

$< 50\%$ stenosis with disease present 1–2 years. If B-mode: no disease and velocities less than 50% can evaluate prn.

> 50 to $< 70\%$ at 6 month–12 month intervals

$> 70\%$ recommend secondary imaging with possible repeat intervention



AAA

Following open repair: Ultrasound after five years to assess for development of anastomotic aneurysm which occurs in approximately 5% of repairs.

After EVAR: 30 days, 6 months, and then 12 months follow-up with CTA. If endoleak identified, then intervals may be shortened.

For patients with elevated creatinine, we usually use ultrasound instead of CT. In patients at one year and no leak, we often switch to ultrasound-based imaging and follow-up every 6–12 months.

PAD Procedures

Similarly, we closely follow vein bypass patients with 1 month, 6 month, and 12 month exams, but more frequently with abnormal findings, i.e. velocities over 200 cm/sec in the conduit.

When velocities exceed 300 cm/sec or ABI drops 0.15 then an angio should be performed to assess for critical vein graft stenosis.

After prosthetic bypass or endovascular intervention: ABIs should at least be followed at 1 month, 6 month, and 12 months, but some of our group follows these interventions similar to infrainguinal vein bypass protocol.

Following Ablation of GSV

The majority of vascular surgeons recommend follow-up imaging to assess for complete closure and assessment for postoperative DVT—duplex examination within 30 days of procedure. Thrombus extending from the SFJ into the common femoral vein can occur in up to 3% of patients, mostly in patients with large saphenous veins and history of DVT.

Following Mesenteric and Renal Interventions

In clinical trials, the protocol will dictate frequency and type of follow-up required. Most of our group has limited routine duplex follow-up and follow patients clinically (i.e. renal function and blood pressure monitoring). If symptoms recur, we recommend duplex imaging. But some still follow routinely at 1 month, 6 month, then annually.



My senior fellow would say we should get credit for cases that we obtain access, regardless of how much of the rest of the procedure the attending performs since, "they can't do the procedure unless we get access."

P. Armstrong, DO



CHAPTER 4

ENDOVASCULAR BASICS

John E. Campbell and Patrick A. Stone

ARTERIAL ACCESS

Most common: Retrograde Femoral Artery

- < 5% of cases are performed by antegrade puncture, brachial access, or radial access.
- Brachial artery complications at our institution are significantly higher than that of a femoral-based approach.
- The brachial artery is smaller, has less tolerance for hematoma, and is more likely to result in nerve-related complications.

Techniques to Obtain Access of the Femoral Artery

- Point of maximal pulsation: “where you feel it best, then stick it.”
- Fluoroscopic-guided puncture over mid-femoral head with or without Doppler needle assistance⁵.
- Ultrasound guidance — 5–10 MHz Linear transducer, transverse or longitudinal view for access. *Up to 20% of femoral bifurcations occur above femoral head.
- *Routine use* of ultrasound guidance include:
 1. EVAR when using the preclose technique.
 2. Antegrade or brachial sticks.
 3. Any cases that thrombolysis is entertained at the initiation of the procedure.

Key study: The FAUST trial⁶ of over 1,000 patients randomized to fluoroscopic vs. ultrasound guidance:

- No difference in common femoral artery cannulation rates with > 80% success in both groups, except in the subgroup where bifurcation was over the femoral head. More importantly there were less first-pass attempts, and reduced venipuncture and vascular complications in the ultrasound group.

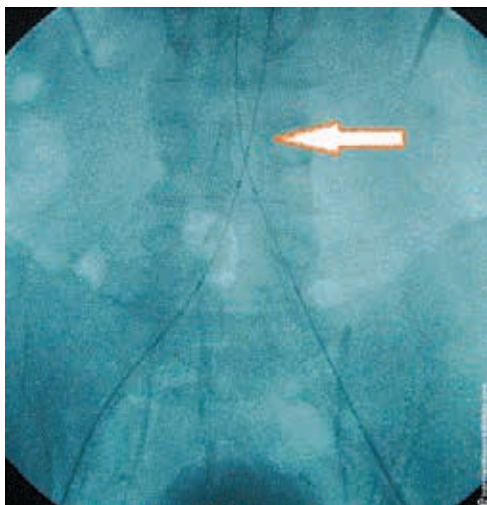


- A modified Seldinger technique is used to obtain access which consists of puncturing the artery, advancement of a guidewire into the aorta during access, and subsequent insertion of a sheath (usually 5 Fr). The introducer is then removed and a catheter is advanced over the wire to the desired location.

WIRE BASICS

Wires come in a variety of lengths, diameters, degree of support, coating, and design. Wires with a high degree of support are needed in tortuous vessels or if passing a large device such as a stent-graft. Hydrophilic-coated wires are useful in navigating tortuous anatomy or complex lesions but do have a high risk of perforation in visceral vessels. No two wires are the same and care should be taken in choosing each wire for each specific situation. A list of different wire characteristics is shown on the following page:

Wires Crossed in Distal Abdominal Aorta





- **Diameter:** .014", .018", .025", .035", .038", .064"
Monorail/rapid exchange requires .014" (usually used in renal, mesenteric, carotid , some tibial interventions).
- **Length:** Separated in regular or exchange length (≥ 260 cm).
Always consider if an exchange length wire is needed before crossing a difficult lesion.
- **Coating:** Silicone, hydrophilic, non-coated. Hydrophilic coating decreases the coefficient of friction making it easier to advance the wire through tortuous vessels.
- **Support:** Different degrees of support from little support (e.g. J-wire) to extreme support (e.g. LUNDERQUIST® Wire; COOK® Medical, Bloomington, IN).
- **Wire design:** Different wires have different transitions at the tip of the wire. This can range from a very short transition (e.g. GLIDEWIRE® Wire; Terumo, Somerset, NJ) with a nickel titanium core] to a very long transition (e.g. Balanced Middle Weight wire (Abbott Vascular, Redwood City, CA).

Frequently Used Wires

- **Bentson Wire (COOK® Medical, Bloomington, IN):** Design of outer coil wrapped around core, floppy distal tip, inexpensive. Often used as initial access wire. Caveat: may not have enough support for sheath advancement in obese patients or if scar tissue present from previous surgery. Also, risk of dissection secondary to poor feedback from coiled design, so wire should be advanced under fluoroscopic guidance.
- **SUPRACORE® Wire (Abbott Vascular, Redwood City, CA):** 17 cm tapered core, moderate support, and stainless steel shaft. Has "soft tip" with the transition of the distal segment of the wire providing good "feedback" during wire advancement.
- **AMPLATZ Wire (Boston Scientific, Natick, MA):** Good support, useful for passage of large devices, or in tortuous anatomy.
- **LUNDERQUIST® Wire (COOK® Medical, Bloomington, IN):** Extremely high support, (referred to as a coat hanger by some) for Endo AAA/TAA.



- **GLIDEWIRE® Wire (Terumo, Somerset NJ):** Super-elastic core gives 1:1 torque ratio. Hydrophilic coating useful to navigate through stenosis and tortuosity as well as through CTOs. However, there is a risk of perforation of small branch arteries, especially when used in visceral vessels.
- **J Wire:** Inexpensive low support wire with “J” shape to avoid cannulation of side branches with access. Not ideal for access secondary to low support and poor tip feedback. Is one of the most common wires used for access secondary to being inexpensive.

CATHETER DEFINITIONS AND BASICS

- French (Fr) = 0.33 mm
- OD = outer diameter of catheter
- ID = inner diameter of catheter
- French size $\div 3$ = approximate catheter diameter in mm
- Sheath’s diameter is defined by the ID
- Catheters/guide catheters are defined by their OD
 - Note: a 5 Fr catheter can pass through a 5 Fr sheath

Frequently Used Catheters

- **Flush catheters:** Pigtail, Tennis Racket, Universal Flush
- **Selective catheters:** Passive, Intermediate, Active
 - **Passive** — (e.g. Berenstein, multipurpose, vertebral, etc.)
 - **Intermediate** — (e.g. Vitek, Mani, etc.)
 - **Active** — (e.g. SIMMONS SIDEWINDER Catheter, Newton, etc.) Active catheters must be formed and this is usually done in the aortic arch using the left subclavian artery. These catheters need to be used carefully and formed correctly. Given the “energy” stored in the tip of the catheter it can “dig” into plaque more easily than passive or intermediate catheters and cause atheroembolism (i.e. stroke). Only use when necessary!
- **Guide catheters:** Used primarily for renal and mesenteric interventions, however can be used for carotid stenting as well as intervention for infrapopliteal disease. The Bates 1 and 2 guides are used for over 70% of the renal interventions at our institution. The IMA guide is also used often and on difficult renal cannulations (severe caudal angulation or a tortuous renal artery) an 8 Fr Cobra guide catheter or MORPH® Vascular Access Catheter can be used (Bio Cardio, San Carlos, CA).



- **Micro catheters:** Can be used for superselective imaging and for embolization procedures.

SHEATHS

- Sheaths can be guiding sheaths or introducer sheaths. Guiding sheaths are usually braided for extra support and can be used for carotid intervention or contralateral access for lower extremity arterial intervention. A short introducer sheath (10 cm) is used for basic access for diagnostic angiography or for renal or visceral intervention (guide is advanced through sheath). Remember that an obese patient may need a longer sheath to maintain access. There are short introducer sheaths (6 cm) available that are ideal for AV graft declots or for fistulograms.
- **Remember that once sheath size is ≥ 8 Fr for femoral artery access, complication risk increases. In the brachial artery great caution should be used if the sheath size is greater than 6 Fr.
- Just because two different sheaths have the same ID does not mean they have the same OD. Sheaths are measured by ID and the OD differs depending on the type of sheath used.

ENDOVASCULAR THERAPY

Forefathers of Endovascular Therapy

- Werner Forssmann — Performed the first heart catheterization in 1929.
- Charles Dotter — Performed first angioplasty in 1964.
- Andreas Gruentzig — Performed first coronary angioplasty in 1977.
- Julio Palmaz — Invented the balloon-expandable stent.

BALLOON ANGIOPLASTY

Definitions

- Rated burst pressure — the pressure at which 99.9% of balloons will not rupture with 95% confidence.
- Nominal pressure — the pressure at which the balloon reaches its labeled diameter.



Characteristics of Balloon Catheters

- **Compliance** — Defined as the unit of volume change per unit of pressure change.
 - Compliant — used as an aortic occlusion balloon or to “mold” stent-graft.
 - Semi-compliant — balloon catheter used for most interventions.
 - Non-compliant — No appreciable change in diameter once nominal pressure reached even with high pressures.
- **Delivery system**
 - “Over-the-wire” system — designed so that the wire enters the tip of the catheter and exits the end of the catheter.
 - Advantage — Excellent pushability.
 - Disadvantage — More potential for movement of wire during removal of the balloon (must “walk off” the entire balloon).
 - Monorail (rapid exchange) — Designed so that the wire enters the tip of the balloon catheter, but exits in the proximal segment out of a side port. The remainder of the catheter after the side port has only one lumen that allows delivery of contrast to the balloon.
 - Advantages — Quicker exchanges, less potential for loss of wire during exchanges since only the distal segment needs “walked off.”
 - Disadvantage — Less pushability than “over-the-wire.”

STENTS

- ***Designed to treat failures of angioplasty:*** Flow limiting dissections, significant recoil resulting in residual stenosis > 30%. However, with maturation of technology, they are now used for primary stenting in several vascular beds.

There are two classifications of stents:

- **Balloon-expandable** — Stent is mounted on the balloon and expanded with initial dilation of balloon. In the past it was typically stainless steel, however new designs are utilizing cobalt chromium. High radial force and accurate placement that is ideal for calcified ostial lesions.
- **Self-expanding** — Composed of nitinol (except the WALLSTENT® Endoprosthesis which is composed of elgiloy). Ideal for tortuous vessels or areas where there is inherent motion of the artery. Key properties of nitinol are both superelasticity and shape memory. Less accurate deployment than balloon-expandable and less radial force, however must be used in areas of motion since balloon expandable stents will have permanent deformation once a critical external force is exceeded.



- **Key points to understand:**
 - Sizing of balloon-expandable and self-expanding stents are different:
 - Balloon-expandable stent sized 1:1 to vessel
 - Self-expanding stent is slightly oversized (~10–15%)
 - Both can have open or closed cell design:
 - Open cell design is more flexible
 - Closed cell design is less flexible but generally less risk of plaque protrusion
- **Covered stents:** Both balloon-expandable and self-expanding stents can be covered.
 - There are several covered self-expanding stents but three are most commonly used:
 - **GORE® VIABAHN® Endoprosthesis (W. L. Gore & Associates, Inc., Flagstaff, AZ):** Diameter: 5–13 mm, Length: 2.5–15 cm, Catheter length: 75/120 cm, Device Profile: 6–12 Fr. ePTFE covered stent-graft that is FDA approved for the SFA and iliac artery.
 - **FLUENCY® Stent Graft (Bard Peripheral Vascular, Inc., Tempe, AZ):** Diameter: 6–10 mm, Length: 40–80 mm, Delivery System Length: 80/117 cm, Device Profile: 8, 9 Fr. ePTFE covered self-expanding stent that is not as flexible as the GORE® VIABAHN® Endoprosthesis. Most commonly used off-label to treat venous stenosis in AV grafts and AV fistulas.
 - **FLAIR® Device (Bard Peripheral Vascular, Inc., Tempe, AZ):** Diameter: 6–9 mm (the flared distal stent graft end diameter is approx. 4 mm larger than the labeled diameter), Length: 30–50 mm, Delivery System Working Length: 80 cm, Device Profile: 9 Fr.
 - ePTFE covered self-expanding stent that is FDA approved for treatment of venous anastomosis stenosis of AV grafts.
 - The most commonly used PTFE-covered balloon-expandable stent is the ICAST Stent (Atrium, Hudson, NH). Diameter: 5–10 mm, Length: 16–59 mm, Catheter length: 80/120 cm, Device Profile: 6, 7 Fr.
 - Used for treatment of Iliac artery stenosis, but our center has used the ICAST Stent commonly for in-stent restenosis of Iliac, renal, and mesenteric arteries. Can also be used for treatment of perforation of arteries or with fenestrated stent-grafts.
- **Drug-eluting balloon expandable stents:**
 - Balloon-expandable coronary stents — used off-label for the treatment of restenosis of renal artery stents and in the treatment of infrapopliteal disease.



- Self-expanding stents — Encouraging data for ZILVER® PTX® Device, (COOK® Medical, Bloomington, IN) currently the only drug-eluting self-expanding stent indicated for SFA and above-knee popliteal artery.
- **Atherectomy:** Rather than displace plaque with angioplasty or stents, atherectomy removes the plaque from the artery.
 - It has been our center's experience to use atherectomy cautiously. Distal embolization can occur with all available devices and off-label use of embolic protection devices are usually used at our institution with atherectomy procedures.

CATHETER-DIRECTED THROMBOLYSIS

- Patients with acute symptoms < 14 days have improved outcomes when catheter-directed thrombolysis is used, however if symptoms persist > 14 days, then open surgery is preferred. No difference in safety or efficacy between rt-PA and UK.
- Indications for catheter-directed thrombolysis:
 1. Paget-Schroetter syndrome.
 2. Iliofemoral DVT.
 3. Acute limb ischemia with symptoms < 14 days.
 4. Thrombosed popliteal artery aneurysm if acute limb ischemia is in stage 1 or 2a.

Contraindication Checklist⁷:

Absolute

1. Established cerebrovascular event (including transient ischemic attacks within last 2 mo)
2. Active bleeding diathesis
3. Recent gastrointestinal bleeding (<10 d)
4. Neurosurgery (intracranial, spinal) within last 3 mo
5. Intracranial trauma within last 3 mo

Relative major

1. Cardiopulmonary resuscitation within last 10 d
2. Major nonvascular surgery or trauma within last 10 d
3. Uncontrolled hypertension: >180 mm Hg systolic or >110 mm Hg diastolic
4. Puncture of noncompressible vessel
5. Intracranial tumor
6. Recent eye surgery

This manual does not include all the information needed to use the drugs listed herein safely and effectively. See full prescribing information and any boxed warnings for these drugs.



Minor

1. Hepatic failure, particularly those with coagulopathy
2. Bacterial endocarditis
3. Pregnancy
4. Diabetic hemorrhagic retinopathy

Post-Procedural Checklist:

- Run low dose heparin through access sheath to prevent sheath thrombosis and propagation of clot (300-500 units/hr).
- Postoperatively check PTT and fibrinogen levels every six hours and daily BMP.
- Will have dark urine (blood tinged) often secondary to lysis of RBCs if after rheolytic thrombectomy. The patient needs to be kept well-hydrated.
- Fibrinogen < 150 mg/dl then TPA should be held or dosage decreased.
 - < 100 mg/dl infusion stopped

Complications⁸:

- Intracranial hemorrhage: (2%)
- Major bleeding requiring transfusion or surgery: (10%)
- Compartment syndrome: (4%)
- Distal embolization: (5%)

Key References

Trials addressing arterial thrombolysis:

- STILE Trial⁹
- TOPAS Trial¹⁰

INTRAVASCULAR ULTRASOUND (IVUS)

- 8 Fr — Used for device for thoracic and abdominal aortic cases.
- 5, 6 Fr — The .014" and .018" IVUS catheters have improved resolution over the 8 Fr system but have a smaller field of view (.014" — 20 mm, .018" — 24 mm).
- **Important tip:** With venous disease such as May-Thurner syndrome, IVUS is essential to determine size of stent needed, as well as to visualize the external compression.



Pearls on IVUS

- Use in AAA cases when limited contrast is desired.
- Can use as sole imaging modality for IVC filter placement.
- Imperative in endovascular treatment of dissection.
- Used in conjunction with reentry device to find true lumen: PIONEER® Catheter (*Medtronic, Minneapolis, MN*).
- In cases of infrainguinal vein bypass, can help evaluate for retained valve.

EXPECTED PROGRESSION OF SKILLS FOR VASCULAR FELLOWS

First-Year Fellow

- Basics of radiation safety.
- Arterial and venous access, including use of closure devices.
- Venography and IVC filter placement.
- Arterial nonselective and selective angiography, including diagnostic carotid and cerebral angiography.
- Dialysis access interventions, including percutaneous thrombectomies.
- EVAR basics.

Second-Year Fellow

- Visceral and renal interventions.
- Complex infrainguinal interventions: CTO, and tibial interventions.
- Thoracic stent grafting.
- Carotid stenting.
- Complex embolizations such as GI and pelvic trauma.

First and Second-Year Fellow

It is important to have a good understanding of the basics of catheter and wire skills before progressing to more complex procedures. Although the first month of a vascular fellowship may have the resident participating in a carotid stent procedure, the progression of catheter skills is not adequate for a beginner to be able to perform the procedure. There is experience to be gained by scrubbing in on these procedures even early on. Although there are no written recommendations regarding progression of autonomy during endovascular procedures, this serves as a guide during your training.



DESCRIPTION OF INDIVIDUAL ENDOVASCULAR PROCEDURES

- **Safely obtaining access** — refer to previous section:
 - You can't move to any other part of the procedure without completing this step safely.
- **IVC filter placement:** The placement of an IVC filter is one of the most basic procedures performed by vascular surgeons. We choose the femoral vein for access with ultrasound interrogation in the majority of cases and then advance a sheath after serial dilations into the proximal ipsilateral iliac vein for venography. Assessment for IVC diameter, presence of thrombus and level of renal veins is routinely performed. The filter is then advanced in its sheath to just below the renal veins and the sheath is withdrawn with release of the IVC filter.
- **Abdominal flush angiography and lower extremity runoff:** After access is obtained, the pigtail is advanced into the abdominal aorta. The wire is withdrawn and the shape of the catheter is allowed to be formed. The pigtail should always be spun to make sure that the tip is not in a side branch before power injection is performed. If no aortic pathology is expected and a lower extremity runoff is planned, the pigtail should be placed 2–3 cm above the level of the aortic bifurcation so that contrast is not “lost” to the renal arteries. The flow rate is generally 7–8 ml/sec for a total of 10–12 sec depending on the size of the aorta and speed of the table performing steps.
- **Contralateral lower extremity angiography:** Several different catheters can be used to go up and over the aortic bifurcation (OMNI FLUSH Catheter, IM, RIM, etc.). The most common catheter used in our practice is the OMNI FLUSH Catheter. Technique involves allowing the catheter to form in the distal aorta, then advancing the wire 1–2 cm from the tip and pulling the catheter down with the wire entering the contralateral iliac. The catheter is then “engaged” on the bifurcation and the wire is advanced to the contralateral common femoral artery (CFA). The catheter is then advanced down to the distal external iliac artery (EIA) or CFA over the wire. If the patient has a challenging aortic bifurcation secondary to it being high/steep or iliac tortuosity, then the OMNI FLUSH Catheter can be removed leaving the hydrophilic wire in the contralateral lower extremity (at times wire may need to be advanced deep into the SFA or carefully into the profunda femoris) and a GLIDECATH® Catheter (Terumo, Somerset NJ) can then be advanced over the bifurcation to the CFA.



- ***Treatment of stenotic arteriovenous fistula:*** Access with a micropuncture kit with puncture a few centimeters distal to arterial anastomosis with the micropuncture introducer left in place. We prefer the micropuncture 4 Fr introducer for the initial imaging since 10–20% will not require treatment but are solely diagnostic. Check initial pressure and then a compressed outflow pressure. If intervention is needed, then a sheath will need to be placed and once intervention is complete, pressures should be rechecked to determine if intervention had a successful hemodynamic impact.
- ***Treatment of iliac artery stenosis by a retrograde access:*** This requires crossing a lesion with a steerable wire, then exchanging it for a working wire (high support wire). When placing balloon-expandable stents, the lesion should be crossed with a long introducer sheath so that the stent does not become dislodged from the balloon during advancement. The sheath is withdrawn after the stent is positioned in the desired location. This allows for no predilation and the lesion can be primarily stented. If there is concern for plaque shift at the ostium then at times “kissing iliac stents” can be placed raising the bifurcation 1 to 3 mm.

Important:

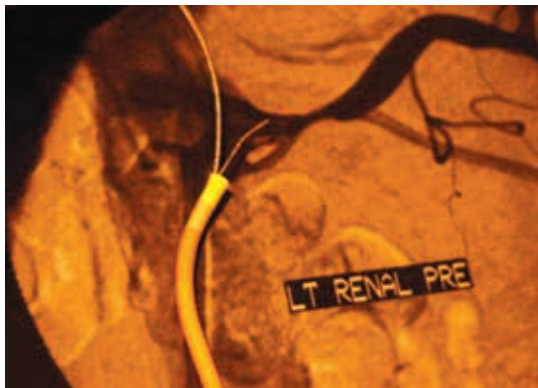
- The bifurcation should not be raised unless necessary and if raising the bifurcation is necessary then no more than 1–3 mm.
- Always perform completion angiogram of the infrapopliteal vessels after treatment of an iliac occlusion secondary to the risk of distal ipsilateral embolization (up to 5%).
- ***Treatment of Iliac or infrainguinal arterial stenosis by a contralateral approach:*** Guiding sheath is advanced over the aortic bifurcation to the CFA. Traditionally, most interventions on the SFA were performed with a .035" system, however, new stent platforms are deployed over a .018" system (e.g. GORE® VIABAHN® Endoprosthesis; W. L. Gore & Associates, Inc., Flagstaff, AZ).
- When performing infrapopliteal interventions, it is important when possible to have a guide catheter or guide sheath positioned with the tip in the popliteal segment for extra support. Most infrapopliteal interventions are performed with a .014" or .018" system.



- **Treatment of thrombosed arteriovenous graft:** The first step of the procedure should be to read the old operative reports to discover which limb is the venous and which is the arterial limb of the graft. If this is not available, always perform a diagnostic angiogram to confirm if the catheter is in the artery or vein. Access needs to be obtained in both limbs and generally a 6 Fr sheath is needed to treat the arterial anastomosis and a 7 Fr sheath for the venous outflow. The sheaths are pointed toward each other with the wires overlapped in between. Once access is obtained, then rheolytic thrombectomy is performed followed by removal of the arterial plug at the arterial anastomosis with a fogarty catheter (an over-the-wire fogarty can be used.) Angiogram is then performed of the graft, venous outflow, and arterial anastomosis. At this point angioplasty, and if needed for recoil, stenting, can be performed.

Important:

- Angiogram of the arterial anastomosis should be performed by placing a catheter proximal to the anastomosis in the feeding artery with visualization of the distal artery branches as well as the arterial anastomosis. Never compress the venous outflow and perform retrograde angiogram secondary to the risk of residual thrombus embolizing to the arterial outflow.
- **Renal interventions:** These interventions are more advanced and the skill set needed is more demanding. Most stents are placed in the ostium given that atherosclerosis of both the renal and visceral arteries is aortostial in most patients. Exact placement is necessary and the stent should extend no more than 3 mm into the aorta secondary to the difficulty in accessing the stent for subsequent procedures. Also there is inherent risk of a future interventionalist “trashing” the stent during coronary intervention when advancing a guide catheter as well.



Renal Artery Stenting No-touch Technique

There are two techniques which should be used for renal artery stenting:

- *No-touch technique:* This was championed by Mark C. Bates, MD at our institution as well as nationally, and is our preferred method. We have a strong belief that there is a high potential for occult atheroembolism by guide catheter manipulation if performed without this technique — with the potential for worsening chronic kidney disease.
 - The technique is usually performed with a 6 Fr system and using the guide of choice for the interventionalist (at our institution this is usually a Bates 1 or 2 guide).
 - The guide is advanced over a moderate support wire using a wire with a good transition at the distal segment (i.e. SUPRACORE® Wire; Abbott Vascular, Redwood City, CA). Next a .014" wire (i.e. SPARTACORE® Wire; Abbott Vascular, Redwood City, CA) with both a short transition at the distal segment and high degree of support is advanced to the distal segment of the guide catheter
 - Next the .035" wire is withdrawn to let the guide catheter take shape, however at least 3 cm of wire should still be left extending into the aorta to keep guide tip from scraping the wall of the aorta and potentially causing atheroembolism.
 - Next the .014" wire is advanced into the renal artery, and the .035" wire is removed. At this point the guide should fall into place at the ostium and PTA/stenting can be performed.
- *Telescoping technique:* This technique can be used to treat de novo renal artery stenosis but is especially useful for renal artery in-stent stenosis since it will prevent the wire from advancing through



a stent strut in the aorta. Again, most of the time this can be performed with a 6 Fr system. A diagnostic catheter (JR4, IM, etc.) is advanced through the guide of choice and secured with the tuohy borst. The renal artery is selected and the .014" wire is advanced into the renal artery. The guide is then advanced over the diagnostic catheter to the ostium of the renal artery. The diagnostic catheter is then "walked off" the wire while leaving the guide in place. At this point the operator can proceed with PTA/stenting.

- *Tip:* In highly tortuous renal arteries a MORPH® guide catheter (Bio Cardia; San Carlos, CA) can be used for added support. Also, when necessary, a brachial approach can be helpful for renal arteries with a high degree of inferior angulation.
- **Visceral interventions:** Performed just like renal artery interventions except that, secondary to tortuosity, and especially with the inferior angulation of the SMA, usually an 8 Fr system is needed for added support. Again, if needed, a brachial approach can be used.
- **Brachiocephalic interventions:** Ostial great vessel interventions are not common but occasionally do need to be performed. If stenting is needed, then a balloon-expandable stent is preferred. Subclavian stenting can usually be performed with a 90 cm sheath via a .035" system from a CFA approach. At times a brachial artery approach is needed, especially with subclavian artery occlusions. Both innominate and ostial carotid intervention can be difficult and often should be performed with the use of an embolic protection device. Techniques include the use of a guide catheter or guiding sheath from a CFA approach. For type 3 arches and at the time of concomitant carotid surgery (consider retrograde stenting). Again, these are technically demanding interventions from a femoral approach with potential for misplacement of stents extending too far into the thoracic aorta, and should only have hands-on involvement by residents with a high degree of comfortability in the endovascular suite.



- **Carotid artery angiography and stenting**
 - **Carotid angiography:** This is usually done with a 5 Fr system. When possible, aortic arch flush angiography should be performed first to assess the type of aortic arch (Type 1, 2, and 3) and amount of atherosclerosis present (i.e. “hostile arch”). When possible, a passive catheter should be used and typically angiograms can be performed with an angle GLIDECATH® Catheter and GLIDEWIRE® Catheter (Terumo, Somerset, NJ) alone for cannulation. Never let the tip of the wire extend out of the field of view, and when attempting to advance the catheter into the carotid artery all attempts should be made to keep the wire in the common carotid artery. Even when performing cerebral angiography and the preferred placement of the catheter is in the internal carotid artery, the wire is not advanced until adequate imaging of the internal carotid artery is performed to rule out disease. Only use active catheters (i.e. SIMMONS SIDEWINDER Catheter) when absolutely necessary.
 - **Carotid stenting:** Although a carotid stent may at times not be as hard technically as a renal or mesenteric stent, the complications are highly debilitating (i.e. stroke) for the patient. As already stressed above, always know the arch dynamics before attempting a carotid artery stenting procedure. Both an anchoring technique and telescoping technique can be used. The anchoring technique involves advancing a support wire into the external carotid artery and then advancing a guiding sheath into the common carotid artery. The telescoping technique is usually reserved for lesions that involve the common carotid artery (preventing safe passage of the wire into the external carotid artery) or if the external carotid artery is occluded. After the sheath is placed, then the lesion is carefully crossed (road mapping can be useful) and an embolic protection device (EPD) can be deployed in the distal internal carotid artery (when using a flow preservation EPD). Proximal protection devices can also be used and the lesion is not crossed until protection is in place. At this point the operator can proceed with stenting.



CHAPTER 5

RADIATION SAFETY

Mark C. Bates and Aravinda Nanjundappa

BACKGROUND

The average environmental exposure of radiation in the US is 3.1 millisieverts (mSv) each year. This exposure has recently been matched by diagnostic and therapeutic imaging and medical exposure has eclipsed industrial/occupational exposure risks. Patient, staff and physician exposure to radiation is of increasing concern as well in the era of complex fluoroscopic guided intervention, high-resolution three dimensional CT imaging and new PET and nuclear imaging algorithms. Radiation safety responsibility is shared by the endovascular laboratory personnel and radiation monitoring specialists but the primary owner of radiation risk management is the physician operator. Radiation exposure for peripheral vascular disease procedures is increased exponentially with new developments in the field and the goal of this chapter is to address the basics of radiation safety and steps to reduce the radiation exposure for the patient and interventional team.

PRINCIPLES OF RADIATION

X-rays are generated from a rotating anode that is being bombarded by a stream of electrons being driven from the cathode under a high potential difference (between 50 to 150 kilovolts.) X-rays are like any other kind of electromagnetic energy but are packaged in parcels called photons at a specific wavelength. The X-rays leave the X-ray tube (generator) and are directed toward the image intensifier (II) where they are collected and transmitted to the digital analyzer to be seen as images. The highest dose of radiation occurs between the generator and image intensifier, thus the patient receives much of the dose but scatter occurs and impacts all those around the procedure.



Thus, the operator must have a detailed understanding of X-ray physics before stepping on the fluoroscopy pedal to protect not only the patient but also his or her team.

The ALARA (As Low As Reasonably Achievable) guidelines stress the need to develop a strategy to keep patient and staff radiation exposure as low as possible. Skin exposure of the patient is the greatest. Radiation exposure is the greatest to the operator if he or she stands close to the X-ray generator. The radiation dose is exponentially reduced as the operator steps away from the generator. The X-ray beam is attenuated by the inverse square law ($1/d^2$) from the X-ray tube. To better understand this law, note that if one steps 5 feet from the table they will receive $< 1/25$ th the dose of one standing at 1 foot. The two views that have the highest radiation exposure to the physician are left anterior oblique with cranial angulations and left lateral view. The procedures with the highest radiation exposure are usually stent grafting and critical limb ischemia. Radiation effects can be estimated based on a single exposure but the effect is cumulative so serial procedures must be considered as additive.

STEPS TO REDUCE RADIATION EXPOSURE

1. It is the operator's responsibility to scan the room and make certain all staff has the appropriate radiation protection BEFORE stepping on the fluoroscopy pedal. Front-line physicians, nurses, and technicians within 4 feet of the image intensifier for prolonged periods of time should have .50 lead equivalence and preferred wrap around two-piece lead with a thyroid collar and lead glasses. Those distant from the image intensifier (II) could use lower lead equivalence. In addition one-piece aprons should be discouraged for anyone who may be circulating close to the image intensifier (II).
2. Most contemporary generators have a spacer to avoid placing the source too close to the patient. However, note that the closer the generator is to the patient's skin, then the higher skin dose they will get and this is the zone most at risk for skin radiation injury.
3. Whenever possible use radiation shield pads, a radiation shield door, lead skirt in front of the X-ray tube generator and a ceiling suspended lead glass shield to reduce patient/table scatter and team exposure.



4. Use fluoroscopy more than Cine as Cine utilizes 10 to 20 times more radiation than fluoroscopy.
5. Use pulse dose fluoroscopy instead of continuous fluoroscopy when possible.
6. Use collimation to reduce radiation scatter.
7. Radiation is only produced when the beam is on, so irradiate only when it is necessary to observe motion. Last-image-hold and instant replay are important tools to reduce dose.
8. Keep the X-ray source (X-ray tube) as far away from the team as possible consistent with optimal imaging.
9. Keep the distance between the patient and the X-ray generator close and keep the image intensifier as close to the patient as possible. However, understand that the patient will receive higher doses with the X-ray generator close and that operator and patient safety does need to be balanced.
10. Use the least amount of magnification consistent with seeing the target vessel adequately.
11. Try not to extend the fluoroscopy time beyond 60 minutes. After one hour of fluoroscopy, exposure hazards of radiation such as skin ulceration/necrosis increase. Most centers require notification of the radiation safety officer when fluoro-time exceeds 60 minutes. Note that skin ulceration may not show up for weeks or months and you must educate the patient about what to look for and ensure follow-up. You should also explain to the patient and document which area is at highest risk for dermal injury based on the skin closest to the generator.
12. Use the inverse square law to your advantage and whenever possible move away from the X-ray source before activating the generator.
13. Wear a radiation badge as it is for your own benefit. The readings should correlate with your workload. Place the badge over-lead and monitor on midline at neck level as well as under-lead and monitor on midline at waist level.
14. De-clotting of AV grafts and AV fistula can result in exposure of hands to radiation and could result in radiation burn to the operator if the operator's hands are placed repeatedly in the beam.



EFFECTS OF RADIATION

Two main effects are stochastic and non-stochastic/deterministic.

- **Stochastic effects:** Here probability is proportional to dose. Severity independent of dose and assume zero thresholds. The risks are radiogenic cancer and genetic damage.
- **Deterministic effects:** Certainty of effect and severity is a function of dose. It does have a substantial threshold. High dose risks are: hair loss, skin damage, cataracts, and congenital abnormalities.

Acute risk is primarily limited to the skin exposure but this can be devastating. One minute of fluoroscopy is equal to 250 CXRs and larger patients result in greater exposure to both patient and operator. Depending on patient weight, technique (collimation, magnification, image angle, distance from generator) and efficiency of equipment (improved with contemporary digital systems), early dermal injury like erythema and temporary epilation can be expected to begin from 45 minutes to 150 minutes of fluoroscopy exposure and skin necrosis after 2 hours.

IN CONCLUSION

Remember to follow these few steps to reduce radiation:

- **Time:** Short exposure to radiation.
- **Distance (inverse square law):** Stay far away from X-ray generator.
- **Shielding:** Shields, apron lead, thyroid shield and lead eye glasses.
- **Contamination control:** Collimation and keep the source to image distance minimum.



“If a patient is going to die from a procedure-related complication, it will most likely be secondary to access.”

“I never saw an access-related amputation until the advent of closure devices.”

Mark Bates, MD



CHAPTER 6

ENDOVASCULAR COMPLICATIONS

John E. Campbell

ACCESS COMPLICATIONS

Access complications are the most common complication of any endovascular procedure. Different patients and different procedures have a different risk of access complication. The American Heart Association divided the risk of complications into three patient groups for cardiovascular procedures¹¹.

1. **Low-risk procedures (< 1% complication rate):** These include diagnostic angiograms generally using 4 or 5 Fr sheaths, shorter length procedures, and procedures that use little concomitant anticoagulation. Low-risk patient characteristics include men sex, younger age, normal renal function, and increased body size.
2. **Moderate-risk procedures (1 to 3% complication rate):** These include routine percutaneous intervention and include procedures that have sheath sizes of 6 to 7 Fr, increased procedure time compared to a diagnostic procedure, and involve the use of adjunctive anticoagulants and antithrombotic regimens. Moderate-risk patient characteristics include older patients, more often female, and may have evidence of renal dysfunction.
3. **High-risk procedures (> 3% complication rate):** These include, but are not limited to patients with peripheral arterial disease, advanced age, female sex, liver disease, coagulopathy, immunosuppression, previous valve replacement, and renal dysfunction. Procedures that require a sheath size \geq 8 Fr are also at high risk for access site complications.



List of Access Complications

- **Groin hematoma (occurs in 1–3% of patients, reported much higher in some series):** Can be caused by puncture of the artery below the femoral head, which is used for support during manual compression. Also, a sheath should never be pulled if the SBP is > 170 mmHg or if the activated clotting time (ACT) is too high (> 180 seconds). Rarely is surgery indicated except for:
 - Progressive enlargement of hematoma
 - Skin compromise
 - Evidence of femoral nerve compression
 - Severe pain

Remember that up to 20% of patients will develop wound infection after surgery for hematoma, and seroma formation is common.

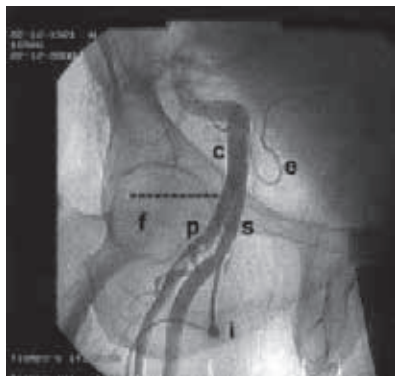
- **Pseudoaneurysm ($\leq 1\%$ of cases, though reported much higher in some series):** If the pseudoaneurysm is < 3 cm then repeat duplex is needed in one to two weeks to assess for spontaneous thrombosis (89% of patients with pseudoaneurysm < 3 cm will resolve in 21 days¹²). Treatment should be performed if size ≥ 3 cm or if there is failure of conservative therapy with observation with either growth of the aneurysm sac or failure to thrombose. Treatment includes:
 - Surgery — Gold standard, though now only used for emergent purposes or when more conservative methods fail (i.e. Thrombin injection).
 - Mechanical compression — Usually ultrasound-guided compression or by Femostop. This treatment has fallen out of favor secondary to patient discomfort with the technique.
 - Thrombin injection — This is now the most widely used method for treatment. Needle is advanced under ultrasound guidance and thrombin is injected to thrombose the aneurysm sac. Care must be taken to not inject into the artery proper and very slow injection is needed to prevent reflux of thrombin into the native artery.
- **Retroperitoneal hematoma (occurs in approximately 0.5% of cases):** This is the most dreaded access complication secondary to having a delayed diagnosis and the potential of high morbidity/mortality. Usually this occurs secondary to a high puncture. Obviously if the sheath is located above the origin of the inferior epigastric or deep circumflex iliac artery (consistent with puncture



of the external iliac artery), then pulling the sheath will likely lead to a retroperitoneal hematoma. However, it should be noted that even if the sheath is located below the origin of the inferior epigastric artery, but superior to the inferior border of the inferior epigastric artery (the borderline area), there still may be increased risk of retroperitoneal hemorrhage¹³. It has been our practice to use a closure device rather than performing manual compression for hemostasis when the sheath is removed and the access site is high. We prefer a suture mediated closure device that allows the sheath to be reinserted if the device fails (i.e. PERCLOSE® Suture; Abbott Vascular, Redwood City, CA). Contralateral access for balloon-protected closure device deployment or placement of a covered stent can also be used. If a vascular closure device is used for hemostasis when the sheath was clearly placed in the external iliac artery, then confirmatory angiography should always be performed to make sure hemostasis has been achieved.

Key Points:

1. If good access techniques are used, and a femoral angiogram is routinely performed to evaluate for high puncture, the rate of retroperitoneal hematoma can be drastically decreased.

Femoral Angiogram

- C – External iliac artery
- f – Femoral head
- P – Profunda femoris artery
- S – Superficial femoral artery
- e – Inferior epigastric artery
- i – Sheath

Femoral angiogram demonstrating sheath placed below the level of the femoral head in the superficial femoral artery. Note there is a high CFA bifurcation.



2. Have a low index of suspicion for retroperitoneal hematoma. Any patient who is status post CFA access with increasing back pain, decreasing hematocrit, or decreased BP should have stat non-contrasted CT.
 3. Treatment can be conservative in stable patients but unstable patients can be treated with transcatheter embolization or covered stent.
- **Arteriovenous fistula (occurs in < 1% of patients):** Most common cause is inadvertent puncture of the profunda femoris artery and vein. Most patients will have spontaneous resolution (80% resolve by one month) but even when persistent, treatment is rarely needed¹⁰. Indications for treatment include arterial insufficiency or venous hypertension. I have discovered many incidental arteriovenous fistulas from previous heart catheterizations in my practice, but never have discovered one that needed treatment. Arteriovenous access procedures purposefully are created to achieve dialysis access with much larger connections and without significant hemodynamic changes requiring ligation of the access.
 - **Acute thrombosis of the access artery:** This can be secondary to dissection caused by access, occlusive sheath in a small or diseased artery, or secondary to a complication from a vascular closure device (most common).
 - **Dissection:** Usually secondary to disruption of large posterior plaque when advancing the wire during initial access. Can be recognized secondary to not being able to aspirate blood from the sheath after it has been placed. A transducer is very helpful to evaluate if the sheath is in the true lumen, there should be an arterial waveform present. Never flush forward with saline or contrast if blood cannot be aspirated. If the sheath is in a dissection plane then this can enlarge the dissection plane.
 - Wires with a good transition at the distal segment will give the operator feedback and help decrease the risk of advancing the wire subintimally.
 - **Wire perforation:** Usually involves a perforation of the inferior epigastric or deep circumflex iliac artery during initial access but can involve other arterial branches as well if the guidewire is advanced a long distance without fluoroscopic guidance. This can be treated with transcatheter embolization but may have a delayed diagnosis and present as bleeding into the retroperitoneal space.



OTHER ENDOVASCULAR COMPLICATIONS

- **Perforations or rupture of artery:**
 - **Wire perforations:** This is usually secondary to use of a hydrophilic wire in a visceral artery, though it can happen in any arterial territory (internal iliac, profunda femoris, infrapopliteal vessels, etc.). Hydrophilic wires should be avoided during mesenteric and renal artery intervention except in very rare cases secondary to this potential risk. If perforation does occur, then this can be treated with superselective embolization.
- **Vessel rupture:**
 - There are many causes including:
 - Oversize of a balloon-expandable stent or balloon.
 - Can occur with 1:1 sizing if the vessel is highly calcified.
 - Advancing large bore device such as thoracic stent graft through either a small, tortuous, or highly calcified vessel.
 - Balloon developing a pin hole rupture during angioplasty.
 - This can be treated with the placement of a covered stent in most cases, but at times open surgery is needed. Always quickly reinflate the balloon to obtain hemostasis while the appropriate devices are gathered for repair.
- **Atheroembolism:** Potentially one of the most devastating complications that can occur during an endovascular procedure. Can range from sub-clinical to fatal. Can be greatly avoided with careful catheter manipulation and constant monitoring of the pressure at the tip of the catheter with a pressure transducer. A hostile aorta can quickly be diagnosed if the pressure dampens at the tip of the catheter during attempted selective angiography. When performing carotid stenting, a large number of the strokes are related to atheroembolism during the attempt to gain access to the carotid artery before the lesion is ever crossed!
 - Signs of atheroembolism include livedo reticularis, blue toe syndrome, and renal failure.



Pearls to Avoid Complications

1. To prevent clot from forming at the tip of the catheter, always keep a column of heparinized saline in the catheter by using a flow switch or manifold to prevent back bleeding.
2. Never let a flush catheter (i.e. pigtail) sit in the aorta and then flush it. When you aspirate you may have blood return secondary to the side holes, but there can be clot located at the tip distal to the side holes that dislodges with forward flushing. In relation to this, I always pull the pigtail to the descending aorta after performing an aortic arch angiogram before exchanging for a different catheter to prevent potential stroke with advancement of the guidewire through the pigtail.
3. Hemodynamic assessment at the tip of the catheter should always be performed prior to any forward injection of contrast or saline to avoid inadvertent injection of clot from the catheter tip, atheroembolism, barotrauma to the vessel wall, and aggressive injection into a hemodynamically significant complex stenosis.
4. Spin the pigtail in the distal aorta to make sure the tip is not in a lumbar artery prior to power injecting.
5. Never advance a sheath without an introducer or diagnostic catheter without a wire.
6. Be very careful to let guide catheters back bleed before injection after advancing through the aorta secondary to the risk of injection of atheroembolic material. Guide catheters can “snowplow” plaque when advanced through hostile arteries secondary to lack of an introducer and a larger ID than diagnostic catheters.
7. Either use ultrasound-guided puncture or fluoroscopic-guided puncture to make sure you are not puncturing above the inguinal ligament. Always perform routine femoral angiogram at the conclusion of the procedure to document location of sheath placement.



8. If the wire does not pass easily in the common femoral artery, then DO NOT FORCE IT.
9. It is very important to “form” catheters correctly to prevent distal embolization with “aggressive maneuvering” (i.e. SIMMONS SIDEWINDER Catheter is an active catheter and must be formed with care, arch manipulation can result in neurologic events).
10. Always keep the patient’s renal function status in the “back of your mind” to limit contrast in patients at risk and avoid contrast-induced nephropathy. With modern fluoroscopic equipment rarely is full strength contrast needed during subtraction angiography.
11. If you rupture an artery with an oversized balloon, do not tamponade the artery with a smaller balloon because you will not achieve hemostasis!
12. Never pull a wire briskly back from the subclavian artery or aortic bifurcation secondary to risk of “cutting” the bifurcation, we have termed this a “cheese cutter effect.”



CHAPTER 7

CLOSURE DEVICES AND THEIR COMPLICATIONS

Aravinda Nanjundappa and Mark C. Bates

BACKGROUND

The importance of meticulous access technique and proper access management can't be understated since access complications are the most common adverse event in most transcatheter studies. The mainstay of vascular access management for patients undergoing percutaneous femoral arterial access is manual compression. Vascular closure devices (VCDs) have been used since 1995 to provide patient comfort, early ambulation, and early hospital discharge after a diagnostic or interventional cardiovascular procedure. Despite the numerous devices available and ease of use of VCDs, the complications continue to be the Achilles heel. The main complications of the VCDs are device failure, bleeding, hematoma, infection, femoral artery dissection, inadvertent intra-arterial deployment of procoagulant material, limb loss, and need for surgical rescue in a minority of cases.

Commercially Available VCDs Can Be Categorized As:

1. **Compression devices:** e.g. FEMOSTOP Device (St. Jude Medical, Inc., St Paul, MN) and SAFEGUARD® Device (Maquet Cardiovascular, Wayne, NJ).
2. **Topical hemostasis agents:** e.g. D-STAT® Flowable Hemostat (Vascular Solutions, Inc., Minneapolis, MN), SYVEK® Agent (Marine Polymer Technologies, Inc., Danvers, MA), and CLO-SUR PLUS P.A.D. (Scion Cardio-Vascular, Inc., Miami, FL).



3. **Invasive:** (A) suture-based, e.g. PERCLOSE® Suture and PROSTAR® Suture (Abbott Vascular, Redwood City, CA); (B) invasive, medicated collagen plug, e.g. ANGIO-SEAL Vascular Closure Device (St. Jude Medical, Inc., St Paul, MN); DUETT Sealing Device (Vascular Solutions, Inc., Minneapolis, MN), and VASOSEAL Device (St. Jude Medical, Inc.; St. Paul, MN); and (C) clip-based, e.g. STARCLOSE® Device (Abbott Vascular, Redwood City, CA) and EVS (expanded vascular stapling) (Angiolink Corp., Taunton, MA).
4. **Invasive without a foreign-body:** e.g. CARDIVA CATALYST System (Cardiva Medical, Inc.; Sunnyvale, CA).

Potential Complications with Closure Devices

1. Femoral angiography in an ipsilateral oblique projection should be done before placement of any VCD. The angiogram should confirm the arterial puncture/sheath interface is in the common femoral artery (CFA) and preferably is consistent with an anterior wall puncture. The angiogram should also confirm the CFA is within the size threshold for the selected device (most critical in systems that have a footpad for anchoring the system against the anterior wall). Finally the CFA must be free of significant disease and for some closure systems that are clip or suture based there should also not be severe calcification.
2. Learn the proper technique for use of each device.
3. Adhere to *Instructions for Use* (IFU) and understand that off-label use may result in complications. Reading the IFU is critical before using any device for the first time.
4. Preferably use the device that you are familiar and comfortable with in a consistent fashion.

Potential Complications with Closure Devices

1. **Hematoma:** Additional manual compression for 3 to 5 minutes should be performed if a hematoma is developing, or longer if needed. However late hematoma both large and small can result in significant pain, discomfort, ecchymosis, possible nidus for infection and rarely needs surgical evacuation if there is potential for skin necrosis or if patient has severe pain and continued enlargement.



2. **Surface hemorrhage:** Small oozing from the arterial puncture site is common and can often be effectively treated with manual pressure. Persistent bleeding will require additional manual compression or adjuvant compression device such as C clamp or femostop.
3. **Retroperitoneal bleed (RP):** A serious complication that can cause death. RP bleed can occur when VCDs are deployed in cases outside the IFU. These scenarios are usually related to a high femoral artery puncture or external iliac artery puncture, concomitant puncture of inferior epigastric artery or deep circumflex iliac artery, multiple punctures for access, and device failure. Management of RP bleeding is discussed in further detail in the *Endovascular Complications* chapter.
4. **Infection:** Localized and deep vascular infection can occur. Clean the puncture site with chlorhexadine or alcohol pad, use new gloves and selective antibiotic use may reduce infections although these techniques have not been systematically studied.
5. **Device failure:** Strict adherence to indications and IFU for each device can reduce the device failure rate.
6. **Embolization:** This can lead to acute limb ischemia, limb loss, and death. Usually secondary to inadvertent deployment of the device intra-arterially. This can be avoided by not using VCDs in small diameter arteries or arteries that are diseased (anchor can “catch” plaque resulting in intra-arterial deployment of device). Emergent angiogram, use of a snare, or adjuvant covered stent can help but often surgical rescue is needed.
7. **Vessel thrombosis:** Can occur if back wall of the artery is “captured” by the device or if foreign material is introduced into the artery (i.e. collagen). This too can usually be circumvented by avoiding use of VCDs in small diameter arteries and arteries that are diseased. Angiogram and use of balloon angioplasty and lytic therapy can be considered but stenting of the CFA has long-term negative consequences and should be avoided unless the patient is a nonsurgical candidate. Surgery is the mainstay of therapy in most cases.



Tips and Tricks to Avoid VCD Complications

1. Perform femoral access angiogram prior to deployment of device.
2. Remember manual compression is the standard of care that VCDs are measured against.
3. Adhere to IFU for each device.
4. Learn each deployment step well and master the device that you want to use.
5. Watch for complications and if they do arise, always have a bailout plan.
6. Have covered stents available and know techniques for coil embolization.
7. The use of VCDs outside the femoral artery has not been systematically studied and off-label use should only be considered in unique circumstances with careful consideration of risk-benefits.



CHAPTER 8

ANEURYSM DISEASE

Patrick A. Stone

BACKGROUND

Definition of aneurysm: Dilation of vessel $> 1.5 \times$ the diameter of normal adjacent vessel.

- *Ectasia:* Less than $1.5 \times$ the normal diameter of the vessel.
- *Aneurysmosis:* Patients with multiple discrete aneurysms.

Etiology — multifactorial: **DEGENERATIVE**, genetic component, smoking, infectious and other theories.

Classifications

True aneurysm: All layers of vessel involved.

Pseudoaneurysm: Contained rupture.

As a rule:

Intracavitary aneurysms have the propensity to rupture.

Peripheral aneurysms more often present with thrombo-embolic complications.

Pearls

Visceral aneurysms: Splenic $>$ hepatic $>$ celiac $>$ SMA.

Subclavian aneurysms: Up to 50% have aortoiliac or peripheral aneurysms.

Ulnar artery aneurysms: Mostly male, < 50 yr, present with digital ischemia (4th and 5th digits), thrombolysis beneficial, vein interposition best treatment.



ABDOMINAL AORTIC ANEURYSMS: AAA

Background

First successful open AAA repair in 1951 by Dr. Dubost in Paris using homograft via extraperitoneal approach.

Dr. Cooley developed a double velour Dacron graft in 1978.

Incidence:

- 3% of men older than 65 years old.
- 5% of patients with CAD.
- 10% of patients with PAD.
- 50% of patients with popliteal aneurysm.

Risk factors:

- *Gender:* men (3:1), smoking (8:1), hereditary, infectious?
- *Average age:* 70

Miscellaneous facts:

- Average growth 10%/year.
- > 50% will require repair within 3 years for those with diameters 5.0–5.4 in both UK and ADAM study.
- 95% of aneurysms are below renal arteries.
- Normal aorta diameter: infra-renal aorta 16–22 mm
 - Approximately 2 mm larger in men

Physical Examination

Pulsatile abdominal mass, (typically non-palpable until near 5 cm).

Examine for other aneurysms—popliteal most common.

Screening

January 1, 2007 SAAAVE ACT (Screening Abdominal Aortic Aneurysm Very Efficiently): One time ultrasound for screening for men ages 65–75 who have smoked 100 lifetime cigarettes, or men or women with family history.



Diagnosis

1. **Plain abdominal X-ray** — 70% of cases have enough calcium present that AAA seen on abdominal X-ray.
2. **Ultrasound** — Modality of choice for surveillance, within 3 mm of operative findings.
3. **Computed tomography** — Primary imaging modality to plan intervention.
4. **Magnetic Resonance Imaging (MRI)** — Seldom used as primary imaging modality, but accurate if imaging for other pathology, i.e. back pain and find AAA.

Estimated annual risk of rupture:

AAA IN CM	RISK OF RUPTURE
4–4.9:	(1–5%)
5–5.9:	(5–10%)
6–6.9:	(10–20%)
7–7.9:	(20–40%)
> 8:	(30–50%)

Laboratory Tests/Evaluations

- CBC, BMP, PT, PTT, chest X-ray, EKG.
- Formal cardiac evaluation in patients considered for open repair.
- Type and cross match.

Intervention

- **Symptomatic any size:** abdominal/back pain, rupture, atheroemboli, and rarely heart failure from aortacaval fistula.
- **Asymptomatic:** 5.5 cm in men, some recommend when 5 cm in women.

Once repair is contemplated, a computed tomography with contrast (CTA with 3-D Recon) should be performed to evaluate endovascular candidacy.

- **Late survival:** Mean survival 7 years compared to 15 years for general US population.



Critical Points in Evaluating CT

These points are important in addition to the basics discussed below in the endovascular repair section:

Anatomic Features to Note on Review of CT: Figure Chart for Measurements

- **Location of renal vein in respect to aorta:** Anterior, posterior, collar vein.
- **Neck:** Amount of mural thrombus, length 10-15 mm from renal artery, and diameter.
 - Reverse conical neck — highest predictor of early and late Type I endoleak from EVAR
- **Length:** From lowest renal to aortic bifurcation and to internal iliac arteries.
- **Patency of visceral and renal arteries and hypogastric arteries:** May need to consider concomitant repair.
- **Diameter of aorta bifurcation:** < 19 mm — concern for graft compression.
- **Number of lumbar vessels and evaluation of IMA:** Patent IMA associated with increased Type 2 leaks.
- **Diameter:** 10–15 mm from internal iliac arteries (distal seal zone).
 - **Most common reason not on IFU for EVAR:* Short neck length.
 - *In patients who are high risk for open repair then consider:* Off-label use of snorkel techniques or commercially available or custom fenestration.

OPEN REPAIR

Open Pearls

Pre-Op Preparation:

- Bowel Prep: 1 bottle of Magnesium Citrate
- HIBICLENS® (chlorhexidine gluconate solution 4.0% w/v) shower preop
- NPO after MN
- Type and cross match
- Informed Consent on chart

This manual does not include all the information needed to use the drugs listed herein safely and effectively. See full prescribing information and any boxed warnings for these drugs.



- **Key portions of informed consent:**
 1. Indications for procedure: i.e. size, symptom status and risk with observation.
 2. Alternatives: Why not an endovascular candidate? Or is observation safer?
 3. Major risks: Estimated risk of perioperative mortality < 3%; other common risks: renal failure, embolization requiring lower extremity revascularization, ileus, hernia, infection, etc. Refer to major complication section for improving consenting.
 4. If thoracic aneurysm repair is risk of paraplegia.
 5. For EVAR: continued surveillance, contrast issues, risk of endoleaks and their management.

General Principles of Open Repair:

- Suprarenal crossclamping is associated with exponential incidence of postoperative complications when > 35 min.
- Repair iliacs at time of open repair if iliac diameter is > 2.0 cm.
- Reimplant IMA if poor back bleeding, stump pressure < 40 mmHg, severe hypogastric disease, previous colon resection secondary to poor collateralization, or if colon appears ischemic at end of operation.
- Alert anesthesia prior to unclamping. Unclamping can result in severe hypotension.

Transperitoneal Incision

- Allows ability to explore the abdomen.
- More difficult to expose suprarenal aorta.
- May encounter previous abdominal adhesions.
- Familiar to most surgeons.

Technique:

- Either midline incision or transverse incision can be used. Small bowel is mobilized to the right side of the abdomen and posterior peritoneum opened from ligament of treitz to aortic bifurcation.
- Square of veins surrounding AAA from transperitoneal approach: left renal, IVC, IMV, LCIV. Note: will get image needed for eversion.
- Minimize dissection of LCIA region — parasympathetic nerves responsible for male erectile function.
- Circumferential dissection around the iliac arteries poses a risk to iliac vein injury. ** Danger **



Retroperitoneal Approach

- Potentially less pain, and decreased ileus.
- Ideal for patients with previous abdominal surgery.
- Ability to gain suprarenal control is easier than transperitoneal approach.
- Difficulty with exposure of right Iliac artery.

Technique:

- Place patient on bean bag, kidney rests between iliac crest and costal margin, right side down with left arm on ether screen or arm rest.
- Once bean bag inflated, adjust the pelvis closer to flat.

Incision:

- 10th intercostal space — Juxtarenal.
- 8th intercostal space — Visceral involvement.

Dissection:

- Peritoneum thickest laterally.
- Lumbar vein — Landmark for left renal artery.
- Can ligate left renal vein but it should be ligated *near* IVC. Additional drainage via, gonadal, phrenic, adrenal veins, and lumbar vein.
- The Achilles heel of this approach is exposure of the right iliac artery
 - This limitation can be overcome by extending the incision across the midline or a counter incision in the right lower quadrant.
- Fogarty catheter with 3-way stopcock can be used to occlude the iliac artery from within the vessel.
- If the diaphragm needs to be divided for more proximal control, this can be done with a stapler device radially to allow for easier approximation at the conclusion of the procedure.



Postoperative Complications

- **Hypertension** — *keep b.p. < 140 mmHg*: Increased bleeding risk with uncontrolled b.p.
- **Death**: 5% from national estimates.
- **MI up to 15%**: Suspicion check Troponin, EKG.
- **Hypotension**: Intraoperative/postoperative hemorrhage secondary to venous injury or lumbar veins.
- **Ischemic colitis**: 2% of elective cases
 - Presentation: Bloody or any diarrhea, acidosis, requiring persistent fluid administration without anemia, usually within 48 hours of surgery
 - Mortality between 50–90% if colonic gangrene occurs
- **Renal failure**: Hypotension, atheromatous embolization.
- **Limb ischemia**: Usually secondary to embolization.
 - Prevention: Clamp iliac arteries first, then aorta
- **Abdominal compartment syndrome**: Common in ruptures or massive fluid resuscitation—must rule out hemorrhage, check bladder pressures.
- **Paraplegia**: Rare < 0.5%

ENDOVASCULAR ANEURYSM REPAIR (EVAR)

Background

- 1990** First successful endovascular aneurysm exclusion performed by Juan Parodi in Argentina.
- 1999** FDA approval of first stent-graft in US: Medtronic ANEURX® Stent Graft System and Guidant ANCURE® Aortoiliac System.
- 2002** GORE® EXCLUDER® Device
- 2003** COOK® ZENITH® Trimodular Device
- 2005** Endologix POWERLINK® System
- 2012** COOK® ZENITH® Fenestrated Device

Candidates (For Non-Fenestrated Device)

The FDA-approved devices have *Indications for Use* (IFU) which include anatomic suitability based on approval. These indications are based on neck and distal seal length, neck and distal seal diameter, and angulation of the aneurysm.



- **$\geq 10\text{--}15$ mm neck length:** Approved in as short as 10 mm with some devices.
- **Neck diameter ≤ 32 mm:** Gore devices can treat up to 32 mm diameter (measured intima-intima) neck whereas the Medtronic TALENT Abdominal Stent Graft, ENDURANT® Device and the COOK® ZENITH® Device are indicated up to 32 mm for diameters (measured adventia-adventia).
- **Aortic angulation:** < 60 degrees
- **Distance from renals to aortic bifurcation:** Varies with device configuration, i.e. has to be > 7 cm for GORE® EXCLUDER® Device except for 31 mm and 35 mm devices. Aortic bifurcation diameter should be > 18 mm or at risk for limb compression.
- **Access vessels:** Must be able to accommodate the delivery sheath of device. This may require a conduit, serial dilation or endografting in small iliac cases.

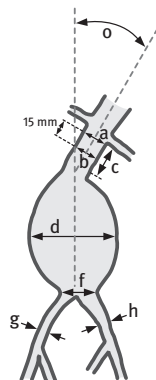
Basic Concepts of EVAR

- Treat from renals to hypogastric arteries.
- Most common complication involves access vessels.
- Treating patients off IFU is the most common cause of graft dysfunction.
- **Reverse conical neck:** Poses a significant risk factor for late endoleak.
- **Distal extensions and cuffs:** Are often useful to preserve hypogastric blood flow. If greater than 28 mm in distal common iliac, will require preoperative embolization or surgical ligation of internal iliac artery, or consider preoperative EIA to IIA bypass with proximal internal iliac artery ligation.



EVAR Sizing

ANATOMICAL LOCATION	MEASUREMENT (mm)
a Aortic Diameter at Proximal Implantation Site	19 – 32
b Aortic Diameter – 15 mm Inferior to Proximal Implantation Site	19 – 32
c Aortic Neck Length	≥ 15
d Maximum Outer Aneurysm Diameter	No Requirements Baseline
e Length from Lowest Renal to Native Bifurcation of the Aorta	> 70 for 23, 26, 28.5 mm devices, > 80 for 31 mm device, > 90 for 35 mm device
f Minimum Diameter of Distal Neck	≥ 18
g Right Common Iliac Diameter	8 – 25
h Left Common Iliac Diameter	8 – 25
i Right External Iliac Diameter	5.0, 6.8
j Left External Iliac Diameter	5.0, 6.8
k Length from Lower Renal to Right Internal Iliac	≥ 120 ≥ 140
l Length from Lower Renal to Left Internal Iliac	≥ 120 ≥ 140
m Right Iliac Length for Sealing	≥ 10
n Left Iliac Length for Sealing	≥ 10
o Proximal Aortic Neck Angle	≤ 60°



**GORE® DrySeal Sheath
with Hydrophilic Coating**

12 Fr = 5.0 OD

18 Fr = 6.8 OD

19–26 mm = 23, 26, 28.5 mm devices
27–29 mm = 31 mm device
30–32 mm = 35 mm device

- Measure inner-wall to inner-wall
- **Do Not** measure calcium
- **Measurements A and B** must be within **2 mm** of each other to avoid reverse taper
- Measure thrombus ≤ **2 mm** thickness and / or ≤ **25%** circumference
- Measure short axis for all measurements, **except Measurement D** is long axis
- **Measurement F** is short axis and long axis, **not measuring thrombus**

 Consult Instructions for Use

Standard EVAR Procedure

Ipsilateral side dictated by the side of access by the main body.

Contralateral side designated by side which contralateral limb will be inserted.

Either surgical cutdown or percutaneous access is acceptable. Currently over 90% of our cases our performed percutaneously.



- Cutdown should be performed via small transverse incisions over common femoral artery **unless previous vertical incision is present.**
- *Percutaneous access — off-label use:* Two PERCLOS® Devices oriented 45 degrees off vertical axis placed bilaterally.
- From the contralateral side — pigtail catheter inserted and length to hypogastric artery confirmed with preoperative CT. Subsequent imaging in magnified view to identify lowest renal artery ostium. The appropriate angle of the image intensifier can be obtained by the preoperative CT scan and is generally in the range of 15–30 degrees LAO and 20–30 degrees cranial to caudal. After deploying the main device inferior to the lowest renal artery, the contralateral gate is then accessed. This can typically be achieved with an angled hydrophilic catheter and angled hydrophilic wire.
- Assurance that gate cannulation is achieved and that the wire is not behind the graft is imperative. Spin the pigtail catheter within the main body. IVUS can also be used or a contralateral catheter to hook the flow divider.
 - If gate cannulation is unsuccessful via retrograde cannulation of the contralateral gate, then attempts by up-and-over from the main body side or brachial artery with snare technique should be pursued. If gate cannulation is deemed not possible (i.e. jailed out), then convert to AUI. Subsequently the contralateral common iliac artery should be occluded and a surgical (8 mm ringed prosthetic) femoral-femoral bypass created.
- Contralateral limb should then be deployed within 1 cm of the hypogastric artery ideally.

Imaging Follow-Up

At 1/6/12 months CT angiograms should be performed to assess for endoleaks and sac regression. If endoleak detected at one month, a three-month imaging study is advised.

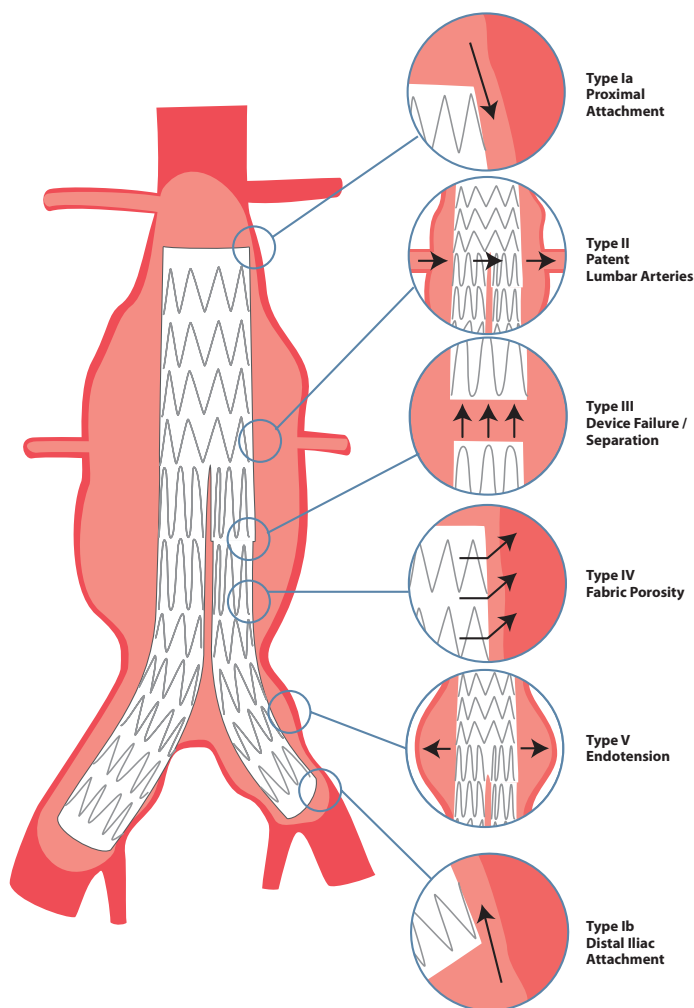
Plain abdominal films also are recommended at one month and yearly to assess for migration and stent fractures.

Endoleak: 15%

- *Type 1* – proximal or distal fixation sites — requires repair.
- *Type 2* – Lumbar, accessory renal, or IMA related — can be observed as long as sac size is stable, i.e. < 5 mm growth from baseline. Most common detected.



Endoleak Types





- If a Type II endoleak is present, and the aneurysm sac grows by ≥ 5 mm, then angiography should be performed. Most Type II endoleaks can be assessed by selective angiography of either the hypogastrics or SMA. Direct sac puncture with either thrombin or glue administration has been described by some groups, but we have found it rare for Type II endoleaks to not be able to be addressed by transcatheter techniques via femoral arterial access. If endovascular measures fail, then consider operative repair with sac decompression and ligation of vessels (i.e. lumbar or IMA) vs graft explantation.
- **Type 3** – Junction leaks (between stent grafts) — require repair.
- **Type 4** – Porosity of graft — often resolves spont., seen in older generation grafts.

See previous page for diagram of Endoleak types.

RUPTURE AAA

Background

50% rule: 50% make it to hospital alive. Of those alive on arrival, only 50% survive operation. There is an overall 75% mortality.

15,000 patients die annually of rupture.

13th leading cause of death in United States.

Predictors of mortality in ED: Increasing age, Hgb < 10 , elevated creatinine, syncope, cardiac arrest $> 90\%$ mortality.

History and Physical Examination

Classic triad of: Abdominal pain, pulsatile abdominal mass and hypotension.

*Most common misdiagnosis — Renal colic

Diagnosis/Imaging

- **Ultrasound:** Readily available in most emergency departments.
- **Computed tomography:** In hemodynamically stable patients this will provide the essential information for determining mode of therapy.
- **Laboratory evaluation:** Basic metabolic panel, complete blood count, and type and cross match packed red blood cells, urinalysis — hematuria in up to one-third of patients.



Treatment

Permissive hypotension: Massive fluid resuscitation will actually result in more bleeding and worse outcome.

While waiting for anesthesia team or angio suite staff, place foley catheter, vascular sheath in jugular and radial arterial line if possible to expedite the case once in the operating theater.

Predictors of mortality following ruptured AAA:

1. **Bleeding:** 90%—Either coagulopathy from massive blood loss or iatrogenic venous injury during dissection.
2. **Renal failure:** > 70%
3. **Ischemic colitis:** > 60%
4. **Respiratory failure**

Intervention:

- **Open:** Should be reserved for unstable and non-endovascular candidates.
- **Endovascular:** If hypotensive, rapidly place balloon to occlude thoracic aorta. If difficulties cannulating the contralateral gate, then be prepared to convert to aortouniliac repair with contralateral iliac occlusion and femoral-femoral bypass. Some centers advocate initial AUI placement.

*Dramatic improvement in morbidity and mortality when comparing endovascular vs. open repair.

Open Repair Pearls

- **Prep neck to knees:** Retroperitoneal vs. transabdominal.
- **Make incision during induction:** Often patient decompensate at that time.
- **Supraceliac control:** Take down triangular ligament, the lesser sac is entered. Esophagus is mobilized to left, the crus of diaphragm can be divided. Rapid exposure of infrarenal aorta to lessen ischemic injury is imperative. Often a tube graft can be performed instead of bifurcated graft. Also, sometimes secondary to retroperitoneal hematoma, visualization of the iliac arteries are limited and intravascular control is a safer maneuver.



Concern for development of abdominal compartment syndrome and ischemic colitis post-op.

Some surgeons feel routine sigmoidoscopy should be employed after ruptured AAA repair.

ILIAC ARTERY ANEURYSMS

Background

Up to 30% of AAA will have concomitant involvement of iliac arteries. 1–2% have isolated iliac artery aneurysms.

75% involve the common iliac artery, and 10–20% involve the internal iliac artery.

Average growth is .1 to .2 cm/year.

Physical Examination

Rarely can palpate, except in very large aneurysms or if involving the hypogastric artery can often palpate on rectal examination.

Most series report > 50% of patients with symptoms: Compression related are most common with lower abdominal and flank pain frequent.

Diagnosis/Imaging

Ultrasound: To assess for size and for surveillance.

Computed tomography: For treatment planning of either open or endovascular repair.

Treatment

Repair when > 3.0 cm or > 2 cm at the time of open repair of AAA.

Interventional Considerations:

Endovascular exclusion: Requires 15 mm of healthy artery at both proximal and distal landing zones. It is rarely feasible to do single covered stent placement with iliac limb of endograft; consider embolization of the hypogastric artery and place a modular device or consider ileo-ileo bypass in younger patients vs. open repair.

Open: If isolated CIA aneurysm, can do retroperitoneal or transabdominal repair with prosthetic graft interposition.



Controversy exists over repair of bilateral iliac artery aneurysm. Some have suggested that bilateral embolization is well tolerated. Other authors advocate preservation of at least one hypogastric artery. Future technology involves branched endografts.

THORACIC AORTIC ANEURYSMS (TAA)

Background

10% national operative mortality for elective repair of TAA aneurysms. Approximately 2:1 male to female ratio (unlike AAA which has a 7:1 ratio).

15–20% are secondary to previous dissection.

60% involve ascending aorta.

40% involve descending aorta.

Natural History

10 mm/year growth average.

Growth greater in descending and dissecting location aneurysms and in those with Marfans.

Annual rupture risk¹:

< 5 cm: 2%

5–5.9 cm: 3%

> 6 cm: 7%

Classification of Thoracoabdominal Aneurysms

Crawford

Type 1 — Subclavian to renals.

Type 2 — Subclavian to aortic bifurcation.

Type 3 — Midthoracic aorta to aortic bifurcation.

Type 4 — Thoracic aorta at diaphragm to aortic bifurcation.

Physical Examination

No physical exam findings specifically suggest TAA.

Diagnosis/Imaging

Occasionally detected on chest X-ray, generally now identified by computed tomography while evaluating other pathology in the chest.



Intervention

Repair if symptomatic or > 6 cm in maximum diameter.

Treatment

Endovascular or open surgical reconstruction.

Basics of Endovascular Exclusion

Approved Devices

2005: GORE® TAG® Thoracic Endoprosthesis (Flagstaff, AZ)²

2008: COOK® ZENITH® TX2® Device (Bloomington, IN), Medtronic Talent (Santa Rosa, CA)

- Access, access, access.
- Up to one-third of patients in randomized trials required conduits.
- Need to image from aortic valve to common femoral arteries on preoperative CT scan.
- IFU recommends 2.0 cm of normal aorta proximally and distally (exception of COOK® thoracic devices, which recommend 2.5 cm of normal aorta proximally and distally).
- Must deploy smaller diameter devices first to prevent type 3 leaks.

Zones of thoracic aorta image:

Zone 0: Proximal and including the innominate artery.

Zone 1: Distal to innominate and including the left common carotid artery.

Zone 2: Distal to left common carotid artery to just distal to left subclavian artery.

Zone 3: First 2–3 cm distal to left subclavian artery.

Zone 4: Below Zone 3.

- Consensus statement from SVS now recommends preoperative carotid subclavian bypass in cases of planned subclavian artery coverage secondary to the increased risk of neurologic complications.
- Controversy exists over coverage of celiac artery. Only small retrospective series presently in literature on safety with this approach.



Spinal drains:

Place spinal drains prior to TEVAR in the following circumstances:

- Previous AAA repair, concurrent AAA repair, planned large coverage area of thoracic aorta, and in patients with branch disease—hypogastric/profunda femoris arteries.
- We admit the patient the day before with planned drain placed pre-op, so that if unsuccessful, insertion can be reattempted the day of the procedure.

Post Procedure Management

The use of adjunct distal aortic perfusion and CSF drainage has reduced neurologic deficits to < 5%.

Mean perfusion pressure = mean arterial pressure — the spinal pressure. Goal over 60 mmHg.

Additionally if the spinal pressure exceeds 10 mmHg the drain is allowed to drain.

Drain is left in place for 24–48 hours, and is capped for 24 hours, if no neurologic deficit can be removed.

Delayed deficits can occur as early as 2 hours and up to post-op 2 weeks.

If neurologic deficit develops: increase the MAP to > 90 and if no drain in place, place emergent spinal drain.

PERIPHERAL ARTERY ANEURYSMS

Popliteal Artery Aneurysms

Background

- Normal size of popliteal artery 6–8 mm
- 5% of patients with AAA have popliteal aneurysms
- 25:1 male to female
- ½ bilateral, >50% have history of repair of nonpopliteal aneurysm, i.e. iliac, femoral, thoracic, abdominal



History and Physical Examination

- Widened pulse on examination
- Other previous aneurysm surgery
- Presentation:
 - *Asymptomatic*: In some series is the most common presentation. If followed, approximately 50% will become symptomatic.
 - *Symptomatic*:
 - *Claudication*
 - *Thromboembolic*: Up to 25% present with ALI
 - *Venous compression*: Present with leg swelling
 - *Rupture rare*

Diagnosis

Ultrasound: Most cost effective, and very accurate in determining size and presence of mural thrombus.

- If normal ABI, can perform CT or MR imaging
- If abnormal ABI, then traditional digital subtraction angiography

Intervention

- *Asymptomatic*: > 2 cm — some recommend treating any size with mural thrombus.
- *Symptomatic*: If thrombus in outflow vessels and acute limb ischemia stage 1 or 2a then consider thrombolysis, if 2b or good target then surgery preferred.

Specific Preop Checklist/Informed Consent

- HIBICLENS® (chlorhexidine gluconate solution 4.0% w/v) scrub the night before, vein mapping when indicated.
- **Mark and sign patient on both sides of extremity if doing procedure prone.
- Discuss risks of limb loss with observation or intervention.
- Risks associated with Infrainguinal surgery: i.e. infection, leg swelling, nerve injury-peroneal nerve with posterior repair, graft failure.
- Expected patency of reconstructions listed below.

This manual does not include all the information needed to use the drugs listed herein safely and effectively. See full prescribing information and any boxed warnings for these drugs.



Surgical Reconstruction

Technical Pearls

- **Bypass and exclusion:** Gold standard. Ideally in-situ vein bypass, can use vascular staple or suture ligature proximal and distal to aneurysm. Five-year primary patency > 80%.
- **Interposition — posterior approach:** 90% patency with ringed PTFE prosthetic interposition at two years.

Technique:

- **Posterior approach:**
 - “S” shape incision. Must identify and protect peroneal nerve. Nerve injury results in “foot drop.”
 - Routinely we use a prosthetic conduit with great long-term patency, either ringed ePTFE or DACRON® Material.
 - *Ideal treatment in patients with large aneurysms with compression symptoms and absent ipsilateral saphenous vein.*
 - Eliminates chance of late aneurysm expansion.
 - Patency rivals bypass and exclusion and does not burn bridge of bypass and exclusion in future.

Endovascular Exclusion

- Typically endovascular exclusion has been offered in patients at high risk for surgery or without autologous conduit. Although one small randomized trial has been published with similar short term patency to surgical reconstruction.
- Computed tomography angiography (CTA) is ideal to determine anatomic candidacy in a similar fashion to EVAR cases.
- **Ideal stent-graft patients include:** Stent does not cross knee joint/at least 2 vessel runoff.

Technical Pearls

- **Antegrade or retrograde access:** The availability of lower profile stent grafts has limited the need for femoral artery cutdown.
- **IVUS:** Identify mural thrombus and accurately measure diameter of sealing zones—consider in patients with renal insufficiency and those without preoperative CT scan.
- **Must deploy smaller graft first:** To prevent junctional leak.



Femoral Aneurysms

Background

- True aneurysms are uncommon.
- Anastamotic aneurysms secondary to suture fatigue or infection.
- Iatrogenic femoral pseudoaneurysm (PSA) are the most common.

Anatomic Location

- Can involve only CFA or either femoral/profunda, or all three.
- < 1% involves just SFA or deep femoral
- ½ of true aneurysms have contralateral femoral aneurysm or AAA.

Presentation

- Can be asymptomatic but also can present with thromboembolic or compressive symptoms.
- Deep femoral aneurysm—classic presentation—RUPTURE.

Diagnosis

- Ultrasound: Surveillance and initial imaging.
 - * Classic to-and-fro flow in pseudoaneurysms
- Computed Tomography: Can be used to plan operative repair.

Informed Consent

Risks associated with general anesthesia/infrainguinal reconstructions:

- **Graft failure:** Expected long term patency > 90% at 5 years.
- **Ultrasound guided thrombin injection (UGTI):** Arterial embolization, allergic reaction, rupture risks with observation.



Treatment Depends on Etiology

True aneurysms:

- *Symptomatic or infected:* Any size: surgical
- *Asymptomatic:* > 3 cm: Surgical repair
- *False aneurysm:* *Iatrogenic PSA: > 3 cm, etc.
- *UGTI:* Typically treat with 0.1 ml aliquots of thrombin, with tip of needle away from the neck within the aneurysm sac. Image tip location with B-mode of ultrasound.
- *If < 3 cm, then surveillance at 1–2 week intervals:* 90% resolve by 6 weeks.
- Picture for eversion.



*“ Vascular surgery is good above the
inguinal ligament...”*

J. P. Boland, MD



CHAPTER 9

PERIPHERAL ARTERY OCCLUSIVE DISEASE

Patrick A. Stone

BACKGROUND

Arterial insufficiency: 15% of population > 70 years of age.

< 5% risk of amputation at 5 years for patients with intermittent claudication.

Risk factors for PAD: Smoking, diabetes mellitus, hyperlipidemia, renal insufficiency, race, hypertension, increasing age.

Classic distribution of disease includes: Aortoiliac in young females and superficial femoral artery disease in males. Diabetics often develop disease in the infrapopliteal vessels.

ANATOMY

Renal arteries originate from the abdominal aorta at L1-2 vertebral bodies and the aortic bifurcation at L4-5 (superficial landmark-umbilicus), the next division is the internal and external iliac arteries with the later becoming the common-femoral artery at the inguinal ligament (superficial landmark is 2–3 cm above inguinal crease).

The common femoral artery divides into the deep femoral artery (typically laterally) and the superficial femoral artery (SFA). The SFA has been named the femoral artery recently to avoid confusion since it is by definition not a superficial artery. Once crossing the knee joint, the below knee popliteal gives rise to the anterior tibial artery which courses anterior and laterally through the interosseous membrane and becomes the dorsalis pedis artery once crossing the ankle joint. After the takeoff of the anterior tibial artery, the below-knee popliteal artery continues as the tibioperoneal trunk (TPT).

This divides into the posterior tibial artery and the peroneal artery. The peroneal artery is the more laterally of the two, which courses



lateral just under the fibula at the ankle. The posterior tibial crosses the ankle joint and branches into the medial and lateral plantar arteries.

Three Patterns of Aortoiliac Disease and Distribution:

1. Confined to aorto common iliac segment (5–10%).
2. Confined to abdomen but extensive disease including external iliac disease (25%).
3. Widespread disease above and below the inguinal ligament (65%).

Collateral Pathway for Patients with Aortoiliac disease

- Internal mammary to inferior epigastric.
- Intercostal to circumflex iliac artery.
- Lumbar and hypogastric to common femoral and deep femoral.
- SMA to IMA and superior hemorrhoidal pathways via the marginal artery of Drummond and arc of Riolo.

History

Asymptomatic: Despite having significant peripheral arterial disease, often patients are without claudication or rest pain secondary to either limited activity or neuropathy.

Symptomatic:

Claudication (Latin — to limp): described by patients as hip, thigh, and/or calf discomfort with ambulation that improves shortly after cessation of activity.

- Must be distinguished from pseudoclaudication:
 - Claudication pain should resolve in ≤ 5 min after cessation of ambulation..
 - Should not require the patient to sit down for pain to resolve.
 - Burning and tingling sensation can be more consistent with neuropathic cause.
 - Claudication should occur at reproducible distance.
 - Pseudoclaudication symptoms often occur with ambulation but also with standing and sitting for long periods if etiology is spine related.

Rest pain: Typically occurs in the medial aspect of the foot and is often worsened at night by leg elevation which impedes the gravitational effects of blood flow in patients with critical limb ischemia. Typically patients with rest pain will have dependent rubor



(red discoloration of foot) and dependent edema. In severe cases can be associated with a purple hue. Image for eversion.

Tissue loss: Non-healing ulcerations, gangrenous changes.

Rutherford classification is the most frequently used classification among vascular surgeons.

Rutherford Classification for Chronic Limb Ischemia¹⁴

RUTHERFORD CLASSIFICATION FOR CLI			
GRADE	CATEGORY	CLINICAL DESCRIPTION	OBJECTIVE CRITERIA
0	0	Asymptomatic	Normal treadmill test
I	1	Mild claudication	Can complete treadmill exercise with ankle pressure > 50 mmHg after exercise but 25 mmHg less than brachial pressure
I	2	Moderate claudication	Results between categories 1 and 3
I	3	Severe claudication	Cannot complete treadmill exercise, ankle pressure after exercise is < 50 mmHg
II	4	Ischemic rest pain	Resting ankle pressure < 40 mmHg , toe pressure < 30 mmHg , flat or barely pulsatile ankle or metatarsal pulse volume recording
III	5	Minor tissue loss	Resting ankle pressure < 60 mmHg , toe pressure < 40 mmHg , flat or barely pulsatile ankle or metatarsal pulse volume recording
III	6	Major tissue loss (extends above the transmetatarsal level, a functional foot is no longer salvageable)	Same as Category 5



Physical Examination

- **Inspection:** Should include the abdomen to toes, evaluating the abdominal girth and cleanliness of the groins for potential intervention as well as previous scars from procedures performed by other surgeons. The toes should all be separated and inspected for cracks and ulcerations. Patients with critical ischemia often have dependent rubor which is relieved with elevation of the extremity.
- **Palpation:** All pulses for quality and characteristics is important. Pulses are graded as non-palpable, 1+ faint, and 2+ as normal. Severely calcified vessels can be assessed as well as the presence of aneurysmal degeneration. The popliteal artery is the most common peripheral artery which becomes aneurysmal. It is not easily palpable behind the knee in most patients and when widened pulse is present should raise one's suspicion for aneurysm. Pedal pulses, both DP and PT, should be charted on the same grading system. In patients who have nonpalpable pulses, hand-held continuous wave Doppler should be used. Multiphasic and monophasic auditory waveforms should be recorded depending on the characteristic.

Non-Invasive Testing

Ankle brachial index (ABI): Ankle brachial index should be performed in all patients who are assessed for PAD. Toe brachial index is often helpful in the diabetic patient, patients > 80 years of age, and in those with critical ischemia to assess digital blood flow.

Calculating the ABI: The highest pressure measured in tested extremity (dorsalis pedis or posterior tibial) divided by the highest of the two pressures measured in the upper extremity.

ABI:*

WNL:0.9 – 1.3

*May be falsely elevated in DM and
in patient's > 80 years age.

Mild:0.7 – < 0.9

Moderate: .0.4 – < 0.7

Critical:< 0.4



Toe pressure: < 30 mmHg not compatible with healing a digital amputation or significant digital tissue loss, digital pressures are less affected in DM than the the ABI, NL TBI > 0.7.

Segmental Pressures:

- **High thigh, AK, BK and ankle:** > 20 mmHg drop is significant.
- **Profunda Popliteal Collateral Index (PPCI):** If < 0.5 should improve symptoms with profundaplasty or inflow procedure alone.
- **AK pop — BK pop pressure/AK pop pressure:** the higher the gradient across the knee the more likely an infrainguinal reconstruction will be needed.

Exercise treadmill testing: To assess patients with either normal ABI and classic symptoms or combined pathology (i.e. neurogenic and arterial to assess significance). Also used to classify functional capacity and categorize severity of claudication.

- 1.5 mph at 12% grade for five minutes or until symptoms cause patient to stop. If ankle pressure drops to < 50 mmHg and with symptoms, then consistent with severe claudication. Mild symptoms include a 25 mmHg drop and moderate in between the above.

Duplex Criteria for Occlusive Disease/Graft Surveillance

% STENOSIS	PEAK SYSTOLIC VELOCITY (PSV)	VELOCITY RATIO (VR)	WAVEFORM
Normal	<150 cm/sec	<1.5	Triphasic
30–49%	150–200 cm/sec	1.5–2.0	Tri/Biphasic
50–75%	200–300 cm/sec	2.0–3.9	Bi/Monophasic
> 75%	>300 cm/sec	> 4.0	Dampened

VR: V1 is PSV at stenosis and V2 within two diameter lengths proximal or distal V1/V2.

For surveillance: Angiogram and repair if PSV > 300 cm/sec, < 25 cm / sec or decrease in ABI > 0.15.

Follow-up protocol: Within one month of procedure. If normal, 6 months, 12 months, then annually; if abnormal recheck in 3 month intervals.



Management

All patients need risk factor modification — the leading cause of death in this population is related to cardiac causes. Patients should be counseled on smoking cessation.

- *Medical treatment for the atherosclerotic disease process should include:* Antiplatelet medications including ASPIRIN® (acetylsalicylic acid) daily. Angiotension converting enzyme inhibitors and statin therapy have been shown to improve survival. Additionally beta blockers should be included in their treatment regimen with proven reduction in perioperative morbidity.
- *Medical treatment also includes a walking program to improve symptoms of intermittent claudication.* A trial of PLETAL® (cilostazol) for 3–6 months in patients with claudication has been shown to improve/increase walking distances in nearly one-half of patients. PLETAL® (cilostazol) is contraindicated in patients with congestive heart failure.
- *Patients who fail exercise programs and PLETAL® (cilostazol) therapy can be considered for endovascular/surgical treatment.*

Interventions

Recommended treatment modality is based on TASC II classification. With continued innovation in endovascular therapy the proportion of patients treated with endovascular therapy compared to open surgery continues to expand. The TASC II guidelines expanded the subset of patients in which endovascular therapy is recommended compared to the original TASC guidelines. Individual patient specific risk factors for open surgery must be taken into account.

TASC Classification Treatment Recommendations

TASC A: Endovascular method with excellent results and should be treatment of choice.

TASC B: Endovascular method with good results and should be preferred treatment unless an open revascularization is required for another associated lesion in the same anatomic area.

TASC C: Open revascularization produce superior results compared to endovascular means and endovascular treatment should be reserved for patients at high risk for open repair.

TASC D: Endovascular methods do not yield good enough results to justify as primary treatment. Open repair is preferred.

This manual does not include all the information needed to use the drugs listed herein safely and effectively. See full prescribing information and any boxed warnings for these drugs.



AORTOILIAC DISEASE

Background

- Endovascular management is feasible with good durability for nearly all lesions except proximal aortic occlusion above the IMA. Infrarenal aortic occlusion is now the most common indication for surgical reconstruction in our practice.
- Reportedly $\frac{1}{2}$ of occlusions of the aorta will progress to the level of the renal arteries, and the other $\frac{1}{2}$ will occlude below the IMA and/or lumbar arteries and will keep the proximal infrarenal aorta patent.
- Leriche Syndrome Triad: buttock claudication, decreased femoral pulses, and impotence.
- Expected primary patency for interventions (stenting) in the aortoiliac segment has been reported to be 80% at five years with similar patency in both stenosis and occlusions.
- Chronic occlusions/long segment interventions and external iliac procedures are less favorable. Most aortic bifurcation lesions are managed with balloon expandable stents, and the rest of the iliac system with self-expanding stents.

TASC II classification of Aortoiliac disease:

- A:
 - Uni/Bilateral CIA stenosis
 - Uni/Bilateral < 3 cm EIA stenosis
- B:
 - < 3 cm stenosis of infrarenal aorta
 - Unilateral CIA occlusion
 - Unilateral stenosis >3 cm or occlusion of EIA not involving internal iliac or CFA
- C:
 - Bilateral CIA occlusion
 - Heavily calcified EIA occlusion
 - Bilateral EIA stenosis or Unilateral EIA occlusion extending into CFA or IIA
- D:
 - Infrarenal aortic occlusion
 - Unilateral CIA and EIA occlusion
 - Bilateral EIA occlusion
 - Iliac stenosis in patients needing open AAA repair
 - Diffuse aortoiliac artery occlusive disease



Preferred Treatment Algorithm for Endovascular Management of Aortoiliac Occlusive Disease

- The retrograde approach is most common—via femoral access, except in distal external iliac occlusive lesions which often require a contralateral approach.
- Cross occlusions with straight stiff hydrophilic wire and angled braided catheter for directional changes.
 - Wires from bilateral femoral access should **cross in the aorta** and have a typical appearance that must be recognized (see previous chapter for image).
- Confirm catheter is within the true lumen.
- Reentry catheters — after failure with simple techniques.
- Most aortic bifurcation lesions are managed with balloon expandable stents, and the rest of the iliac system with self-expanding stents.
- Long sheaths should be advanced across the lesion before a balloon-expandable stent (BES) is advanced. Once the stent is in place, the sheath is withdrawn and the stent can be deployed. This prevents the stent being *stripped off* during advancement across the lesion.

Aortic Stent Placement:

- *If there is significant distal aortic stenosis, then consider: “Top Hat”* with hand-mounted PALMAZ® GENESIS Stent (Cordis Corporation, Bridgewater, NJ) on 10 mm balloon or consider large self-expanding stent after adjunct angioplasty.
- *Mounting technique:* Use 4x4 soaked in contrast and remove all hydrophilic material from the balloon. Let the balloon dry then place stent in center of balloon and roll slowly crimping stent on the balloon until stent secured in place (fingers should hurt by the time you’ve finished!) Then advance into sheath (must use introducer to prevent stent being stripped by the diaphragm of sheath.) Once past the lesion, withdraw the sheath and deploy the stent as close to the bifurcation as safely possible. Be careful not to let the “shoulder” of the balloon inflate in the iliac artery which can cause iliac rupture or deployment of stent in the iliac artery. Gain access of contralateral iliac artery and slightly raise aortic bifurcation with balloon expandable stents into distal aortic stent. Use self-expanding stents in external iliac arteries since more flexible.



Surgical Interventions

Pre-op — considerations

Typically reserved for failed endovascular interventions or TASC D lesions.

Cadillac is ABF: Best operation for fit patients.

Extra-anatomic reserved for poor risk and patients with hostile abdomen.

- Know history of previous abdominal surgeries, radiation, etc.
- Check bilateral brachial blood pressure, if difference > 20 mmHg, use extremity with best pressure for proximal anastomosis.

1. Aortobifemoral bypass: patency rate exceeds 80% at five years.

- The gold standard operation for aortoiliac disease. No difference in patency based on conduit used (PTFE vs. Dacron).
- Predictors of poor long-term outcomes of ABF:
 - Aorta < 1.8 cm, < 50 years old
- Technique
 - Midline incision.
 - Eviscerate to right.
 - Open retroperitoneum in midline preserving tissue adjacent to duodenum.
- **Dissection:** Renal vein-aortic bifurcation.
- Proximal anastomosis for aortic reconstruction in patients treated for occlusive disease:
 - **End to end:** Better hemodynamics, potential less risk of duodenal erosion.
 - **End to side:** In cases that either the IMA is patent, or there is severe external iliac disease/occlusions — in order to preserve pelvic blood flow.
- The distal anastomosis should be placed over patent vessel: i.e. the profunda or SFA.
- **Tunnel below ureters:** Must identify
 - Must identify circumflex iliac vein “vein of sorrow” under inguinal ligament prior to tunneling.

2. Axillobifemoral bypass: five-year primary patency of 50–80%

- For patients who are at higher risk for surgical reconstruction extra-anatomic reconstructions have been used with variable success. Also, the classic reconstruction in patients with infected aortic grafts *prior to explants*.



- Equivalent patency in patients with SFA occlusion.
 - Superior results when used for claudication in contrast to tissue loss.
 - Technical aspects of axillary incision:
 - Transverse incision two fingerbreaths below clavicle near midclavicular line. Open clavi-pectoral fascia. Open along fibers of pectoralis major. Either divide pectoralis minor or use first portion of axillary artery. Counter incision anterior axillary line. Tunnel subcutaneous to femoral region. Can either use:
 - Presewn axillobifemoral graft.
 - Single 8 mm ringed graft to ipsilateral femoral artery with fem-fem bypass.
 - **Caution: Sewing to third portion (lateral to pectoralis minor)—reported axillary disruption.**
- 3. Femoral-femoral bypass: five-year primary patency of 60% with up to 80% secondary patency.**
- Performed most frequently in patients with unilateral iliac occlusion (with failed endovascular attempt) and minimal disease in the ipsilateral iliac. Also in patients with AUJ, or in patients with single limb of ABF occluded. Steal of the donor extremity is rare unless inflow lesion present.
 - Most common mode of failure is inflow progressive stenosis.
- 4. Ileo-femoral bypass: retroperitoneal incision to ipsilateral iliac artery.**
- Benefits of single groin incision, limited data suggest improved patency compared to fem-fem bpg.



INFRAINGUINAL DISEASE

TASC II Classification of Femoral-Popliteal Disease

- A
 - Single stenosis <10 cm or occlusion < 5 cm
- B
 - Multiple < 5 cm stenosis/occ.
 - Single < 15 cm stenosis/occ. not involving the infragen. pop artery
 - Heavily calcified < 5 cm occlusion
 - Single popliteal stenosis
- C
 - Multiple stenosis/occ. > 15 cm
 - Recurrent stenosis/occ after two endo interventions
- D
 - CTO of CFA or SFA > 20 cm involving the pop art
 - CTO of pop artery and proximal trifurcation

Site Specific Management

CFA/profunda: Endovascular intervention discouraged.

- Common femoral endarterectomy is procedure of choice but rarely as a sole procedure, except in high risk cases in which the PPCI predicts improvement with this inflow intervention only — such as rest pain, or in patients with isolated common femoral disease.

SFA stenosis/occlusion: PTA +/- stenting for TASC II A-B lesions have similar short-term results compared to that of surgical reconstruction and is now considered the intervention of choice. For TASC-D lesions, surgical intervention is considered the first line therapy (common femoral occlusion or popliteal occlusion involving the trifurcation). For TASC-C lesions that reconstitute at the adductor canal femoral to above-knee popliteal bypass can be performed. We have preferentially performed PTA and stenting for lesions that are restricted to the SFA and above-knee popliteal artery. Symptomatic failures of this technique are offered below-knee reconstructions.

- Several well executed studies have been performed comparing the conduit of choice for above the knee reconstructions: similar results for vein and PTFE above the knee < 2 years. Some advocate routine use of PTFE in hopes of reserving the saphenous vein for subsequent below-knee popliteal bypass.



Infrapopliteal disease: Saphenous vein bypass is the gold standard with primary assisted patency — 75% at 5 years. All other conduits have been shown to have dramatic inferiority to saphenous vein. Arm vein, which often requires spliced segments, has been shown with duplex surveillance and secondary procedures to have patency rates superior to reports with prosthetic infrapopliteal bypass (primary assisted patency) in some series.

- Prosthetic infrapopliteal bypass is reserved for patients with tissue loss who lack saphenous vein conduit, or in cases where arm vein harvest is prohibitive secondary to renal insufficiency, or added length of procedure. Tibial bypass has similar patency reported in literature to that of infrapopliteal reconstructions when saphenous vein is used.
- Although patency rates are satisfactory with below-knee and tibial artery bypass, with saphenous vein the morbidity with these procedures can be significant including: myocardial infarction, wound-related complications, long hospitalizations, transfusion related complications, etc. In high risk patient populations, endovascular interventions often can achieve wound healing with significantly less morbid outcomes.
- Several studies have shown promising results with endovascular procedures for limb salvage including the results of the LACI trial with laser atherectomy and BK chill study with cryo-based angioplasty — resulting in > 80% limb salvage in both studies.

Follow-up surveillance: There is no level 1 evidence to support routine graft surveillance after prosthetic bypass. However, our group has routinely performed and acted on detected inflow and outflow stenosis similar to autologous reconstructions.

- **For prosthetic bypass grafts:** Same follow-up guidelines and duplex criteria as autologous bypass grafting with follow-up at 30 days, 6 months, and annually.
- **Femoral-femoral:** A midgraft velocity < 60 cm/sec and inflow or anastomotic velocity > 300 cm/sec which predicts a high risk for failure and should undergo additional imaging.
- **Femoral-popliteal (AK and BK):** < 45 cm/sec is at high risk for sudden graft failure and should have additional imaging.
- **Axillofemoral bypass:** Midgraft velocity < 85 cm/sec is predictive of failure.



Benefits of Procedures

Improvement in leg pain, limb salvage.

Complications

- Death — #1 cause is cardiac.
- **Infection:** Up to 10% of groin incisions become infected.
- **Lymphocele:** Can become infected, treated with drainage and ligation of lymphatic leak point +/- vacuum dressing/muscle flap.
- **Leg swelling:** Present in nearly 1/2 of patients.
- **Graft failure:** Early graft failure high association with limb loss / technical error.
- **Limb loss:** Usually secondary to graft failure.
- **Nerve injury:** Common to have paresthesia of leg (saphenous nerve injury).

Post-Operative Care

1. **Cardiovascular medicines:** Antiplatelet, statin, B-Blocker.
2. **Anticoagulation:** Dextran 40 at 25 cc/hr routine after infrainguinal reconstructions for 24 hours. High risk bypasses consider heparin drip as bridge to oral anticoagulation. Long-term plan based individually. All patients need to be dc'd with antiplatelet agents, consider dual antiplatelet therapy (clopidogrel and asa) or warfarin for high risk reconstructions. Dual antiplatelet therapy (clopidogrel and asa) for 4–6 weeks after endovascular PAD procedures.
3. **Assess for bleeding, compartment syndrome — reperfusion, and intervention success (i.e. pulse exam.)**
4. **Infectious complications:**
 - **Incisional** — stop antibx. ≤ 24 hours routinely, unless treating infection: i.e. foot infection
 - **Non-incisional** — UTI: D/C foley, pneumonia: incentive spirometry
5. **Access complications—after percutaneous procedures**

This manual does not include all the information needed to use the drugs listed herein safely and effectively. See full prescribing information and any boxed warnings for these drugs.



Pearls of Chronic Critical Limb Ischemia

- The highest predictor of need for combined inflow and outflow procedure is tissue loss.
- Autogenous conduit is recommend for infrainguinal reconstructions, even fem-ak pop in patients with expected survival *more than 2 years*.
- **Early graft failure < 3 months:** Technical issues.
- **Late graft failure > 3 months–2 years:** Most commonly secondary to intimal hyperplasia.
- **Absolute claudication distance:** Distance patient can no longer walk on treadmill — best measure to compare pharmaceutical and intervention procedures.
- **ABI:** Best predictor of survival in population based studies.

ACUTE LIMB ISCHEMIA

Background

- Embolectomy was first successfully performed in 1911. The most notable change occurred in 1963 when Fogarty, *et al.*, performed an embolectomy with a balloon catheter.
- Unlike the presentation of those with chronic critical limb ischemia, patients presenting with acute ischemia require emergent attention.
- 30-day limb loss is up to 30%.

History

- Present typically with abrupt onset of pain in the involved extremity.
- **Symptoms:** How long have symptoms been present?
- **Cardiac:** A fib, history MI.
- **Vascular:** Risk factors for PAD?, Chronic PAD history? History of aneurysms?
- **Etiologies:**
 - Thrombosis/embolization
 - Dissections, phlegmasia, trauma, compartment syndrome



Physical Examination

Exam: The five P's:

- **Pain:** Discomfort of the extremity.
- **Pallor:** Pale discoloration of the involved extremity.
- **Pulselessness:** May have Doppler signal.
- **Paresthesia:** Decreased sensation.
- **Poikylothermia:** Cool to touch.

Etiology: Source: Embolic events most commonly originate from the heart, 80% of which are secondary to atrial fibrillation, or recent MI causing mural thrombosis. Other less frequent causes include arterial to arterial embolus or paradoxical embolus.

- Thrombosis most frequently occurs in patients with previous interventions and sometimes occurs secondary to a hypercoagulable state such as heparin-induced thrombocytopenia or other inherent causes.

Embolic events originating from the heart most typically embolize to:

- Common femoral artery — 30–35%
 - Can present with palpable femoral pulse — water-hammer characteristic.
- Aortoiliac — 20–25%, saddle embolus: bilateral ischemia
- Popliteal — 15%
- Brachial — 10%, usually left upper extremity

Operative Technique

Brachial:

- Left Brachial most commonly affected.
- "S" type incision across antecubital fossa with takedown of the tendon from aponeurosis. Find the bifurcation of the radial and ulnar arteries with individual embolectomy after transverse arteriotomy.
- Perform completion arteriography if palpable pulses are not appreciated after embolectomy.

Femoral:

- **Vertical vs. transverse skin incision and isolation of CFA, DFA, SFA.**
 - **Suspected thrombosis:** Longitudinal arteriotomy.
 - **Suspected embolism:** Transverse arteriotomy.



Tibial:

- Below-knee popliteal incision, two fingerbreaths inferior to tibial tuberosity. Dissection down to popliteal fossa, then extend the incision inferiorly with takedown of the soleus muscle. The anterior tibial vein crosses over the proximal anterior tibial artery prior to its entry into the interosseus membrane. Isolate the tibioperoneal trunk and anterior tibial artery with an arteriotomy just above the anterior tibial artery.

Fogarty catheter: Will inflate in mm to approximately 2x the number of the fogarty: i.e. #3 dilates to diameter of approximately 6 mm.

- Color and location typically used for embolectomy
 - White 5: Iliacs
 - Red 4: Femoropopliteal/brachial
 - Green 3: Tibials/radial ulnar

SVS: CATEGORIES FOR ACUTE LIMB ISCHEMIA

Category	Description	
I	Doppler arterial and venous signal present but acute symptoms with pain, normal sensory and motor.	Viable
Ila	No Doppler arterial signal present, positive venous signal and reduced sensation, intact motor function.	Marginally threatened
IIb	No Doppler arterial signal, venous doppler signal present. Reduced sensory and motor function.	Immediately threatened
III	No Doppler signal in artery or vein—no sensory or motor, non-viable—Tx. Amputation: revascularization can result in cardiac arrest secondary to release of toxins from ischemic tissue.	Irreversible



ATHEROEMBOLI (BLUE TOE SYNDROME)

Background

Microscopic, cholesterol laden debris from a proximal source. Typically found in patients with palpable pulses. Source is typically from aneurysm, cardiac embolism, or severe atherosclerosis of the aorta or inflow arteries. If the embolic debris is larger, then can cause more of an acute ischemia pattern than a blue toe picture.

History and Physical Examination

- Can be spontaneous or after catheter manipulation.
- Evaluate for aneurysm or asymmetry in pulse examination.
- Typically is very painful.

Medical treatment includes: Antiplatelet agents (often dual therapy) and statins. Warfarin has been reported to cause intraplaque hemorrhage and is contraindicated. It is recommended in cases of ≥ 4 mm mobile aortic arch plaque that is symptomatic.

Intervention

Intra-arterial stent placement has been used to stabilize the plaque, however traditional treatment has been either endarterectomy or ligation and bypass.



"If at first you don't succeed, try, try again."

Edward Hickson, "Moral Song"

*"If at first you don't succeed, you're running
about average."*

Marion Hamilton Anderson



CHAPTER 10

DIALYSIS ACCESS

Stephen M. Hass

1966: Brescia and associates described first arteriovenous access — radiocephalic arteriovenous fistula at the wrist

DIALYSIS OUTCOME QUALITY INITIATIVE (DOQI)

- Fistula FIRST.
- Non-dominant arm used first.
- Radiocephalic AVF first choice.
- Brachiocephalic AVF second choice.
- Transposition brachiobasilic AVF third choice.
- Forearm loop AVG next.
- Upper arm brachioaxillary AVG last choice.
- Once non-dominant arm exhausted, use dominant arm.
- Tunneled catheters are a TEMPORARY access measure ONLY, and should be placed in the jugular vein.
- Only use subclavian vein for tunneled catheter access when you have exhausted use of the peripheral veins in that extremity.
- Some surgeons prefer forearm loop AVG prior to brachiobasilic AVF, as the graft does not preclude brachiobasilic AVF creation at a later time, and the forearm loop AVG may promote dilation of the basilic vein for later use.
- Referral for dialysis access creation should be made when $\text{GFR} < 25 \text{ ml/min}$ and expected dialysis within one year.

Key History

- Previous access procedures, AICD, previous central vein catheters, CHF, previous arm or neck surgery.



Examination

- Scars from previous access, catheters, chest wall collaterals, examination of veins with tourniquet.
- Blood pressures should be checked bilaterally — if > 20 mm Hg difference, concern for inflow disease.
- Palpation of brachial and radial/ulnar arteries; if non-palpable, then check with continuous wave Doppler.
- Allen test — evaluates for possible radial artery dominance; concern for wrist fistula if + exam.

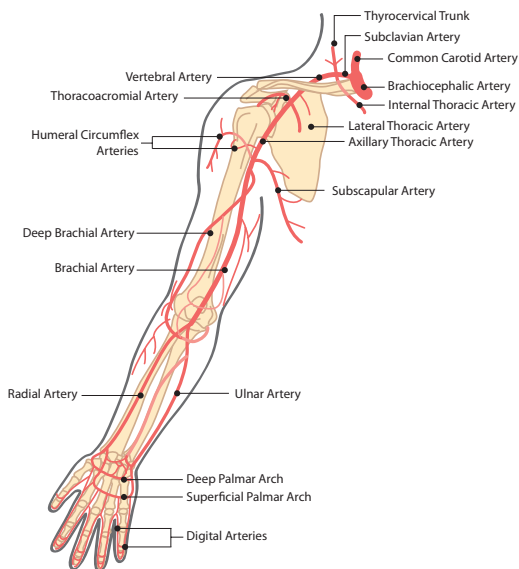
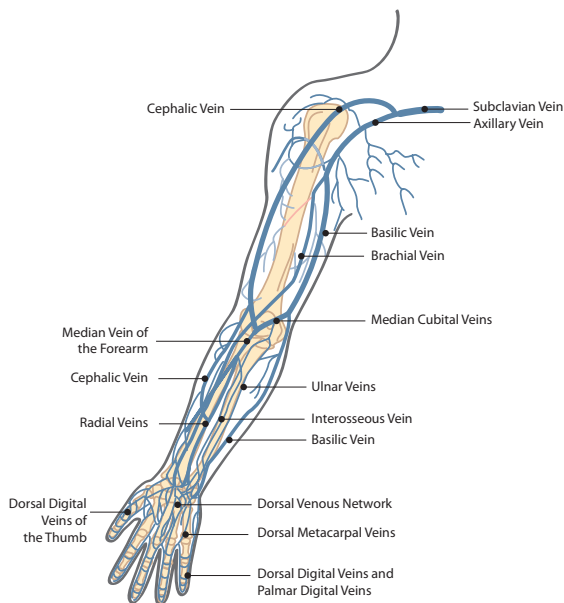
Non-Invasive Evaluation

- Vein mapping used to assess the size of veins and to check central veins for stenosis/occlusion.
- Evaluates arteries for size and potential arterial inflow disease, with blood pressure measurements, arterial waveforms and velocities.
- Non-invasive evaluation should routinely be repeated by surgeon at time of creation in the OR, as sedation or anesthesia can markedly dilate veins.
- Preferred anatomic and physiologic measurements:
 - > 2 mm transverse arterial diameter with minimal calcification
 - > 2.5 mm venous segment with continuity needed (> 15 cm)
 - Brachial artery blood pressure difference should be < 20 mmHg
 - No outflow disease: < 30 mmHg difference between ipsilateral brachial and third digit pressure
 - Patent palmar arch
- Venogram necessary prior to creation of AV access when:
 - Edema in extremity
 - Chest wall or arm collateral veins
 - History of catheter on side of planned access
 - Multiple previous access procedures
 - AICD or pacemaker placement

ANATOMY OF UPPER EXTREMITY VEINS

Cephalic vein:

- Lateral to the radial artery and courses up the lateral forearm on the flexor side.
- At the elbow, it joins the basilic vein (which takes similar course with ulnar artery), to form the median cubital vein.





- Cephalic vein courses up the anterolateral portion of the arm superficially and terminates in the deltopectoral groove as it joins the axillary vein.

Basilic vein:

- Courses posteromedially up the arm below the fascia to join the brachial veins to begin the axillary vein.

Central veins:

- Once the cephalic vein joins the axillary vein, it becomes the subclavian vein.
- Subclavian vein joins the internal jugular vein to become the innominate vein.

Techniques

Radiocephalic fistula (Brescia-Cimino)

- One-third do not mature; **patency and long-term function best of all fistulas.**
- Incision made between radial artery and cephalic vein (longitudinal incision).

Brachiocephalic fistula (Kaufmann)

- Transverse incision at antecubital fossa.
- Cephalic vein transposed medially to create end-to-side anastomosis with brachial artery.

Transposition brachiobasilic fistula

- Can be done as a one or two stage procedure.
- **One stage:** Entire basilic vein dissected and transposed anterior to the bicep muscle, either by flap creation or by subcutaneous tunneling.
- **Two stage:** First stage is the arteriovenous anastomosis, usually distal to the antecubital fossa, followed by the second stage, which is transposition anterior to the bicep muscle usually by flap creation.
- Some feel the two stage procedure is beneficial, as it avoids a more complex dissection and transposition operation should the vein fail to mature, or if prohibitive steal develops.

Forearm loop AV graft:

- Arterial anastomosis is at brachial artery just distal to antecubital fossa.
- Venous anastomosis can be cephalic vein, basilic vein, or an antecubital vein.



- Small incision made at apex in lower forearm as counterincision for loop arm tunneling.
- *Important to dictate anatomy and direction of flow of each limb (venous limb, arterial limb) in operative report to aid with thrombectomy at a later time.*

Brachioaxillary AV graft:

- Two small incisions along medial aspect of arm — one for brachial artery exposure, and one for distal basilic/axillary vein exposure.
- Graft then tunneled in subcutaneous tissues in a curvilinear path, anterior to the bicep muscle.
- Venous anastomosis to distal basilic vein acceptable if dimensions permit, as it preserves deep vein patency and limits morbidity of high axillary dissection.

Postoperative Evaluation

- Arteriovenous fistula or graft should have palpable thrill or audible bruit.
- If access pulsatile, then outflow stenosis is a concern (unidentified central venous or distal vein stenosis, twisting or kinking of access in subcutaneous tunnel).
- Radial/ulnar arteries should have audible Doppler signals or, preferably, palpable pulses at completion of procedure; diminished pulses warrant close postoperative clinical evaluation and finger pressure measurements bilaterally to evaluate for potential steal syndrome.
- Autogenous arteriovenous fistulas typically require 12–16 weeks for maturation.
- Autogenous fistula maturation typically evaluated by the “Rule of 6’s”:
 - Flow of 600 cc/minute
 - Diameter over 6 mm
 - Depth < 6 mm
 - Cannulation length of 6 inches
- If quick maturation or aneurysmal dilation develops, suspect that central vein stenosis is causing high venous pressure.
- Grafts are accessible in 2–3 weeks.
- Newer materials (i.e. VECTRA® Vascular Access Graft, Thoratec Corporation, Pleasanton, CA) can be accessed within 24–48 hours of implantation.



- Follow-up in two weeks for incision check and access evaluation.
- Fistulas need follow-up every 6–8 weeks for access evaluation and maturation surveillance. Any abnormalities (pulsatility, diminished thrill or bruit, etc.) warrant further investigation with non-invasive methods or venography.

Results

FISTULA/PATENCY	6 MONTHS	18 MONTHS
All autogenous, primary	70%	50%
All autogenous, secondary	85%	75%
All ePTFE, primary	60%	30%
All ePTFE, secondary	75%	55%

Complications

Thrombosis:

- Most common complication.
- Technical if occurs early (< 30 days).
- Over 90% of late thrombotic episodes are related to venous outflow issues.

Infection: Less than 5% of grafts become infected; an infected graft typically requires graft removal, which can be partial, subtotal, or total, depending upon organism involved, amount of graft, location of graft involvement (i.e. anastomosis versus isolated midportion of access), and overall condition of patient (i.e. sepsis versus local wound infection).

Edema:

- Secondary to poor venous outflow.
- If persists longer than two weeks, plan venogram — repair of outflow stenosis or ligation of access is the treatment.

Failure to mature (autogenous arteriovenous fistula):

- Up to 1/3 of wrist fistulas, < 15% of basilic transpositions.
- Poor inflow, poor vein quality, or excessive outflow due to large vein tributaries.
- Multiple venous branches — perform open ligation or endovascular coil embolization.
- Arterial/venous stenosis — perform percutaneous transluminal angioplasty/stenting or open patch angioplasty.



- Mid-vein abnormality—likely secondary to valve or chronic venous disease; perform percutaneous transluminal angioplasty / stenting or open repair with patch angioplasty or interposition repair.

Steal syndrome:

- Arterial steal occurs in 2–8% of patients.
- Higher frequency in diabetics and more *proximal* access.
- Assessment with finger pressures and clinical examination.
- Typically, digital pressures of < 50 mmHg will have rest pain or some manifestation of symptoms.
- Compare with contralateral extremity and assess finger pressures with and without AV access compression.
- If no significant change with access compression, then likely distal disease; if significant change with AV access compression, then likely steal.

Grade 1: Mild (cool extremity with few symptoms)

2: Moderate (symptoms with dialysis)

3: Severe (ischemic rest pain or tissue loss)

Access pseudoaneurysms:

- Secondary to repeated punctures at same site.
- Interposition repair is standard treatment, but covered stents are used frequently now.

Management of Complications

Malfunctioning AV access:

- Could be due to central stenosis, venous stenosis, arterial stenosis, or intra-vein or intra-graft stenosis.
- For prosthetic access:
 - 55% venous anastomosis
 - 30% long segment venous outflow stenoses or occlusions
- For autogenous vein access:
 - Frequently occur at the arterial anastomosis or within the proximal few centimeters
- May present as a pulsatile access, high-pressure outflow measurements during dialysis, poor inflow pressure measurements during dialysis, or prolonged bleeding after needle removal.



Treatment is either endovascular or open repair:

- Endovascular: Percutaneous balloon angioplasty or stent placement.
 - Haskal, *et al.* — prospective study finding stent graft superior to balloon angioplasty for AV graft venous anastomosis stenosis
- Open repair: Jump graft repair, interposition repair, or patch angioplasty.

Thrombosed AV access:

- Thrombosed fistula often not salvageable probable more success with open thrombectomy.
- For thrombosed AV grafts, four prospective randomized trials comparing surgical vs. endovascular techniques; contemporary series show equivalent results in three month patency with both methods.
- Range from 25–75% with DOQI goal of 50% at 3 months.
- Goal is to achieve intra-graft pressure < 40% of compressed graft pressure (systemic pressure).

Endovascular management of thrombosed AV graft:

- Forearm graft
 - Access via mid forearm limb section with sheaths placed toward apex of graft.
 - Venous outflow treated with percutaneous rheolytic thrombectomy of venous outflow followed by PTA of venous anastomosis if needed.
 - Arterial inflow treated with thrombectomy of arterial limb with over-the-wire Fogarty balloon catheter to remove arterial plug.
 - Identify etiology of failure and treat with PTA and/or stenting
 - Most common cause is stenosis at venous anastomosis.
 - Strongly consider placement of endovascular stent graft for treatment of the venous anastomosis if not across the elbow joint since patency proven superior to PTA.
- Brachioaxillary graft:
 - Access antegrade above antecubital fossa
 - Treatment of venous outflow, similar to forearm graft
 - Access retrograde at graft close to axilla
 - Treatment of arterial inflow, similar to forearm graft

Surgical management of thrombosed AV graft:

- Cutdown at apex of graft or at venous anastomosis.
- Thrombectomy of graft; intraoperative fistulogram.



- Address etiology of failure; can attempt by endovascular means intraoperatively with C-arm (PTA and/or stenting) or open technique (patch angioplasty, graft revision).

Steal syndrome corrective actions:

- Banding or tapering of graft or vein — plication.
- Distal Revascularization Interval Ligation (DRIL) procedure.
- Revision Using Distal Inflow (RUDI) procedure.
- Ligation and abandonment of AV access.

DIALYSIS CATHETERS

- Used as a TEMPORARY access measure. Used preferably when dialysis necessary before autogenous AV fistula has matured.
- Studies have demonstrated increased morbidity and mortality with central venous catheters compared to arteriovenous fistula.
- Internal jugular vein preferred. Subclavian vein to be used ONLY when all access options have been exhausted in the upper extremity.
- Pre-curved catheters allow tunneling along anterior chest into internal jugular vein with less kinking or twisting of the catheter along the subcutaneous path.
- Malfunctioning catheters can be replaced by endovascular means over a stiff wire if the catheter has been in place long enough to have a well-defined subcutaneous tract.
- Many times, however, the catheter will develop a “pseudosheath” around the portion in the venous lumen — simply replacing the catheter over a wire will reintroduce the new catheter into the “pseudosheath” — therefore, balloon angioplasty is required to disrupt the pseudosheath prior to reinserting a new catheter.



*"I have not failed. I've just found 10,000
ways that won't work."*

Thomas Alva Edison



CHAPTER 11

CENTRAL VENOUS ACCESS

Stephen M. Hass

- The most common procedure performed by housestaff and medical students.
- After 50 successful access placements complications steadily decrease, i.e. learning curve.

INDICATIONS

Hemodialysis, chemotherapy, total parenteral nutrition, exhausted peripheral access, long-term access for antibiotics, large-bore access for trauma patients requiring rapid infusions, access to allow for Swan-Ganz catheters.

History

Previous catheters, AICD/pacemakers, lung resection (access side of previous lung resection), COPD/emphysema, chronic renal insufficiency or impending dialysis needs (important to avoid subclavian access).

Labs

- *CBC, PT,PTT, INR*: Elevated coagulation panels and low platelet counts place patients at risk for bleeding complication, especially non-compressible vessels (subclavian).



Sites

Jugular, subclavian, femoral veins

- For emergency access and in patients with coagulopathy, femoral site preferred, as it avoids risk of pneumothorax and allows for better direct pressure should hematoma occur.
- In obese patients, the neck landmarks are often distorted and femoral access cumbersome—subclavian vein is often easier to access.
- If patients with severe COPD: jugular site is preferred, as it is believed that pneumothorax rates lower with internal jugular access as compared to subclavian access; for previous AICD placement, internal jugular vein access avoids competition for access with pacer wires/leads (which are usually placed via subclavian route).

HEMODIALYSIS TUNNELED CATHETER

- Direct ultrasound imaging during cannulation is now becoming standard. 5–8 mHz array transducer allows for best imaging of vascular structures.
- We prefer a lateral approach to the jugular vein with access at the base of the neck with the ultrasound probe in transverse orientation just superior to the clavicle. **RIGHT INTERNAL JUGULAR VEIN IS THE PREFERRED INITIAL SITE.**
- 0.035" wire introduced through access needle into central venous system — passage into IVC preferred for stability and to avoid cardiac arrhythmias due to wire coiling within atrium/ventricle.
- Predilation of skin and subcutaneous tissues with rigid dilators **MUST** be done under direct fluoroscopic guidance to avoid kinking of wire and aberrant passage of dilator tip through the wall of the central veins.
- Counter incision made medial to nipple line and 5–7.5 cm inferior to clavicle.
- Catheter tunneled in subcutaneous tissue (over the clavical for internal jugular approach), exiting at the point of the guidewire insertion.



- Peel-away sheath is placed and the catheter is advanced through it into the central veins. The sheath is then removed by peeling the sheath apart, it is important to not let the catheter slip backward out of the sheath when the sheath is removed.
- The catheter tip should be placed at the level of the SVC/right atrial junction or into the right atrium to ensure there is optimal blood flow. If the catheter is placed in the right atrium, then it should be made of a soft compliant material (i.e. silicone).
- Tunneled catheter lengths are measured from cuff to tip.
 - Right internal jugular/subclavian vein—19–23 cm length usually adequate.
 - Left internal jugular/subclavian vein—23–28 cm length usually adequate.
- Although the femoral vein is an alternative access to the subclavian vein, iliofemoral vein thrombosis and femoral vein catheter infection can be prohibitively high.

Landmarks

Internal jugular vein access:

- Posterolateral approach:
 - Entrance just above clavicle and posterolateral to sternocleidomastoid muscle.
- Anterior approach:
 - Identify two heads of sternocleidomastoid and puncture at apex of two heads with needle pointed at ipsilateral nipple.

Subclavian vein access:

- Landmark: lateral $\frac{2}{3}$ of clavicle, with needle passed under clavicle and pointed toward sternal notch. The more lateral the puncture, higher the risk of arterial puncture.

Femoral vein access:

- Vein is medial to artery and about one fingerbreadth lateral to the edge of the symphysis pubis bone—ultrasound access preferred to landmark technique.
- If possible, place tip of catheter in inferior vena cava to improve catheter patency rates and functionality.



Complications

- Pneumo/hemothorax ($< 2\%$). *Chest X-ray for assessment in all patients post procedure.*
- Catheter thrombosis
- Catheter-induced venous thrombosis
- Local and systemic infection.
- Air embolism (mill wheel murmur, place patient in trendelenburg, right side up, and aspirate).
- Arterial cannulation:
 - ***Current recommended treatment for carotid artery cannulation:***
For > 7 Fr sheath diameter, treatment requires open surgical removal; otherwise, remove and provide direct pressure.
 - ***For subclavian artery cannulation:*** Endovascular management by brachial or femoral access, with balloon inflation to tamponade arterial puncture site after sheath removal; closure devices have also been successful; covered stent is also a viable emergency option.



“The critical part of this operation is what I call the fine tuning, the meticulous removal of the loose fragments after removing the plaque.”

Ali F. AbuRahma, MD



CHAPTER 12

CAROTID ARTERY OCCLUSIVE DISEASE

Ali F. AbuRahma

KEY FACTS

- Stroke is the third leading cause of death in the US.
- Surgical treatment (CEA) has historically been considered superior to medically treated patients for stenosis exceeding 50% with symptoms and > 60% without symptoms.
- Up to one-half of patients report having TIA symptoms prior to stroke, with the remaining having stroke as the initial symptom.
- **Asymptomatic:** Incidental finding or after imaging for carotid bruit (most common reason for detecting carotid stenosis).
- **Symptomatic:** For 4–6 months, after a neurologic event. Then reclassified as asymptomatic.
 - **TIA:** Transient ischemic attack.
 - **Stroke:** Cerebral infarction, may have permanent deficits or complete resolution of symptom complex with only imaging evidence of infarction of brain tissue.
- **Amaurosis fugax:** Transient monocular blindness: described as “shade pulling down over eye.”
- **Hemispheric:** Classic distribution of symptoms; contralateral arm and/or leg symptoms (motor or sensory deficit). Left hemispheric symptoms classically can have aphasia or dysphagia in addition to extremity symptoms.
- **Nonhemispheric:** Non-lateralizing symptoms or posterior circulation symptoms.



Physical Examination

Palpation of carotid artery to appreciate pulsation, and auscultate for bruit. One-third rule — one-third transmitted bruit (e.g. heart), one-third mild carotid stenosis, and one-third significant carotid stenosis.

Diastolic component of bruit typically found with severe stenosis > 70%.

Diagnosis/Imaging

Ultrasound: First line assessment and only assessment in the majority of institutions that use ICAVL accredited laboratories.

Duplex criteria: Refer to non-invasive imaging.

For surveillance of carotid artery stenosis $\geq 50\%$ to $< 80\%$ stenosis should undergo duplex imaging every 6 to 12 months.

MRA: Meta-analysis of contrast-enhanced MRA has a higher sensitivity and specificity than duplex ultrasound—limitations in renal insufficiency patients and costs.

CTA: Newest technology, including 3-D reconstruction, very accurate, possibly more so than conventional angiography, decreased accuracy in calcific plaques.

Angiography: 1% risk of neurologic event with diagnostic arteriography (Asymptomatic Carotid Atherosclerosis Study [ACAS] and North American Symptomatic Carotid Endarterectomy Trial [NASCET]).

Technique for Diagnostic Carotid and Cerebral Angiography

Femoral access:

- Insertion of 5 Fr sheath, then pigtail catheter placed just above aortic valve.

Typical injection rates for the aortic arch are:

- 15 cc/sec for 30 cc (total volume) or 20 cc/sec for 40 cc. The intensifier should be positioned in LAO to profile the arch. Identify arch type: 1, 2, and 3. Then perform selective angiography with catheter selection based on arch type. *RAO projection used to profile the right common carotid artery. Passive and intermediate catheters can usually be used to successfully cannulate vessels in a Type 1 and Type 2 arch.



Type 3 arch often requires the use of SIMMONS Catheter:

- The SIMMONS Catheter is an aggressive catheter and may increase the risk of atheroembolic complications. The catheter is categorized as an active catheter and it must be "formed". This is best accomplished by inserting it into the subclavian artery over the wire until the secondary curve is approaching the subclavian origin. The wire is then withdrawn to the secondary curve and the catheter is advanced and rotated allowing it to form.

Selective injections can be performed with hand injection or with power injection:

- Typically AP, lateral, and ipsilateral oblique to best profile stenosis or spin.
- NASCET (North American Symptomatic Carotid Endarterectomy Trial) method is used to determine degree of stenosis.
- Measure stenosis diameter of internal carotid artery and subtract this distance by the normal distal ICA diameter and then divide by normal distal ICA diameter.
 - Residual luminal diameter of stenotic lesion (mm) divided by the normal luminal ICA diameter distal to the lesion.

Intervention Recommended

> 50% symptomatic

> 60% asymptomatic: however most use ≥ 70 –80% stenosis.

Surgery is the first line of therapy—CEA, stenting for high risk patients.

Surgery for Carotid Artery Occlusive Disease

Informed Consent

Risks: Stroke, hematoma, cranial nerve injury, MI, site infx.

Benefits/Alternatives: Prevent future neurologic events, continued medical tx.

Technique

Carotid Endarterectomy (CEA): Single most frequent non-access procedure performed at Charleston Area Medical Center (CAMC), currently performing over 400 annually.

This manual does not include all the information needed to use the drugs listed herein safely and effectively. See full prescribing information and any boxed warnings for these drugs.



- *Dextran* 40 at 20–25 cc/hr at time of incision x 24 hours.
- *Skin incision:* Transverse along skin lines or classic incision along anterior border of the sternocleidomastoid muscle (SCM). Carotid bifurcation generally at thyroid cartilage.

Dissection:

- Pull sternocleidomastoid muscle laterally to prevent dissection into central neck.
- Vagus nerve located between jugular vein and carotid artery.
- Facial vein typical landmark over carotid bifurcation.
- Hypoglossal nerve 1–2 cm above carotid bifurcation.
- Right angle test: palpate artery over right angle to make sure there is no plaque at location of distal clamp.
- Endarterectomy between inner and outer media, start proximal then move distally.
- Tack any loose intima with U stitches.

Management of arteriotomy:

- Patch angioplasty — ? ideal patch vs. eversion.
 - Prospective randomized trials have shown decreased perioperative strokes, carotid thrombosis, and recurrent stenosis with patching when compared to primary closure.
- Multiple prospective randomized trials at our institution comparing patch types comparing patch types demonstrated no significant differences in perioperative stroke/death.
- Re-establish flow to the external carotid, common carotid, internal carotid (in that sequence).

Techniques to identify which patients need intra-arterial shunt:

< 10% of patients need shunted and < 50% of those with contralateral occlusion need a shunt. Methods to determine selective shunting:

1. Awake: If neurologic symptoms develop on clamping — shunt.
2. EEG: Presence of delta waves on clamping — shunt.
3. Stump pressure: Systolic > 40 mmHg should not be shunted.
4. TCD and cerebral oximetry: Not as frequently used as other techniques.

Intraoperative imaging: Not universally performed, some data suggest duplex to detect intraoperative defects, gold standard has been angiography.



Postoperative Complications

1. Most common is hypertension/hypotension: Medical management.
Hypertension—Increases hematoma frequency.
2. Expanding hematoma: Requires emergent re-exploration, symptoms may include dysphagia, difficulty breathing, and stridor.
3. Neurologic deficit in operating room: re-explore to rule out carotid thrombosis. If in recovery room, may get stat CT or duplex, and if abnormal the patient should be explored urgently.
4. Cranial nerve injury occurs in up to 15% with most resolving within six months.
 - Dysphagia (vagal nerve), paresthesia in the marginal mandibular branch of the facial nerve distribution, hoarseness (recurrent laryngeal nerve).
5. Myocardial infarction (MI) — up to 1–2% of patients.
6. Death (< 1%).
7. Combined stroke/MI/death should be less than 3% in asymptomatic patients and < 5% in symptomatic patients.

CAROTID ARTERY STENTING

Current group of patients considered high risk that is currently eligible for carotid stent procedures:

Currently at our institution: We perform 400 carotid endarterectomy (CEA) procedures and 40 carotid artery stents (CAS) annually.

2012 Medicare coverage includes only high risk **symptomatic** patients with > 70% carotid stenosis.

High Risk Classification

Anatomic:

- Stenosis at C2 or higher, ostial stenosis, or below the clavicle.
- Contralateral recurrent laryngeal nerve injury, previous neck irradiation, tracheostomy.
- Recurrent carotid artery stenosis.
- Contralateral occlusion.

Physiologic:

- **CHF:** EF < 30%
- **Severe COPD**
- **> 80 years:** Also increased risk with stenting.



Technical issues with carotid stenting:

- **MUST BE on antiplatelet regimen, i.e. Clopidogril prior to procedure.**
- *Arch:* Increased complexity with more tortuous arches, i.e. type III
- Symptomatic patients are at highest risk for neurologic events.
- Gain access to common carotid artery (CCA) with either telescoping technique or use external carotid artery for anchoring technique.
- *Image:* Carotid bifurcation and intracranial circulation
- The lesion is then crossed with the wire and the filter is deployed in the distal internal carotid artery. A self-expanding stent is then deployed and post-dilated. Significant brachyarrhythmias can develop and atropine may need to be given. Pre- and post-intracerebral imaging should always be performed.
- Flow reversal can be used as alternate embolic protection device.

Controversial Areas

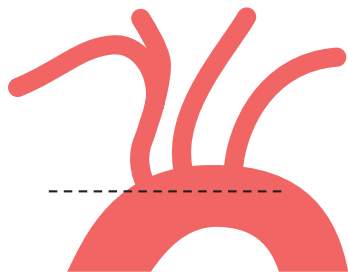
CABG and CEA: If both symptomatic, then simultaneous procedures.

If only one symptomatic, typically perform that procedure first in staged manner.

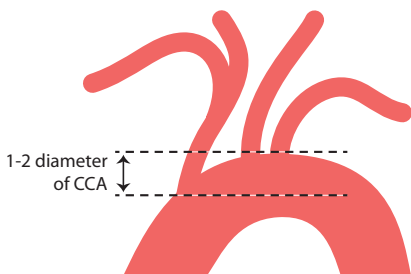
Protamine and CEA: Some data suggest decreased hematoma rate with no increased stroke, others report increased stroke risk.



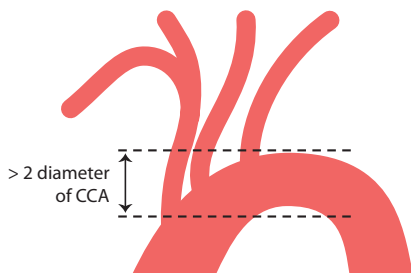
Aortic Types



Type I



Type II



Type III



CHAPTER 13

BRACHIOCEPHALIC DISEASE

Saadi Alhalbouni

OVERVIEW**Brachiocephalic Disease**

- The origins of the aortic arch great vessels rarely require intervention when compared to extracranial carotid arteries.
- < 20% of patients have more than 30% stenosis of the innominate or subclavian arteries with concomitant severe ICA disease

ANATOMY

- Most commonly, the great vessels (innominate, left common carotid, and left subclavian arteries) arise from the aortic arch separately.
- 5% — “*bovine*” *arch*: Common origin of left common carotid/innominate artery, or left common carotid artery arises from the innominate artery.

PATHOLOGY

- **Atherosclerotic**: The most frequent indication for intervention (80%). Nearly 100% of patients have a history of smoking.
- **Non-atherosclerotic**: Takayasu, dissection, aneurysmal degeneration, prior radiation.

PRESENTATION

Asymptomatic: Asymmetric blood pressure during examination or incidental finding on imaging looking for other pathology.



- **Symptomatic:**
 - Atheroembolic complications: TIA, stroke, limb ischemia, digital ulcerations
 - Claudication or vertebrobasilar insufficiency
- **Most are asymptomatic:** < 10% require re-vascularization

WORK-UP

History

- TIA, stroke, amaurosis fugax
- History of sternotomy? CAD
- History of vasculitis

ROS

- **Vertebrobasilar insufficiency:** Vertigo, ataxia, binocular visual symptoms, and drop attacks.
- **Vertebral-subclavian steal:** Vertebrobasilar insufficiency symptoms with upper extremity activity.
- **Coronary-subclavian steal:** Coronary symptoms with upper extremity activity in patients with CABG using LIMA.
- **Upper extremity ischemia/ Claudication:** Diminished or asymmetric pulses, limb fatigue and pain with use.

PE

- **Neurologic exam:** Neurological deficits, previous stroke.
- **Complete pulse exam:** Carotids, brachial and radial/ulnar.
- **Hand exam:** For signs of embolic lesions.
- **Brachial pressure:** Difference between the two upper extremities > 20 mmHg is significant.

IMAGING

- **Duplex:**
 - **Innominate/CCA lesions:** Dampened common carotid waveform with low velocities < 50 cm/sec
 - **Innominate or subclavian lesions:** Flow reversal in the vertebral arteries
- **CTA/MRA:** Both require contrast, CT limited with calcific lesions.
- **Angiography:** Gold standard — also ability to offer intervention simultaneously.



INFORMED CONSENT

Expected risks of procedures: Access complications, surgical site infection, bypass occlusion, stroke, nerve injury.

Benefits: Reduce risk of stroke, improve blood flow to the arm, improve dizziness of VBI symptoms present.

INDICATIONS FOR TREATMENT

- No prospective randomized trials comparing medical, endovascular, and surgical treatment modalities.
- *Asymptomatic:* $\geq 80\%$ stenosis.
- *Symptomatic:* $\geq 50\%$ stenosis.

Treatment

- **Endovascular:**
 - *PTA and stenting:* $>70\%$ 5 year patency
- **Open:**
 - *Direct reconstruction:* i.e. Innominate endarterectomy, aorta-carotid bypass: $> 80\%$ 10 year patency
 - *Indirect reconstruction:* Carotid-carotid, carotid subclavian bypass: $> 80\%$ 5 year patency

ENDOVASCULAR TIPS

- Usually preferred for older patients with higher operative risk.
- Femoral or retrograde brachial for subclavian interventions.
- Proximal common carotid artery — use filter when using femoral approach with guide catheter.
- Liberal stenting of patients with asymptomatic subclavian steal diagnosed by Duplex is discouraged.
- Endovascular interventions discouraged — heavily calcified, ulcerative lesions, or disease extending to vert. art.



OPEN PEARLS/TIPS

- Clamping of the brachiocephalic arteries generally does not require shunting.
 - Direct transthoracic approach via a median sternotomy, or cervical approach
 - Consider preop cardiac cath if median sternotomy planned for combined coronary reconstruction.
- Bypass options include subclavian-carotid (preferably ipsilateral) or carotid-carotid bypass.
 - Transposition of carotid to subclavian or vice versa have the advantage of one anastomosis and no prosthetic material
- Must identify Phrenic nerve for subclavian reconstructions.
- Transpositions typically more technically demanding.
- For thromboembolic lesions, ligate artery proximally to eliminate embolic source.
- Carotid-carotid: Retropharyngeal—shorter distance vs subQ tunnel.
- Improved patency of C-S bypass compared to ax-ax bypass.

POSTOPERATIVE CONSIDERATIONS

Endovascular: Access complications, neuro deficits, asymmetry of B.P., limb ischemia, hematoma.

Open: Neuro deficits, CN injury, hematomas, cardiopulm (MI, resp distress), thoracic duct injury, phrenic nerve injury.



“ If MRSA is our number one bug for vascular surgical site infections why are we not using prophylaxis against it? ”

Dennis Bandyk, MD



CHAPTER 14

VASCULAR SURGICAL SITE INFECTION

Patrick A. Stone

BACKGROUND

Incidence depends on surgical site: < 1% with neck incisions, < 3% of aortic surgery, up to 10% of groin incisions.

Host is most common source of contamination.

Prevention: Optimal OR conditions:

- Warm patient, preoperative antibiotics, clipping, supplemental oxygen, blood sugar control, perfect wound closure.

Risk factors: Reoperative surgery, ongoing infection in affected limb, groin incision, preprocedural hospital stay, emergency surgery.

CLASSIFICATION

Temporal relationship:

Early < 4 months

Late > 4 months

Location

Intracavitary: Abdomen/chest

Extra/cavitary: i.e. groin

Classification of Early Vascular Site Infection

Szilagyi:

1. Cellulitis only.
2. Dermal infection.
3. Frank purulence around graft.



Bacteriology

- Most common infection isolated is gram positive organism—up to 50% of cases.
- Most common bacteria isolated in early infections — **MRSA**.
- Most common bacteria isolated from late infections — #1 **Staph. Epidermidis**, #2 **MRSA**.
 - Classic late presentation of groin infection is draining sinus.
- 10–15% gram negative organisms.
- Classic microbe associated with anastamotic disruption — **Pseudomonas**.

Presentation

- *Wound infection*: Erythema and drainage from surgical site. Groin incision highest risk.
- *Bleeding*: *Most suspect infection if recent surgery*
- *GI Bleeding*: if previous aortic reconstruction must consider aorto-enteric fistula.
- *Aneurysm formation*: i.e. patch pseudoaneurysm with carotid infection.
- *Bacteremia*: More typical of intracavitary infections—fever, leukocytosis, malaise, weight loss.
- *Septic emboli*: Roth spots in extremity with bypass.

Evaluation

- *Blood cultures*: **Bacteremia requires total graft explantation. Patient is not a candidate for graft preservation.**
- *Ultrasound*: Fluid around graft with clinical signs and symptoms of infection.
 - Also image to identify alternative conduit, i.e. lower extremity or upper extremity vein.
 - Baseline ABL and determination of patency of conduit.
- *Computed Tomography*: Most sensitive/reliable
 - Perigraft fluid, often with stranding signifying inflammation.
 - Perigraft air (should be resolved normally by 3 months), focal bowel thickening, hydronephrosis.

Treatment

Graft removal with replacement of autologous tissue is gold standard treatment. Also, explanting the graft with extranatomic reconstruction is acceptable as first line treatment.



- Intravenous antibiotics: culture specific is given for 6 weeks.
- Lifetime antibiotics in patients with unacceptable risks of explantation for suppressive therapy in select cases.

Other scenarios/options:

- **Infection limited to groin:** If gram positive and early infection, consider local treatment with I and D, antibiotic beads, and possible muscle flap.
 - If gram negative infection, or entire graft is infected, then autologous replacement or extra-anatomic reconstruction (i.e. obturator bypass).
- **Infected limb of ABF:** Retroperitoneal incision with intraoperative culture, if negative then can remove limb only, if infected at midlimb then requires total graft explant.
- **Aortic infection:** Graft removal and axillobifemoral bypass (if stable, revascularization first then graft removal in 24–48 hours), or in-situ cryo-preserved aorta, or deep venous replacement (NIAS Procedure). Mortality as high as 50%.
- **Carotid patch infection:** Incidence < 1%. Treatment should be to remove patch and perform vein patch angioplasty, or may require interposition vein graft if large section of artery debrided.

Antibiotic Bead Algorithm

1. Operative exploration of groin infection.

- Culture tissue/fluid adjacent to conduit.
- Pulsatile irrigation and Brown Volcano irrigation (½ H₂O₂, ½ Betadine).
- Based on culture results PMMA bead placement, i.e. if gram + (vancomycin), gram – (gentamycin).
- Close wound, or place wound vac over skin.

2. Return to operating room in 3–5 days for second debridement and washout.

- Initial culture taken then irrigation and local debridement.
- If stat gram stain is negative, consider definitive treatment, i.e. graft preservation with or without muscle flap depending on soft tissue defect.
- If culture is positive replace with culture specific antibiotic beads and plan third procedure.

3. If vascular surgical site cannot be sterilized on third exploration, then partial graft removal is required with either extranatomic reconstruction or in-situ autologous procedure.

This manual does not include all the information needed to use the drugs listed herein safely and effectively. See full prescribing information and any boxed warnings for these drugs.



CHAPTER 15

RENAL ARTERY OCCLUSIVE DISEASE

John E. Campbell and Mark C. Bates

Renal artery stenosis is the most common cause of secondary hypertension and is a known etiology of ischemic nephropathy with subsequent chronic kidney disease.

TWO TYPES

1. Atherosclerotic renal artery stenosis (ARAS) — 90%
 - Usually involves ostium or proximal segment
 - Generally becomes symptomatic in later decades of life (> 50 years)
 - Can cause renovascular mediated hypertension and ischemic nephropathy
2. Fibromuscular dysplasia — 10%
 - Usually involves the mid or distal segment of the artery
 - Generally becomes symptomatic in early decades of life (late teens to early 30s)
 - Usually not associated with ischemic nephropathy

Pathophysiology

- Goldblatt performed seminal experiment in 1934 developing the 2-kidney 1-clip model and 1-kidney 1-clip model.
- Renal occlusion or stenosis creates ischemia which then triggers increased production of renin. Renin promotes the conversion of angiotensin I to angiotensin II, which promotes aldosterone release. Aldosterone increases sodium and water retention.
 - *2-kidney 1-clip model (unilateral renal artery stenosis)*: There is pressure diuresis of the non-stenotic kidney which prevents a volume component to the hypertension.
 - *1-kidney 1-clip model (bilateral renal artery stenosis and solitary kidney)*: Diuresis is compromised and volume-mediated hypertension occurs.



Epidemiology

- Key at risk group is patients with end-stage renal disease.
 - Prevalence up to 40% when screened!

INDICATIONS FOR INTERVENTION

- Well-accepted indications:
 - Hemodynamically significant RAS with recurrent unexplained pulmonary edema (Class I, LOE B).
 - RAS with:
 - Accelerated, resistant (not controlled on 3 anti-hypertensives), or malignant hypertension
 - Hypertension with unilateral small kidney
 - Hypertension with medication intolerance (Class IIa, LOE B)
 - RAS and CKD with bilateral RAS or RAS of a solitary functioning kidney (Class IIa, LOE B).
 - RAS in patient with unstable angina (Class IIa, LOE B).

Less accepted indications that should be performed with detailed conversation of risks and benefits with patient or consider treating with medical therapy:

- Asymptomatic bilateral or solitary viable kidney with hemodynamically significant RAS (Class IIb, LOE C).
- Asymptomatic unilateral hemodynamically significant RAS in a viable kidney (Class IIb, LOE C).
- Unilateral RAS and CKD (Class IIb, LOE C).
- Anatomic indications:
 - $\geq 70\%$ visualized stenosis
 - 10 mmHg mean gradient or 20 mmHg peak systolic gradient

Diagnosis

1. **Renal artery duplex:** Should be first imaging modality and for subsequent follow-up.
 - Exam limited in obese patients and patients must be kept NPO prior to test to reduce bowel gas.



CLASSIFICATION	RENAL AORTIC RATIO (RAR)	PEAK SYSTOLIC VELOCITY (PSV)	POST STENOTIC TURBULENCE (PS)
< 60% stenosis	< 3.5	< 180 cm/s	Absent
> 60% stenosis	> 3.5	> 180 cm/s	Present
Occlusion	NA	NA Absence of flow Low amplitude parenchymal signal	NA

2. **CTA:** Can be very helpful (sensitivity and specificity > 90%), especially with 3-D reconstruction; however many patients with ARAS have CKD and CTA carries with it a risk of contrast induced nephropathy.
3. **MRA:** In patients with normal renal function can be useful (sensitivity $\geq 90\%$, specificity $\sim 90\%$); however cannot use gadolinium in patients with CKD secondary to risk of nephrogenic systemic fibrosis.
 - *Important:* Cannot use MRA if previously placed renal stent secondary to signal drop out, the artery appears occluded.
4. **Renal angiogram:** Gold standard for diagnosis but carries with it the risk of the invasive procedure and contrast nephropathy. Tips for diagnostic angiogram:
 - Always use hemodynamic monitoring at catheter tip to prevent injection of saline or contrast into soft plaque or thrombus.
 - Best oblique for imaging both the left and right renal artery ostium in most patients is the left anterior oblique (LAO), while an ipsilateral oblique is best to image the mid and distal segment of the artery.
 - In most cases, diagnostic angiography should be able to be performed with ≤ 15 ml of contrast. As stated earlier, many patients have CKD who need renal angiography and casual use of contrast with frequent “puffing” will have a detrimental effect on patient outcomes. It is our practice to only perform flush abdominal angiography on patients with difficult cannulation of the renal arteries or if a “hostile” aorta is discovered. However, we perform continuous hemodynamic monitoring of the catheter tip with a pressure inducer to avoid atheroembolism.



TREATMENT

Renal Artery Stenting

Has become the treatment of choice for renal artery stenosis

- **Technique:** Either the no-touch technique or telescoping technique should be used on all interventions to avoid atheroembolism caused by the guide catheter during attempted access of the renal artery. Guide catheters have a large internal diameter (ID) and there is a high potential for “snow plowing” of plaque if proper technique is not used! If clinically significant atheroembolism takes place, then renal function declines over a period of 3–8 weeks (except in cases of massive atheroembolism where acute renal failure can be seen). Since the majority of patients are discharged the next day from the hospital, most operators will not see the decline in renal function until the patient follows-up weeks later. Unfortunately, this is usually blamed on the patient’s other medical comorbidities and the operator never learns from their mistakes!
 - **No-touch technique:** The technique is usually performed with a 6 Fr system and the guide of choice for the interventionalist (at our institution this is usually a Bates 1 or 2 guide.) The guide is advanced over a moderate support wire that has a good transition in the distal segment (i.e. SUPRACORE® Wire, Abbott Vascular, Redwood City, CA) and next a .014" wire (i.e. SPARTACORE® Wire, Abbott Vascular, Redwood City, CA) with both a short transition at the tip and high degree of support is advanced to the proximal segment of the catheter. Next, the .035" wire is withdrawn to let the guide catheter take shape leaving at least 3 cm of wire projecting from the guide to keep it from scraping the wall of the aorta. Next, the .014" wire is advanced into the renal artery and the .035" wire is removed. At this point the guide should fall into place at the ostium and PTA/stenting can be performed.



- **Telescoping technique:** This technique can be used to treat de novo renal artery stenosis but is especially useful for renal artery in-stent stenosis since it will prevent the wire from advancing through stent struts that are projecting into the aorta. Again, most of the time this can be performed with a 6 Fr system. A diagnostic catheter (JR4, IM, etc.) is advanced through the guide of choice and secured with the tuohy borst. The renal artery is selected and the .014" wire is advanced into the renal artery. The guide is then advanced over the diagnostic catheter to the ostium of the renal artery. The diagnostic catheter is then "walked off" the wire while leaving the guide in place. At this point the operator can proceed with PTA/stenting of the renal artery.
- We have found that intravascular ultrasound (.014" catheter) is very helpful to accurately size the stent.
 - *It is important to size the stent to the "normal segment" of the renal artery and not to the post-stenotic dilatation.*
- A brachial approach can be used if the renal artery is highly tortuous or has a severe inferior angulation. This can be performed with a 6 Fr system and usually a multipurpose guide is most useful. Alternatively, a MORPH® Guide Catheter (Bio Cardio, San Carlos, CA) can be used from a femoral approach for added support.

Renal Artery Bypass

Was the treatment of choice for many years, but secondary to the morbidity and mortality of the procedure, is now usually reserved for patients who have failed endovascular therapy.

- Perioperative mortality of ~ 10% by Medicare database, though much lower in high volume centers (< 5%)
- Excellent long-term patency, up to > 90% at 8 years
- **Renal artery bypass:**
 - **Conduits:** Autologous saphenous vein, autologous hypogastric artery, and synthetic graft
 - Always use autologous tissue if possible
 - Bypass can originate from aorta, hepatic, splenic, or iliac artery



RENAL ARTERY STENT OUTCOMES

- A meta-analysis of three randomized controlled trials demonstrated that balloon angioplasty of the renal artery was superior to medical therapy for the treatment of moderate to severe renal artery stenosis.⁴³ There are multiple retrospective studies that demonstrate the benefit of renal artery stenting; however, there is a paucity of randomized data. There have been two recent randomized trials:
 1. **STAR Trial**¹⁵— 140 patients randomized to medical therapy with or without stenting. Primary endpoint of 20% or greater decrease in creatinine clearance.
 - No difference found in the treatment groups.
 - Flaws in study:
 - 50% stenosis was used as inclusion criteria.
 - More than half the patients had unilateral RAS.
 - Randomization based on intention-to-treat model with severity of stenosis based on MRA, CTA, and angiography. Twelve of 64 patients in the stent group had < 50% stenosis and did not receive a stent.
 - High complication rates (4% mortality from renal perforation, 17% hematoma rate, renal artery injury in 10% of patients).
 2. **ASTRAL Trial**¹⁶— 806 patients randomized to medical therapy with or without stenting
 - Inclusion criteria:
 - Physicians had to be uncertain which treatment was appropriate—stenting with medical therapy or stenting alone.
 - > 50% stenosis of the renal artery.
 - Demonstrated no difference in outcomes in the two groups in blood pressure response or renal function.
 - Bottom line — if the operator is not sure if a patient should have a renal intervention, then the patient should be treated with medical therapy. Patients with weak indications don't benefit from renal artery stenting.



- General approximate numbers to remember for outcomes after renal artery stenting:
 - Two-thirds of all patients will have improvement or cure of their hypertension after stenting, while one-third will have no improvement.
 - Three-fourths of all patients have stabilization or improvement of renal function and one-fourth of all patients will have worsening renal function after stenting.



CHAPTER 16

AMPUTATIONS

Patrick A. Stone

Over 300,000 amputations performed annually in United States. At CAMC, approximately 100 major amputations are performed annually. This is a significant cost to the health care system in terms of hospital and rehab charges. The majority of non-traumatic amputations are secondary to complications of diabetes mellitus.

RISK FACTORS FOR AMPUTATIONS

- Diabetes mellitus — 20x compared to non-diabetic
- Peripheral vascular disease

Preoperative Considerations

Healing potential: Overall nutritional status, immune status, as well as other conditions contributing to skin healing, (i.e. lymphedema and chronic venous changes).

Functional status: Patients non-ambulatory prior to amputation will still be non-ambulatory after the amputation and this should factor into level of amputation.

Risk of anesthesia: Most patients can have regional anesthetic if moderate- to high-risk with general anesthetic.

LEVEL OF AMPUTATION**Clinical Evaluation**

- Patients will generally heal below a palpable pulse, i.e. palpable popliteal pulse > 90% healing of BKA.
- Knee contractures > 30 degrees will often develop stump complications and poor healing secondary to pressure necrosis — AKA recommended.



- Severe edema and cellulitis of below-knee skin from severe lymphedema or venous stasis are unlikely to heal below knee.

Testing

- Ankle pressure > 50 mmHg will permit healing most BKAs.
- Toe pressure > 50 mmHg will permit healing with digital or foot amputations.
- Transcutaneous oxygen— considered by some to be best predictor of healing. TcO_2 > 20 mm Hg allow healing at tested area.

Preprocedural Counseling and Consent

1. Understand the expected mortality and functional outcomes.
2. Frequency of subsequent revisions.
3. Potential peri-operative complications unrelated to procedure.

Technical Issues

Toe/ray amputation

- Tennis racquet incision/preservation of all viable skin/resection of cartilage surface.
- Meticulous incision closure.

TMA

- Long posterior skin flap with transection of bones in midmetatarsal region 1 cm proximal to skin edge, fascial closure and nylon sutures for skin closure.

BKA

- Skin incision approximately 10 cm from tibial tuberosity with posterior based skin flap one-third the length of the circumference of the calf. Suture ligation of popliteal artery/vein separately, transect tibia at beveled angle 1 cm proximal to anterior skin edge, divide fibula 1 cm proximal to tibia, nerves cut sharply under tension and allowed to retract.
- Soleus resected and fascial closure with absorbable suture and skin closed with nylon suture.



AKA

- Fishmouth incision, bone will be divided at base of fishmouth, pursestring suture with PROLENE® Suture around femur to keep bone in midline, has tendency to abduct since adductor muscles are no longer functioning. Nerves should be sharply divided to limit neuroma formation, with fascial closure using absorbable suture and nylon suture for skin edges.

Hip disarticulation

- Rarely necessary, posterior based gluteus skin flap used to cover hip joint after cartilage surface removed, fascial closure with absorbable suture and nylon skin closure. Nearly 100% six month survival, usually when profunda acutely occluded and unreconstructable—consider comfort measures.

Other Issues

- Drains may increase infection rate but may reduce hematoma rate, a frequent cause of poor healing.
- Consider tourniquet in patients with normal blood supply to reduce blood loss, i.e. traumatic amputations.
- Complete vs. partial removal of failed prosthetic bypass at time of amputation, significantly decreased wound complication rate if complete removal.
- *Primary closure vs. delayed closure.*
- Myoplasty should be considered in patients with AKA who are likely to ambulate:
 - Adductor muscles are fixed to femur with nonabsorbable sutures and ant/post muscles also with drilled holes in femur with U type suture technique for both.

POSTOPERATIVE CARE

- Patient should be placed in intermediate care unit following procedure, since perioperative mortality exceeds that of distal revascularization procedures.
- Administer beta blocker unless contraindicated.
- DVT prophylaxis: second most common cause of death related to thromboembolic complications.
- *Cardioprotective meds:* ASA/Beta-blocker/Statin.

This manual does not include all the information needed to use the drugs listed herein safely and effectively. See full prescribing information and any boxed warnings for these drugs.



- **Antibiotics:** Length of therapy should be 24–48 hours unless ongoing infection at remote location.
- **Fluid management:** Careful attention since significant number of patients with reduced ventricular function.
- **Early mobilization:** Physical therapy and rehabilitation consult—helpful to have rehab. Team to see patient prior to the procedure for further amputation education.
- No weight bearing activity unless immediately casted or apops placed.

PERIOPERATIVE COMPLICATIONS

- Death should be < 5% following digit or foot amputations, expected mortality is up to 10/15% for BKA/AKA respectively.
 - Most common cause of mortality is cardiovascular related.
- **DVT/PE:** Patients at high risk with most series reporting thromboembolic complications as second leading cause of death.
- **Wound infection and nonhealing:** Depending on how aggressive attempts are at preserving the knee joint the frequency of this complication will vary. Typically quoted as 20% of BKA's and < 10% of AKAs requiring revision. Wound infection occurs up to 30% of patients with MRSA the leading cause of infection.
- **Non-surgical site infections:** Secondary to patients' reduction in mobility this cohort is at high risk for pneumonia, UTI from indwelling catheters and venous line related infections from prolonged hospitalizations.

Long-Term Functional Outcomes

- **10–20%** will subsequently undergo a contralateral amputation.
- Energy expenditure is not significantly increased in toe and foot amputations, however great toe amputations including the first metatarsal head may have considerable changes in balance.
 - Increase energy expenditure following BKA/AKA is 30%/60%.
- Expected ambulation with a prosthesis is up to 75% with BKA and 40% after AKA.

Long-Term Survival

- One-year survival is 50% and three-year survival is as low as 30%.



CHAPTER 17

MESENTERIC ISCHEMIA

Patrick A. Stone

CHRONIC MESENTERIC ISCHEMIA

- Splanchnic artery blood flow increases within an hour of eating which is mostly related to increase SMA flow. Hepatic artery flow is fairly constant in both the fed and fasting state. Increased flow is essential to allow absorption of nutrients. Mucosal integrity is maintained by approximately 30 ml/min/100 grams of tissue.
- Not uncommon to have documented mesenteric artery stenosis, i.e. incidental finding on computed tomography of abd./pelvis.
- 5–10% of population over 65 years of age.
- Classically, **two vessels** need to have severe disease in order to have symptoms.
- In patients with poor collateralization single vessel disease can also result in symptoms.
- Typical age at presentation is 50–70 years old.
- Not uncommon to get consults for patients with ischemic colitis which are found on CTA or MRA to have no ostial stenosis of the celiac or SMA and have either isolated IMA disease of small vessel/collateral issues.

Presentation

- *Postprandial abdominal pain is the most reliable clinical symptom.*
- “Intestinal angina” — with food fear, weight loss, and abdominal discomfort 10–15 minutes after eating, lasting 1–4 hours.
- Can also have intestinal ischemia without classic symptoms, however this is usually secondary to small vessel disease in IMA distribution.
- Most have had symptoms for several years and other diagnosis given. Not uncommon for patients to have undergone surgical intervention for other GI diagnosis (i.e. cholecystectomy).



Examination

Scaphoid abdomen, abdominal bruit $\frac{2}{3}$ of patients, often nontender and nondistended unless acute mesenteric ischemia.

Diagnosis

Visceral duplex: initial test of choice, body habitus limiting factor.

Need to be NPO prior to exam.

Duplex criteria:

- Celiac > 200 cm/sec: > 70% stenosis, EDV > 55 cm/sec: > 50% stenosis
 - Retrograde hepatic artery flow is nearly 100% predictive of critical celiac stenosis or occlusion.
- SMA > 275 cm/sec: > 70% stenosis, EDV > 45 cm/sec: > 50% stenosis

CTA: Best non-invasive study to evaluate the vessels and to evaluate for other causes of abdominal pain. Especially useful for pre-preprocedure planning.

- *Can determine supraceliac aorta characteristic with calcium burden:* Clamp site.
- *Degree of stenosis, and degree of calcification at vessel ostiums.*
- *Assess risk of atheroembolism during intervention:* i.e. presence of medial degeneration.

MRA: Limited use except in severe calcific disease.

Digital Subtraction Arteriography (DSA):

- Given the quality of CTA, DSA is now only used when planning endovascular intervention.

Views:

- **AP** — To identify collateral support and anatomy for variations. Should also assess for other pathology (ie. microaneurysms associated with vasculitis).
- **Lateral** — Best for viewing ostium and profiling aorta-ostial interface for optimal stent deployment.

ANATOMY

- Replaced right hepatic artery —10–15% of population.
- Collateral Circulation



- **Celiac to SMA:** Via gastroduodenal and pancreaticoduodenal arteries, pancreaticoduodenal arcade, middle colic and pancreaticoduodenal arcade.
- **SMA to IMA:** Branches of left and middle colic arteries via the arc of Riolan.
- **Hypogastrics to IMA:** Via the middle and inferior rectal arteries to the superior rectal arteries from the IMA.

Informed Consent

Risks:

- Death: up to 10% based on national data for open reconstructions. < 2% perioperative mortality with endovascular interventions.
- Complications associated with laparotomy: bowel obstruction / adhesions, etc.
- SIRS syndrome.
- Bowel infarction: embolization intraop.
- Recurrent ischemia: secondary to intervention failure/recurrent stenosis.

Recurrent stenosis: Higher with endovascular procedures.

Benefits: Able to eat without pain, weight gain.

Alternatives: Observation, endo, open.

Treatment

Endovascular: Decreased length of stay and peri-procedural morbidity and mortality.

- Femoral or brachial approach
 - Rapid exchange platforms with .014" wires, a high support wire is needed (i.e. SPARTACORE® Wire, Abbott Vascular, Redwood City, CA). These should be approached with a guide catheter using either a no-touch technique or a telescoping technique. Often, an 8 Fr guide is needed for added support when approaching from a femoral access.
 - **Balloon expandable stents preferred since ostial lesions in most:**
 - 50% develop restenosis and 50% of those patients develop recurrent symptoms.

Surgical reconstruction:

- Bowel prep preoperatively
- HIBICLENS® (chlorhexidine gluconate solution 4.0% w/v) shower
- NPO



Intraoperative Pearls/Technique

Antegrade: Aorta to celiac/SMA

- Takedown triangular ligament/crus of diaphragm.
- With nasogastric tube in place, identify esophagus and move to patient's left.
- Isolate supraceliac aorta for proximal anastomosis.
- Use bifurcated graft 16 x 8 mm, cut shaft short to prevent kinking of graft.
- SMA limb tunneled behind pancreas, celiac limb to hepatic artery.

Retrograde: Aorta or iliac artery as inflow artery:

Consideration in patients with previous upper abdominal surgery or for debranching procedures:

- Use lazy curve to reduce risk of graft kinking*
*higher incidence than antegrade recon.
- Ringed ePTFE.

ACUTE MESENTERIC ISCHEMIA

Etiology

1. **Embolic:** 30–50% of patients, typically — cardiac origin.
Up to 20% have other synchronous emboli with the SMA most susceptible secondary to its ostial angle, usually at junction of middle colic artery.
2. **Thrombotic:** Critical stenosis progressing to occlusion.
3. **Venous thrombosis:** 70% involve SMV, most commonly secondary to hypercoag. state, 3 year survival < 50%.
4. **Non-occlusive mesenteric ischemia (NOMI):** In critically ill patients usually secondary to low flow state, imaging demonstrates narrowing of multiple branches, mortality exceedingly high secondary to underlying conditions producing this.

History

Cardiac rhythm disturbances, history of previous embolic events, known or history of mesenteric ischemia, hypercoagulable condition, medication that can cause nonocclusive mesenteric ischemia (i.e. digitalis or pressors). Acute onset of symptoms.

This manual does not include all the information needed to use the drugs listed herein safely and effectively. See full prescribing information and any boxed warnings for these drugs.



Examination

- Pain out of proportion to examination.
- Abdominal examination with diffuse tenderness, when frank peritonitis present, grave prognosis.
- Can have heme positive stool.

Labs

- **CBC:** Frequent leukocytosis and left shift
- **BMP:** Fluid shifts with ARF common
- **Lactic acid:** Elevated

Imaging

- Ultrasound: usually not helpful secondary to bowel gas.
- CTA: quick and usually confirms presumptive diagnosis.
 - Thrombosis vs embolus
 - Pneumatosis late finding
 - MVT: "Bull's eye" sign
 - Eversion image
- Conventional DSA: often poor imaging due to bowel gas and requires intervention team.

Treatment

Endovascular:

Consider for diagnostic and possible transcatheter therapy:

Contraindicated in patients with peritonitis—to operating room.

Surgical intervention:

- Give anticoagulation to prevent propagation of thrombus.
- Abdominal exploration with examination of entire bowel.
- Mesentery evaluation with handheld Doppler.
- Classically an embolus stops at middle colic artery and proximal jejunum is spared, whereas a thrombus will result in ischemia as proximal as the duodenum.
- Dead bowel should be removed, marginal bowel can be inspected with woods lamp. Thrombectomy is performed via a retrograde approach of the SMA after isolation at the base of the mesentery. Small transverse arteriotomy used unless bypass intended.
- Second look in most to reevaluate the bowel.
- If bypass necessary, autologous tissue is recommended in 24–48 hours.



CHAPTER 18

THORACIC OUTLET SYNDROME (TOS)

Mohit Srivastava

BACKGROUND

- Symptoms are due to compression of neurovascular bundle at the thoracic outlet.
- Most procedures performed in US are for neurogenic (> 90%).
- **Incidence:** Up to 2%, 25–40 years old, female to male: 4:1.
 - Neurogenic (94–97%)
 - Venous (2–3%)
 - Arterial (1–2%)
- **Thoracic outlet:** Triangle is ant scalene, middle scalene, and first rib
 - Subclavian artery (SCA) passes behind ant scalene and arches over the first rib
 - Brachial plexus courses between anterior and middle scalene
 - Vein courses anterior to anterior scalene

Brachial Plexus (BP)

- C5 – T1
 - C5 – C6: upper — Post to SCA
 - C7: middle — Lateral to SCA
 - C8 – T1: lower — Superior to SCA (closest relationship to it)

Subclavian Vein (SVC)

- Does not transverse the triangle. Passes anterior to the insertion of the anterior scalene muscle on first rib.
- Inferior and lateral to the subclavius tendon.

All three (SCA, SCV, BP) pass underneath the clavicle, beneath the subclavius and pectoralis minor.



Other Pertinent Anatomical Structures

- **Phrenic nerve:** Anterior to anterior scalene muscle.
 - Passes lateral to medial (infero-medially).
 - 10–15% have a double phrenic nerve.
- **Long thoracic nerve:** Post to middle scalene, descends over the first rib.
- **Thoracic duct (left side)**

Three Main Spaces of Thoracic Outlet (TO) Responsible for Compression

- **Scalene triangle:** SCA and BP (most common site of compression).
- **Costoclavicular space:** All three (between clavicle and first rib).
- **Retropec minor space:** BP only (between coracoid process and ribs).

Etiology

- **Neurogenic:** Osseous changes, soft tissue abnormality, and trauma.
 - Osseous changes
 - Cervical rib — 1% (50% bilateral) — F > M, most are asymptomatic
 - Fibrous band that extends from the tip of the cervical rib and inserts on the first rib
- **Arterial:** Usually cervical rib and rudimentary first rib.
- **Venous:** Costoclavicular ligament and subclavius muscle compressing first rib.

PATHOLOGY

- **Neurogenic:** Insidious
 - Symptoms are usually exacerbated by increased arm activity and with elevation.
 - Paresthesias are usually nocturnal.
- **Lower Plexus:** Sensory disturbance in the ulnar nerve distribution.
 - Pain/paresthesias in medial arm.
 - Hypothenar, interosseus, deep flexor of the ring and middle finger.
 - Pain in shoulder radiating to the neck and occipital area.
- **Upper Plexus**
 - Mostly forearm and upper arm rather than the hand
 - Pain in the side of the neck and headache (occipital and orbital)
 - Sensory decreased to the median nerve
 - Lateral thenar muscles (can lead to “claw hand”)



THORACIC OUTLET SYNDROME

Muscular/Ligament

Scalene Anticus and
Medius Muscles
Pectoralis Minor Muscle and
Costocoracoid Ligament
Costoclavicular Membrane
Subclavius Muscle

Bone

Cervical Rib
First Rib Anomalies
Long Transverse Process
Clavicle Abnormalities

COMPRESSION

FIRST RIB

VASCULAR

Subclavian Vein

Edema
Venous Distension
Paget-Schroetter
Syndrome

Subclavian Artery

Loss of Pulse
Claudication
Thrombosis

NERVE

Sympathetic

Raynaud's
Phenomena

Peripheral

Pain
Paresthesia
Motor Weakness

Pain
Color and
Temperature Change
Ischemia
Trophic Change



VASCULAR

Examination

- Tenderness on scalene compression and sBP difference of 20 mmHg between arms.
- Auscultate just beneath the clavicle with the arm in a neutral position.
 - Then abduct and externally rotate while palpating the pulse and auscultating.
- Weakness of shoulder, biceps, triceps — upper plexus.
- Weakness of the intrinsic muscles of the hand — lower plexus.
- Tinel's sign.
 - Radiating tingling over the arm when tap on brachial plexus.
- Adson's sign.
 - Hold arm down and turn head to affected side, with cervical extension and inspiration.
 - Narrows triangle, causes decreased radial pulse.
- 90 degrees exterior rotation and abduction.
 - Can do hyperabduction and turn head away.
 - Radial pulse obliterated.
- Laboratory testing and imaging.
 - EPS usually negative — does not exclude TOS diagnosis.
 - Nerve Conduction Velocity
 - Normal sensory and decreased motor amplitude in median nerve.
 - Decreased sensory and decreased motor amplitude in Ulnar nerve.
 - Somatosensory Evoked Potential (SSEP)— decreased amplitude at ERB's point, median nerve normal.
 - Chest X-ray in all.
 - CT not conclusive, MRI a little better.
 - Arteriogram only with arterial involvement.
 - If concerned, do with arm in stressed and neutral position.
 - Venogram only with venous involvement. Should perform in stressed and neutral position.
- Provocative test.
 - Scalene muscle block — Positive test is > 50% improvement in the elevated arm stress pain score.



- **Differential diagnosis.**
 - Cervical stenosis.
 - Cubital tunnel syndrome (ulnar entrapment at elbow)—tingling pain in the ulnar distribution; can have medial forearm numbness—TOS (medial antebrachial cutaneous, lower blood pressure)?
 - Carpal tunnel syndrome — PURE median nerve distribution.
 - Sensory distribution of the first three fingers.
 - Symptoms originate in hand and radiate up arm.
 - Rotator cuff injury.
 - Complex Regional Pain Syndrome (RSD, causalgia).
 - Dysfunction of central and peripheral nerves (s/p trauma).

Treatment

- **Conservative:** Education, modify activities, no forward flexed positions, exercises, and NSAIDS.
- **Operative intervention:**
 - Failure of conservative, significant work disability, vascular type.

Surgical Approaches

1. **Transaxillary rib resection with scalenectomy**
 - First rib resection done for lower trunk symptoms.
 - Some advocate this approach first if neurogenic.
 - Any upper trunk symptoms — need supraclavicular approach as well.
 - *Advantages:* Rapid exposure of first rib, cosmetic.
 - *Disadvantages:* Exposure difficult, injury to Ax vein and T1 nerve root.
2. **Supraclavicular approach**
 - Still take first rib along with anterior scalene muscle (as above).
 - *Advantage:* Excellent view, cervical rib easily removed.
 - *Disadvantage:* Nerve injury risk.
3. **Infraclavicular approach**
 - Best exposure for venous variant.
4. **Combined**
 - Lateral decub for transaxillary and move to supine for supraclavicular approach.
 - Once first rib is gone—anterior and middle scalenectomy performed.



5. *Posterior*

- Posterior scapular resection.
- Only for previously radiated.

Venous Paget-Schroetter Disease

- Axillo-SCV is most common site of venous pathology.
- Subclavius tendon is usually the site of compression.
- Treatment is thrombolysis and anticoag with first rib resection later.
 - If longstanding, stenosis may require angioplasty or surgical patch angioplasty.

Arterial

- *Earliest lesion—simple stenosis.*
- BONY ABNL is number one cause.
- *Treatment: Manage ischemia, decompression, repair arterial defect, consider dorsal sympathectomy.*
 - Thrombolysis/thrombectomy can be done after angiogram.
 - Depends on clinical stage of ischemia.
 - Decompression can be done later, if thrombolysis chosen.
 - If aneurysm or poststenotic > 2 cm —resect and replace with GSV or prosthetic graft with an approach above and below the clavicle.

Postoperative Complications

- PTX (pneumothorax) — < 10%
 - Most common complication.
 - Check chest X-ray post op.
- Nerve injury (temporary or permanent).
 - More common in lower trunk distribution than upper trunk (lower usually permanent).
 - Long thoracic nerve can be injured with middle scalenectomy—winged scapula.
 - Intercostobrachial nerve—under second rib.
 - Numbness on medial aspect of the arm.
- Lymphatic leak — injury to thoracic duct — occurs in supraclavicular approach on left side.
 - Ligate if leak intraop.



Results of Decompression for Neurogenic TOS

- Primary — 50% significant improvement at 18 months, 30–40% at 72 months.
- Secondary — higher.

NO DIFFERENCE BETWEEN APPROACHES

- Active range of motion exercise pre-op — minimizes scarring post-op.
- MOST SIG variable is cause of TOS.
- If additional repetitive stress was present preoperatively — poorer outcome.



CHAPTER 19

VENOUS DISEASE

Albeir Y. Mousa and Patrick A. Stone

BACKGROUND

- Venous disease is the most common diagnosis seen by most vascular specialists.
- Care for venous diseases constitute 2% of total health care expenses in US.
- Up to 20% of adult male and two-thirds of adult females have varicose veins.

Classification

REVISED CEAP CLASSIFICATION OF VENOUS DISORDERS	
C	CLINICAL FINDINGS
C ₀	no visible venous disease
C ₁	telangiectatic = 1 mm "spider veins" or reticular veins = 1–3 mm
C ₂	varicose veins: > 3 mm
C ₃	edema
C ₄	skin changes without ulceration: (lipodermatosclerosis)
C ₅	skin changes with healed ulceration
C ₆	skin changes with active ulceration
E	ETIOLOGY
"c"/"p"/"s"	congenital/primary/secondary disease



REVISED CEAP CLASSIFICATION OF VENOUS DISORDERS	
A	ANATOMIC FINDINGS
Superficial veins (As)	Telangiectasias or reticular veins
	Great saphenous vein—above the knee/below knee
	Small saphenous vein or non-saphenous
Deep veins (Ad)	Named deep system veins
Perforating veins (Ap)	Thigh or calf
P	PATHOPHYSIOLOGIC COMPONENT
	"r"/"o"/reflux/obstruction / both

Pathogenesis:

Hormonal, genetics

History and Physical Examination

Common complaints include: Pain, aching, burning, and heaviness. Other complaints include swelling of the leg or foot with or without skin changes. Dermatitis or lipodermatosclerosis (LDS), ulceration, bleeding or unsightly appearance are also frequent complaints.

Diagnostic evaluation:

- Hand-held continuous wave Doppler examination for reflux sites in both great and short saphenous vein.
- **Duplex examination:** Identifies specific sites of reflux/reflux time. ≥ 0.5 sec = significant.
- Ascending/descending venography used in cases of equivocal duplex examination.

Intervention

1. **Compression:** Support hose are indicated in all patients with symptomatic disease.
 - 20–30 mm Hg minimum, 30–40 and 40–50 mm also available for more severe disease.
2. **Microphlebectomy:** For large varicosities.
3. **Ligation and stripping:** Surgical removal of varicose vein from groin to knee or ankle, seldom performed with less-invasive treatment options.

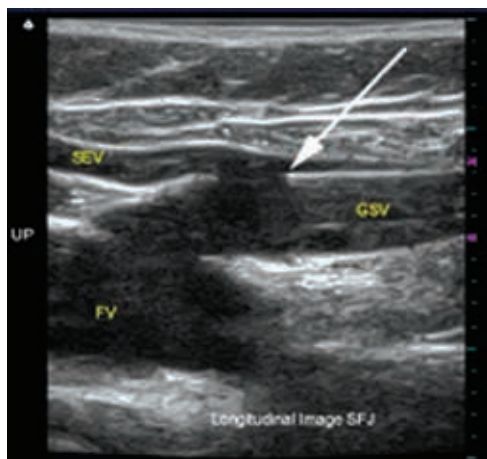


4. **Endovascular venous ablation of superficial veins:** Is evolving as the most common venous procedure performed.

Key steps to this procedure are to get access and to identify saphenofemoral junction under ultrasound duplex examination in both transverse and longitudinal views.

Technique

- Ultrasound assisted puncture of GSV near knee.
- After access catheter is inserted and tip of catheter just inferior (distal) to the lateral superficial epigastric vein.
- Tumescence injected in saphenous sheath. Ablate vein with pull-back of catheter.



Arrow points to tip of catheter, which is inferior to superficial epigastric vein (SEV).

Postoperative Complications of Ablative Procedures

- DVT < 3% — most are clot extension into sapheno-femoral junction.
 - Current recommendations include 30-day follow up imaging to confirm successful closure and evaluate for deep venous thrombosis.
- **Paresthesia of leg:** Up to 20% along greater saphenous vein distribution



- Recurrence up to 5% at one year
- **Randomized trials of surgery vs. ablation:**
 - Patient satisfaction, quality of life, and analgesic requirements favor ablation.

VENOUS THROMBOTIC DISEASE

Background

Deep Venous Thrombosis (DVT):

- More than one million cases diagnosed annually in US.
- Significant clinical implications, including risk of fatal pulmonary embolism (200,000 deaths/year in the US) and long-term complications of venous hypertension (post-thrombotic syndrome).

Thrombotic Disease

Virchow in 1856 wrote paper identifying risk factors for DVT (Virchow's triad).

- **Stasis:** Post-operative/traumatic patients.
- **Hypercoagulability:** Factor V Leiden — most common deficiency, 5% of population.
 - Up to 40% of patients with DVT.
- **Vein wall (endothelial injury):** Results from direct trauma to the vessel.

Risk Factors

Previous DVT: One-fourth have previous history of DVT.

Malignancy:

- One-fifth of all first time DVT are associated with malignancy.
- 5–10% of all first time DVT will be diagnosed with malignancy within the following 24 months.

Surgery/trauma

Pregnancy

Clinical Examination

Homan's sign: Calf pain with dorsiflexion

Unilateral Acute leg swelling:

- Measure and compare calf and thigh circumference of legs.



Massive leg edema:

- *Phlegmasia alba dolens*: Indicated by significant swelling without cyanosis.
- *Phlegmasia cerulea dolens*: Indicated by significant swelling and cyanosis.
- *Venous gangrene (VG)*: This is indicated by full thickness skin necrosis, resulting from DVT, in advanced cases. Partial thickness skin necrosis, e.g. blebs or blisters, can be noted in the early phase of VG.

Palpable cord: Felt if superficial thrombophlebitis.

Laboratory Tests

- **CBC**: Check platelet count prior to starting anticoagulation.
- **BMP**: Renal failure — requires careful dosing of LMWH.
- **Art. Blood gas**: If hypoxemia, suspect PE.
- **D-Dimer**: Very high **negative predictive value** in patients with low risk of DVT.

Imaging

Venous duplex:

- **Acute**: Dilated, noncompressible, low echogenic with absence of phasicity and augmentation.
- **Chronic**: Non-dilated, echogenic, partially compressible, and collaterals often present.
- **CTV or MRV**: More sensitive for proximal thrombosis, up to 25% of patients with PE and no DVT found on lower ext. duplex have pelvic or IVC clot.
- **Ascending venogram**: Used to be the gold standard—filling defect on imaging.

May Thurner Syndrome

- Left iliac vein compression by right iliac artery.
- Venography to confirm diagnosis.
- IVUS is preferred imaging: accurate stent sizing.
- Primary stent placement (self-expanding) has become treatment of choice.



Treatment of DVT Based on Location

Iliofemoral: Catheter-directed thrombolysis and anticoagulation.

If phlegmasia is present and there is a contraindication for thrombolysis, then consider venous thrombectomy.

Technique for catheter-directed venous thrombolysis:

1. **Consider placement of retrievable IVC filter:** Routine placement has met with some controversy.
2. Prone position, an ultrasound-guided puncture of popliteal vein is performed; however it is often easier to puncture the lesser saphenous vein with its more superficial location. Also can consider posterior tibial vein access while patient supine.
3. Sheath is placed and percutaneous rheolytic thrombectomy is performed followed by placement of a lytic catheter.
4. If indicated, as in May Thurner syndrome, IVUS-guided stent placement is advisable.

Femoropopliteal: Intravenous or subcutaneous anticoagulation agents used initially with transition to oral agents for long-term use. LOVENOX® (enoxaparin sodium injection) used long-term in patients with malignancy.

- Up to 40% have asymptomatic PE.
- Nearly ¼ of patients on anticoagulation will develop symptoms of PE and may be considered treatment failures if previous diagnosis is not made by V/Q scan or CTA.

Infrapopliteal: Controversial, if high risk for anticoagulation, reasonable to repeat duplex in 5–7 days to assess for propagation.

Medical Treatment

- Unfractionated heparin with aPTT of 1.5–2.5x control or low molecular weight heparin (LMWH), with an overlap of COUMADIN® (warfarin sodium) for 5–10 days.
- **Dosage:**
 - Unfractionated heparin: 80 I U/kg bolus, infusion of 18 IU/kg (PTT q hrs).
 - LMWH: 1 mg/kg bid or 1.5 mg/kg daily
 - Warfarin: Starting dose of 5mg. DO NOT LOAD.

This manual does not include all the information needed to use the drugs listed herein safely and effectively. See full prescribing information and any boxed warnings for these drugs.



- **Goal INR:** 2.0–3.0, teratogenic, know classic meds that alter dosing i.e. antibx.

Length of Treatment:

ACCP guideline statement: Known risk factor and DVT—three months.

Idiopathic: 6–12 months, two or more episodes or hypercoagulable state, then lifelong treatment is recommended.

Key Study

- PREPIC¹⁷ (Randomized study comparing patients with anticoagulation vs. anticoagulation + filter.)
- 200 patients in each arm.
- **Eight-year follow-up**
- **Decreased PE with filter:** 6% vs. 15%.
- **Increased DVT with filter:** 35% vs. 27%.
- **Long-term survival equivalent:** Approximately 50% both arms.

UPPER EXTREMITY DVT

- Majority of patients have identifiable risk factors, and up to two-thirds have central venous catheters or pacemaker/AICD.
- Malignancy in one-third.
- **In the young, consider Paget Schrotter syndrome (effort vein thrombosis):**
 - Severe, painful, upper extremity swelling, with significant superficial venous engorgement. Treatment should include thrombolysis followed by TOS decompression.
- Up to 10% develop PE.

Treatment

- **Same as for lower extremity DVT:** Anticoagulation.
 - If failure or contraindication to anticoagulation, consider SVC filter, but only in high risk patients.
 - **Limitations:** Filters not indicated for SVC use, risk of cardiac tamponade.
- Three-month mortality can be up to one-third of patients with upper extremity DVT.

This manual does not include all the information needed to use the drugs listed herein safely and effectively. See full prescribing information and any boxed warnings for these drugs.



PULMONARY EMBOLISM

Background

Up to 50,000 deaths annually secondary to PE.

History and Physical Examination

Tachypnea is most common, pleuritic chest pain, hemoptysis, tachycardia, hypotension, hypoxemia, and hypocarbia common.

Diagnosis

1. **EKG:** Sinus tachycardia *most common finding.
2. **CXR:** Rule out other causes. **Westermark sign:** segmental or lobar perfusion loss.
3. **V/Q scan:** Ventilation perfusion defects (very sensitive as per PLOPED study).
4. **CTA:** The most common method to evaluate.
5. **Pulmonary angiography:** Gold standard and seldom necessary.

Intervention

- **Anticoagulation:** Same as for acute DVT.
- **Systemic thrombolysis:** When patient has significant cardiopulmonary effects of embolism, i.e. hemodynamic changes with echocardiogram showing right ventricular dilation, deviation of septum, tricuspid insufficiency and pulmonary hypertension.
- Consider catheter-directed treatment for systemic failures.

VENA CAVA FILTERS

Background

- **Surgical plication:** Historically performed with an Adams-Deweese clip.
- **Greenfield filter:** First devices: surgical venotomy until 90s then percutaneous.

Indications for IVC Filter

1. Failure of anticoagulation.
2. Contraindication for anticoagulation.



3. Recurrent DVT despite anticoagulation.
4. Prophylactic filter: for patients at high risk of PE prior to bariatric surgery if venous insufficiency. Selected trauma patients: Brain injury, solid organ injury.
5. Following pulmonary embolectomy and those who could not tolerate additional PE.
6. Free-floating iliofemoral thrombus.

Technique

Access: Femoral — 90% at our institution, jugular, subclavian access.

Imaging for placement:

- **Fluoroscopic**, IVUS, transabdominal ultrasound-guided.
- Need to identify renal veins: filter to be placed inferior to renal veins. Typically found at L1–L2.
- Techniques to identify renal veins:
 - Venography from distal IVC or proximal ipsilateral iliac vein
 - Selective catheterization
 - IVUS
- Most filters can be placed in IVC diameter < **28 mm** *check IFU of device
- Calibrate caval diameter by venogram or IVUS more precise measurement.
- > **28 mm**: Bird's nest or bilateral iliac vein filters. Rarely required.

When to place suprarenal filter:

- Ovarian or renal vein thrombosis.
- Pregnancy.
- Thrombus extended beyond already inserted IVC filter.

Filter Types

Permanent: Designed to never be explanted.

Optional: Potential to be removed, however can remain permanently in place, ¼ removed most series.

Design:

- **Conical:**
 - GREENFIELD® Vena Cava Filter (Boston Scientific, Natick, MA) (Permanent): 1973. Conical shaped, ≤ 28 mm IVC, reported to be the



least thrombogenic filter, delivered via 12 Fr sheath. **Longest and largest data of any filter.**

- COOK® SELECT Vena Cava Filter (COOK® Medical, Bloomington, Indiana) (Retrievable): Can treat up to 30 mm IVC, delivered via 8.5 Fr sheath.
- **Double basket design:**
 - TRAPEASE® Vena Cava Filter/OPTASE® Retrievable Vena Cava Filter (Cordis Corporation, Bridgewater, NJ): Several studies have shown significant rate of caval thrombosis; can treat up to 30 mm IVC, OPTASE® Retrievable Vena Cava Filter only retrieval filter from femoral approach, can be delivered via 8 Fr sheath.
 - Randomized trial of TRAPEASE® Vena Cava Filter vs GREENFIELD® Vena Cava Filter demonstrated higher caval thrombosis with the TRAPEASE® Vena Cava Filter.
- **Nest:**
 - BIRD'S NEST® Filter (COOK® Medical, Bloomington, Indiana): Designed for MEGA CAVA, higher rate of caval thrombosis secondary to design, treats up to a 40 mm IVC, can be delivered via 12 Fr sheath.

Complications of Filters

Migration, thrombosis, fracture, and/or penetration into surrounding structures (bowel, artery, etc.).

Pitfalls and Pearls of IVC Filters

1. Poor history and already had a filter, always check abdominal X-ray on table prior to prepping patient.
2. Check femoral veins prior to prepping patients. Occasionally we will find bilateral common femoral occlusions after filter is opened.
3. Never advance sheath in vena-cava without wire or introducer (tip can be advanced into lumbar vein).
4. Understand the filter you are deploying, the classic mistake of pushing and pulling at same time can push filter out into adjacent branches (renal or lumbar veins).
5. Always follow sheath advancement with fluoroscopy. If wire is not stiff enough the sheath can prolapse (i.e. the heart from a jugular approach and cause tamponade).



Important Changes in Nomenclature of Lower Extremity Veins

OLD NOMENCLATURE	NEW NOMENCLATURE
Femoral Vein	Common Femoral Vein
Superficial Femoral Vein	Femoral Vein
Sural Veins	Sural Veins; Soleal Veins; Gastrocnemius Veins (Medial and Lateral)
Huntarian Perforator	Mid Thigh Perforator
Cockett's Perforators	Paratibial Perforator
May's Perforator	Posterior Tibial Perforators
Gastrocnemius Point	Intergemellar Perforator
Greater Saphenous Vein	Great Saphenous Vein
Lesser Saphenous Vein	Small Saphenous Vein



"Missing this is almost unforgiveable...."

Patrick Stone, MD



CHAPTER 20

COMPARTMENT SYNDROME

Mohit Srivastava

MISSING THIS IS ALMOST UNFORGIVEABLE...**Pathogenesis**

- Universal feature:
 - Increase in intracompartmental pressure that leads to decreased tissue perfusion
- As compartmental pressure rises, it is transmitted to postcapillary venules and:
 - Venous pressure rises FIRST
 - Eventually, capillaries collapse and resistance increases

Intracompartmental Pressure (ICP) thresholds:

- > 30 mmHg or within 20 mmHg of dBp
- Dynamic pressure (MAP — ICP)
 - < 40 has been shown to correlate well with tissue ischemia.
 - Has been shown to decrease number of unnecessary fasciotomies, even in the presence of an ICP > 30 mmHg.

Tissue susceptibility to ischemia:

Nerve tissue: Permanent damage at two hours or less.

Muscle: Maximal contracture at 12 hours, death begins at four hours.

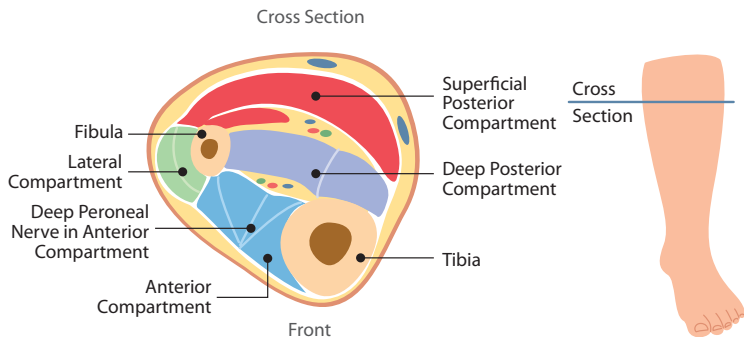
Skin and subcutaneous tissue: Much more tolerant of ischemia.

Need for fasciotomy still most dependent on clinical stage of ischemia, not duration.

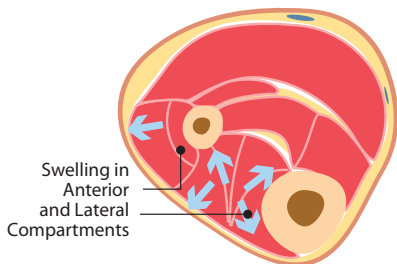


Compartment Syndrome of Lower Leg with Muscle Necrosis

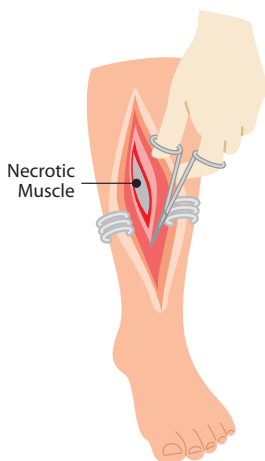
Compartments of the Lower Leg



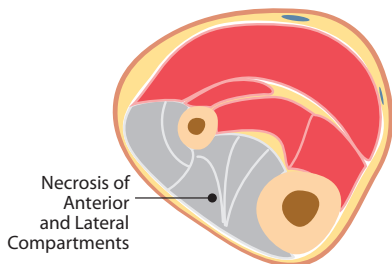
Early Stage Compartment Syndrome



Surgical Procedure



Late Stage Compartment Syndrome



An incision is made in the leg and the necrotic muscle is debrided



Etiologies

Ischemia-Reperfusion:

- High-risk
 - Ischemia > 6 hours, poor collaterals, poor intra-op. back bleeding.

Trauma:

- Can be caused by arterial or venous (highest when combined injury).
- Popliteal injury carries higher rate of fasciotomy than any other site.

Venous outflow obstruction

Hemorrhage

Iatrogenic:

- Extravasations of fluid/medication; prolonged immobilization.

Clinical Evaluation

Four compartments of lower extremity:

- **Anterior:**
 - Deep peroneal nerve, anterior tibial artery
- **Lateral:**
 - Superficial peroneal nerve
- **Deep posterior:**
 - Tibial nerve, posterior tibial artery, peroneal artery
- **Superficial posterior:**
 - Sural nerve

Compartments most commonly affected:

- Anterior > lateral > deep posterior > superficial posterior.

Must do a thorough motor and sensory exam:

- Pain is usually out of proportion to the extent of the injury.
- Pain on passive motion is usually seen first.
- Anterior compartment, paresthesia in dorsum of first web space.
- Loss of arterial pulse is late finding.



Measuring ICP:

- Stryker system and Whiteside Manometer are most commonly employed.
- Can use arterial line manometer if the patient is in the ICU.
- ***Most symptomatic compartment first:***
 - Then, all other compartments can be interrogated
- Always compare to MAP and dBP.
- Normal ICP: 10–12 mmHg.

Treatment

Fasciotomy:

Criteria for intervention include:

- Prophylactic: Patients at high risk at the time of revascularization.
- ICP, MAP, dBP measurements (as previously listed).

Technique:

- Lower extremity
 - ***Double incision:*** Classic
 - Lateral incision allows for access to the anterior and lateral compartments and medial incision allows for access to the deep and superficial posterior compartments.
- Upper Extremity
 - ***Forearm:***
 - *2 compartments image for eversion:* Volar (superficial and deep) and dorsal.
 - Volar compartments are most frequently affected.
 - Incision begins medial to the biceps tendon above the antecubital fossa.
 - Extends in a curvilinear fashion distally.
 - For dorsal compartment, single incision from lateral condyle to the wrist.



Postoperative Measures

Wound management:

- Delayed primary closure.
- Secondary intention.
 - Vacuum dressing
- Split thickness skin grafting in approximately one-half of incisions.

Complications:

- Local:
 - Neurologic deficit (foot drop), wound complication.
- Systemic:
 - Myonecrosis (increased creatinine phosphokinase, CPK), hyperkalemia, hypocalcemia, renal failure, DIC, death.



CHAPTER 21

VASCULAR TRAUMA

D. Daniel Dearing

GENERAL PRINCIPLES

- Classic injuries.
 - Aorta — deceleration at ligamentum arteriosum
 - Carotid/vertebral — flexion/extension
 - Brachial artery — proximal humerus fracture
 - Popliteal artery — posterior knee dislocation

INITIAL ASSESSMENT AND RESUSCITATION

- Pertinent historic details:
 - Mechanism
 - Blunt or penetrating
 - Approximate time since injury
 - Blood loss at scene
 - Known prior disabilities/injuries
 - Type of weapon ($K = m \times v^2$)
 - Body position, entrance/exit wounds
 - Height of fall, speed of vehicle
- Initial assessment follows ATLS protocols.
- Significant bleeding best controlled with direct pressure at bleeding site or at proximal artery supply.
- “Permissive hypotension” benefits.
 - Resuscitation to normal BP can lead to dislodgment of an initially hemostatic plug
 - $SBP \leq 90$ mmHg may be more appropriate to avoid further hemorrhage



- Secondary survey.
 - Pulses should be assessed in neck and extremities
 - Audible bruit or palpable thrill — AVF
 - Neurologic exam: concomitant injuries > 20%
 - Bony deformities, fractures, or dislocations
 - Skin changes
- Hard signs — high suspicion of vascular injury.
 - External arterial hemorrhage, pulsatile hematoma
 - 5 P's
- Soft signs.
 - Diminished distal pulses
 - Proximity of penetrating injury
 - Peripheral neurologic deficit

DIAGNOSTIC CONSIDERATIONS

- Routine radiographs: C-spine, CXR, abdominal, pelvic, extremity films.
 - Can document fractures, foreign bodies, bullets or shrapnel
- Arteriography remains gold standard.
 - “Hard” signs most predictive of injury,
 - **Preoperative arteriography:** Visualization of anatomic regions that are difficult to assess
 - Axillary/subclavian arteries
 - High (zone 3) carotid injuries
 - Thoracic inlet (zone 1) neck injuries
- Allows for potential endovascular interventions.
 - Duplex ultrasound or CTA: consider first line if soft signs

OPERATIVE PRINCIPLES

- Obtain hemostasis: Secure proximal and distal control.
 - Direct pressure/proximal arterial compression
 - No blind clamping
 - Consider balloon occlusion
- Exploration and debridement.
 - Exposed adjacent normal vessel
 - Preserve collateral vessels when possible
 - Arteriotomy: usually longitudinal



- **Repair techniques.**
 - Ligation
 - Venous ligation usually well tolerated in the extremities
 - Can be employed for large central veins (e.g. portal vein or IVC) in extreme situations
 - Arterial vessels that can be safely ligated if necessary
 - Subclavian artery
 - Radial or ulnar arteries (if intact palmar arch present), single tibial artery
 - Internal iliac artery
 - Superficial femoral artery
 - Simple repair
 - Used when minimal damage present, simple PROLENE® Suture repair
 - End-to-end repair
 - Tension-free anastomosis
 - Generally can resect 1–2 cm of vessel,
 - Interposition Grafting
 - Used when a tension-free anastomosis not possible
 - Autogenous vein preferred (especially for small vessels < 5 mm)
- **Assessment of revascularization.**
 - Return of normal distal pulses
 - Completion on-table arteriogram
- **Wound closure.**
 - If large soft tissue defect then muscle coverage/vacuum dressing
- **Vascular damage control “unstable patients”.**
 - Ligation of vessels not essential to distal tissue viability
 - Consider shunt

CAROTID ARTERY INJURIES

- **5% of arterial injuries:** Stroke in ¼ and > 15% mortality.
- Frequently associated injuries: upper aerodigestive, spinal cord, vert. arteries.



PENETRATING NECK INJURIES

- Hard signs (mandate neck exploration).
 - Airway compromise
 - Shock or active bleeding/expanding hematoma
 - Focal neurological deficit
 - Loss of carotid pulse
- Soft signs (require further investigation).
 - Dysphagia/voice change/hemoptysis, widened mediastinum
- Zones of the neck.
 - Zone 1 — Region from the clavicle to the cricoid cartilage
 - Zone 2 — Region from the cricoid cartilage to the angle of the mandible
 - Zone 3 — Region from the angle of the mandible to the base of the skull
- Zone 1 penetrating injuries.
 - Proximal control:
 - Median Sternotomy
 - Innominant, common carotid and right subclavian arteries
 - Anter. lat. thoracotomy:
 - Proximal left subclavian artery
 - Prosthetic conduits
 - Endovascular options possible: case reports only
- Zone 2 penetrating injuries.
 - Majority of penetrating trauma to the neck
 - Hard signs of vascular injury/platysma violation = explore
- Zone 3 penetrating injuries.
 - Difficult exposure may require ligation
 - Another option is endovascular repair
 - *If no hard signs, serial examination:* CTA vs. formal angio

BLUNT CEREBROVASCULAR INJURIES (BCVI)

- Asymptomatic— $\frac{3}{4}$

Injury

- Intimal disruption or tear leading to thrombosis or dissection.
- Etiologies: assault, seat belt, oral trauma, basilar skull fractures.
- “High risk” for BCVI: Mechanism + presence of bruit, bruising or abrasions, visual disturbances, seizures, headache, focal neurologic



deficits GCS < 6, petrous bone fractures, diffuse axonal injury, i.e. Fort II or III fractures.

- CT angiography as a screening modality — high-risk patients.
- CCA injuries — resection and primary anastomosis or interposition grafting.
- ICA injury more challenging due to inaccessibility of many injuries.
 - Current treatment regimen is anticoagulation, especially for dissection injury
 - Resolution of dissection often occurs
 - AV fistulas or pseudoaneurysms: consider endo tx.

VERTEBRAL ARTERY TRAUMA

- **Rare:**
 - C7–T1 level is most commonly injured, followed by C1–C2
 - ¾ of patients have no signs on physical exam
 - AVFs more common due to nearby venous plexus
 - Clinical evaluation:
 - Signs raising suspicion:
 - High cervical quadriplegia
 - Respiratory failure
 - Horner syndrome
 - Cerebellar symptoms: Ataxia or Wallenberg syndrome
 - Cranial nerve deficits
 - Imaging:
 - Arteriography — Gold standard
 - Allows for diagnosis/potential intervention
 - **Treat:** hemorrhage, pseudoaneurysm, or AV fistula
 - CT angiography can be used as a screening modality
 - Active bleeding from V1 — can be ligated surgically or embolized
 - Treatment:
 - Surgical repair: primary repair, interposition, transposition to CCA
 - Endovascular approaches required for middle and distal vertebral artery
 - Usually requires endovascular embolization of both the proximal and distal end of the injured artery



THORACIC VASCULAR TRAUMA

- Acute deceleration — descending thoracic aorta at ligamentum arteriosum.
- Most patients with significant injury die at scene (up to 85%).
- $\frac{1}{3}$ — present in hemorrhagic shock with a mortality approaching 100%.
- $\frac{2}{3}$ remain stable with a mortality of 25%; mostly due to associated injuries.
- Imaging
 - CXR: widened mediastinum
 - CTA: now becoming “image modality of choice”
 - TEE very specific not as sensitive
 - Can be used during laparotomy/assess cardiac function
- Treatment
 - Nonoperative treatment
 - Due to associated injuries — 50% not surgical candidates
 - Physiologic high risk
 - Closed head injury (GCS < 6 or intracranial bleed)
 - ARDS/acute lung injury (P:F ratio < 200)
 - Cardiac injury
 - Coagulopathy
 - Anatomic high risk for repair
 - Extensive calcification
 - Arch involvement and circulatory arrest contraindicated
 - **Cornerstone of therapy — blood pressure control**
 - Target pressure < 125 mmHg historically used, but even lower pressures (~ 100 mmHg) acceptable
 - Short-acting beta blockers (esmolol or labetalol) preferred
 - Risk of expansion greatest in first 5–7 days
 - Serial helical CTA every 48 to 72 hours for first 7 days
 - Operative repair
 - Posterolateral 4th intercostal space approach
 - Technique: Graft interposition or primary repair
 - Mechanical circulatory support can be key method to reduce risk of paralysis and end organ ischemia
 - Atrial-femoral
 - Femoral-femoral

This manual does not include all the information needed to use the drugs listed herein safely and effectively. See full prescribing information and any boxed warnings for these drugs.



- Endovascular repair
 - Conformable GORE® TAG® Thoracic Endoprosthesis (Gore, Flagstaff, AZ) 2012
 - Approved for traumatic thoracic injury
 - Need 2 cm of “landing zone”— proximal and distally
 - **Can cover/debranch:** L sub. artery
 - Follow *Instructions for Use* for follow-up

ABDOMINAL VASCULAR TRAUMA

Background

- Accompanied by injury to adjacent solid or hollow abdominal organs frequently.
- **Physical findings:** Hypotension/abd. distention unresponsive to fluids, peripheral arterial exam—document if abnormal, check ABI.
- Patients who are hemodynamically stable with an unexplained ABI < 0.9 require arteriography.
- Patients that require immediate OR exploration.
 - Penetrating injury — hemodynamically unstable or fascial penetration
 - Peritonitis/pneumoperitoneum
 - Blunt trauma with positive FAST exam
- **Anatomy**
 - Zone 1 — central region of the retroperitoneum; subdivided into supramesocolic and inframesocolic when assessing hematoma
 - Aorta
 - IVC
 - Mesenteric vessels
 - Proximal renal arteries
 - Zone 2 — lateral portions of retroperitoneum
 - Kidneys/ureters
 - Retroperitoneal portions — right and left colon
 - Lateral segments — renal artery and vein
 - Zone 3 — pelvic portion of vascular system
 - Common, external, internal iliac arteries and veins
- **Operative techniques**
 - **Midline incision:** xiphoid — symphysis pubis, can convert to median stern.
 - Abdominal organs eviscerated and gross blood and clot evacuated



- Laparotomy pads used for packing to achieve hemostasis
- Enteric viscera inspected: GE junction — colon at peritoneal reflection
- Gastrocolic omentum divided and lesser sac explored
- Kocher maneuver to inspect duodenum and head of pancreas
- Mesentery explored for mesenteric hematoma
- Final inspection should be solid organs
- **Left medial visceral rotation** — **visualization aorta**: Hiatus-iliac bifur.
- **Right medial visceral rotation**: Exposure of the IVC and right zone 2
- **Proximal and distal vascular control**: Exposure hematoma / bleeding
- Principles of vascular repair followed
 - Debridement of injured vessels, prevention of embolization of clot or air, irrigation, primary repair or interposition grafting

Management of Intra-Abdominal Hematomas

ANATOMIC REGION	PENETRATING	BLUNT
Zone 1	Open	Open
Zone 2	Open	Do not open unless ruptured, pulsatile, rapidly expanding
Zone 3	Open	Do not open unless ruptured, pulsatile, rapidly expanding or absent iliac pulse
Portal Triad	Open	Open
Retrohepatic	Do not open unless ruptured, pulsatile, or rapidly expanding	Do not open unless ruptured, pulsatile, or rapidly expanding

PERIPHERAL VASCULAR TRAUMA

Mangled Extremity Severity Score (MESS)

Skeletal/soft-tissue injury

- **Low energy (stab; simple fracture; pistol gunshot wound): 1**
- **Medium energy (open or multiple fractures, dislocation): 2**
- **High energy (high speed MVA or rifle GSW): 3**
- **Very high energy (high speed trauma + gross contamination): 4**

*Limb ischemia**



- *Pulse reduced or absent but perfusion normal: 1*
- *Pulseless; paresthesias, diminished capillary refill: 2*
- *Cool, paralyzed, insensate, numb: 3*

Shock

- *Systolic BP always > 90 mmHg: 0*
- *Hypotensive transiently: 1*
- *Persistent hypotension: 2*

Age (years)

- *< 30: 0*
- *30–50: 1*
- *> 50: 2*

* Score doubled for ischemia > 6 hours

MESS value greater than or equal to 7 predicted amputation with 100% accuracy.

Diagnostic evaluation

- “Hard signs” require immediate surgical exploration with intraoperative arteriography
- Most arterial injuries are clinically occult
- Color-flow duplex imaging useful but highly operator dependent
- CTA has high sensitivity and specificity; may be best screening modality, reserving arteriography for anticipated endovascular treatment

Treatment

- **Non-operative management**
 - Controversial, but may be considered if:
 - Low-velocity injury
 - Intimal defects and pseudoaneurysms
 - Intact distal circulation
 - No active hemorrhage
 - Follow-up imaging in 1–2 weeks
- **Endovascular management**
 - Transcatheter embolization
 - Low-flow arteriovenous fistulae, false aneurysms, and active bleeding from noncritical arteries
 - Stents to exclude the injured area or to treat focal intimal injury
- **Operative Management**



- Draping of entire injured extremity and contralateral extremity
- Initial closed reduction of severely displaced fractures/dislocations can restore pulses
- Proximal and distal control obtained prior to exposure of the injury
- Endoluminal balloon occlusion — can provide temporary control
- Debride to macroscopically normal arterial wall
- Fogarty catheters passed proximally and distally
- Systemic heparinization used unless contraindicated
- Consider intraluminal shunting:
 - Severe ischemia of limb and revasc. delayed secondary to fracture fixation, complex soft tissue injury, or associated life-threatening injuries
- Type of repair dictated by extent of arterial damage
- **Extra-anatomic bypass:** Extensive soft tissue loss/associated bowel injury
- **Conduit of choice: Contralateral Saphenous Vein**
- Intraoperative completion arteriography

Subclavian–axillary arteries

- Most commonly penetrating trauma: up to 50% mortality.
 - Associated with major musculoskeletal and brachial plexus injury.
 - Fracture dislocation of the posterior portion of the first rib.
- Critical ischemia of the upper extremity uncommon due to rich collateral circulation around shoulder.
- Surgical Approach: Penetrating injuries of the right subclavian–axillary arteries require median sternotomy for proximal control.
- Left anterolateral or “trap door” thoracotomy may be necessary for proximal left subclavian injuries.
- Supraclavicular incision for more distal subclavian artery.
- Axillary artery approached through infraclavicular incision.
- Endovascular therapy has been used in selected patients.
 - Hemodynamically unstable
 - Traumatic arteriovenous fistulae and false aneurysms
 - Focal intimal lesions

Brachial, radial, and ulnar arteries



- Penetrating trauma and supracondylar fractures of the humerus.
- Injuries distal to profunda brachii may not manifest signs of ischemia.
- Single vessel injury (forearm) — ligation if palmar arch intact.
- Ulnar artery repaired if combined injury — usually dominant vessel.

External iliac-femoral arteries

- Iliac arteries: Lethal injury.
- Proximal control of external iliac artery — retroperitoneal exposure.
- Proximal profunda femoral — repair, important LE collateral supply.
- SFA can be ligated if needed.

Popliteal artery

- Outcome depends predominantly on mechanism of injury.
- Amputation rate for shotgun wounds approaches 20%.
- Injuries directly behind the knee can be approached posteriorly.
- Interposition or bypass, and autogenous vein preferred (contralateral vein).

Tibial arteries

- Single actively bleeding/pseudoaneurysm — ligation/embol.
- Tibioperoneal trunk or two infrapopliteal vessels — repair.

Extremity Venous Injuries

- Most commonly injured superficial femoral vein (40%), popliteal vein (25%) and the common femoral vein (15%).
- Localized injury — end-to-end/lateral venorrhaphy — unless unstable.

Retrohepatic Vena Cava/Hepatic Vein Injury

- Life threatening bleeding occurs if supporting structures are disrupted (ligaments, diaphragm, liver parenchyma).
- Exposure may release tamponade resulting in exsanguination.

If Pringle maneuver stops bleeding: Hepatic artery/portal vein injury



If bleeding slows with held respiration: Hepatic vein/retrohepatic cava injury

- Three main strategies for management
 - Direct vein repair
 - Lobar resection
 - Tamponade and containment of venous bleeding, lowest reported mortality (~20%)
- Atriocaval shunt (Schrock, *et al.*, 1968)
 - High mortality of ~200 reported cases
 - Rarely used presently, requires thoracoabdominal incision



APPENDIX 1

**CONTRAST ALLERGY PRE-PROCEDURE
PROTOCOL****PREMEDICATION OF PATIENTS WITH
KNOWN OR SUSPECTED CONTRAST ALLERGY**

1. Prednisone: 50 mg po at 13 hours, 7 hours, and 1 hour before contrast media injection, and BENADRYL® (diphenhydramine): 50 mg IV/IM/po 1 hr, before contrast medium.

Urgent medication if can't do above:

1. SOLU-MEDROL® (methylprednisolone sodium succinate) 40 mg or SOLU-CORTEF® (hydrocortisone sodium succinate) 200 mg IV (q4h) until contrast study required and diphenhydramine 50 mg IV 1hr prior to contrast .
- Data suggest steroids of limited effect if not given more than 4 hours pre-contrast load.



APPENDIX 2

OUTPATIENT COUMADIN® (WARFARIN SODIUM) ORDER SET**Indication (Mark all that apply):**

- ☐ Deep Vein Thrombosis (DVT)
☐ Pulmonary Emboli (PE)
☐ Heparin-Induced Thrombocytopenia (HIT)
☐ High Risk Peripheral Vascular Disease (PVD)
☐ Other:

Target INR: ☐ 2.5 (range 2.0-3.0) ☐ Other:

Expected Duration of Therapy: ☐ 3-6 months ☐ 6-12 months ☐ Lifetime ☐ Other:**INR Monitoring Schedule:**

# Consecutive In-range INR's	Repeat INR in
1	7 days
2	14 days
3	21 days
4	28 days

INR 2.0-2.1 or 2.9-3.0 repeat INR in 14-21 days regardless of # of consecutive in-range INR's

INR <2 Increase weekly dose by 10%, repeat INR in 7 days**INR 2-3** No change, follow INR monitoring schedule**INR 3.1-3.5** ... Decrease weekly dose by 10% and repeat INR in 7 days**INR 3.6-4** Decrease weekly dose by 15% and repeat INR in 7 days**INR 4-5** Hold one dose and decrease weekly dose by 20%. Repeat INR in 4 days**INR >5** Notify physician

If INR is subtherapeutic (less than 2.0) or supratherapeutic (greater than 3.0) review patient's medication list and inquire about recent dietary changes. Report new medication additions to physician.



APPENDIX 3

**REVERSING EXCESSIVE
WARFARIN-ASSOCIATED AC****1998 AND 2001 ACCP RECOMMENDATIONS FOR
REVERSING EXCESSIVE WARFARIN-ASSOCIATED
ANTICOAGULATION**

1. INR < 5: No bleeding.
Reduce or omit next few doses.
2. INR 5 < 9: No bleeding.
Omit next few doses and consider low dose
Vitamin K oral (1–2.5 mg).
3. INR > 9: No bleeding.
Hold warfarin, Vitamin K oral (2.5–5.0 mg),
Fresh Frozen Plasma: 4 units
4. Bleeding at any elevated INR:
 - Tx: Hold warfarin
 - Fresh Frozen Plasma: 4 units
 - Vitamin K IV: 10 mg slow
 - Consider Recombinant Factor 7a

*In patients with prosthetic heart valves, FFP is preferred over Vitamin K; use only very low doses of Vitamin K (1 mg by slow IV infusion).



REVERSAL OF COUMADIN® (WARFARIN SODIUM) IN PATIENTS REQUIRING SURGERY IN 24–48 HOURS

1. INR : < 2.0: Vitamin K 1.0 mg po
2. INR: 2–5: Vitamin K 1–2.5 mg po
3. INR: 5–9: Vitamin K 2.5–5.0 mg po, repeat 1–2 mg in 24 hours if still elevated

For patients requiring emergent surgery use FFP and Vitamin K intravenous from 1–5 mg slowly depending on degree of INR elevation.

This manual does not include all the information needed to use the drugs listed herein safely and effectively. See full prescribing information and any boxed warnings for these drugs.



W. L. GORE & ASSOCIATES, INC.

Flagstaff, AZ 86004

+65.67332882 (Asia Pacific)	800.437.8181 (United States)
00800.6334.4673 (Europe)	928.779.2771 (United States)

goremedical.com