

Neurological Emergencies

Michael P. Merchut, M.D.
Professor of Neurology
Loyola University Medical Center

A 75 year-old man is brought to the ER by ambulance because of a stroke one hour ago during breakfast. What are the neuro signs and symptoms, abrupt in onset, suggestive of a stroke?

- 1.
- 2.
- 3.
- 4.
- 5.
- 6.

Which are hemispherical or cortical (carotid territory), and which are brainstem or cerebellar (VB territory)?

Acute stroke syndrome

- Hemiparesis or weakness in one limb
- Monocular (retinal infarct) or binocular blindness, especially if homonymous
- Sensory deficit on one side
- Language deficit
- Brainstem deficits (diplopia, dysarthria, deafness, crossed sensory or motor signs)
- Ataxia of limbs or gait

Which things do you check or treat first, when you are convinced the patient has an acute stroke?

- 1.
- 2.
- 3.
- 4.
- 5.
- 6.

The patient has no history or signs of acute head or neck trauma.

Acute stroke syndrome

- A-B-C's
 - NPO, intubate for inadequate airway, ventilate if needed
 - Correct hypotension, rule out acute MI or arrhythmia (a-fib)
- Rule out hypoglycemia
- Minimize hyperglycemia by running an IV of 0.9% normal saline initially at a TKO rate
- Use parenteral antihypertensive Tx only for sustained, very high BP (>220/120; or >185-110 for IV tPA)
- Evaluate patient for use of IV tPA
- Decide on when to get a brain scan (which type?)

Acute stroke syndrome: IV tPA

- IV tPA must be given within 3 hrs of stroke onset
- Neuro deficit (NIHSS score 5 to 22) must not be rapidly improving (TIA) or post-ictal
- BP maintained under 185/110
- Normal PTT, PT \leq 15 sec, platelets \geq 100,000
- No blood, or edema/infarct > 1/3 of MCA territory on CT
- No bleeding, recent surgery, MI, arterial puncture or LP
- Blood glucose is between 50 and 400 mg/dl

Acute stroke syndrome: what scan & when?

- CT scan
 - in deteriorating patient, quickly rules out hemorrhage, mass (tumor, abscess) or early infarct edema
 - shows cortical infarcts by 1-2 days, may miss lacunes
- MRI scan
 - highest resolution scan, but longer scanning time
 - DWI (diffusion weighted imaging) detects impaired movement of water in infarct immediately
 - non-invasively view arterial supply (MRA)
 - contraindications: pacemaker

Acute stroke syndrome: considerations in younger or atypical patients

- Arterial
 - Dissection (spontaneous, traumatic)
 - Fibromuscular dysplasia, Marfan's, vasculitis
 - Vasoactive drugs: cocaine, amphetamines
 - Migraine
- Paradoxical cardiac embolus (PFO)
- Hypercoagulable states

Acute stroke syndrome: anticoagulation

- Anticoagulation (heparin, warfarin) is indicated in select cases:
 - Atrial fibrillation
 - Carotid or vertebral dissection
 - Cerebral sinus (venous) thrombosis
 - Hypercoagulable states
- Anticoagulation is withheld 5-7 days or more in presence of larger, or hemorrhagic, infarcts
- Goal of preventing future infarcts, perhaps clot extension

Acute stroke syndrome: atrial fibrillation

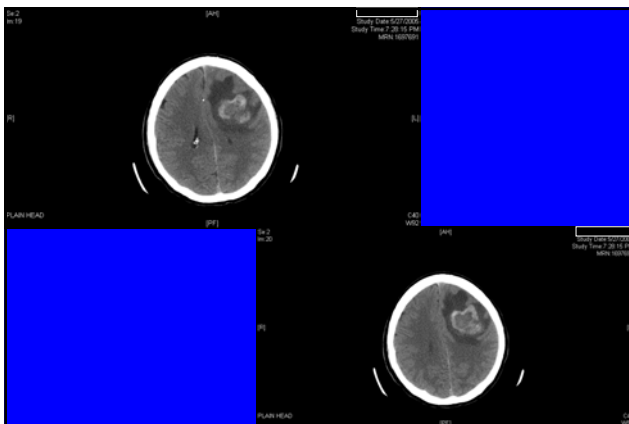
Age	Stroke risk	Treatment
Any	High*	Warfarin, INR 2.5 (2.0-3.0)
>75	High*	?? Warfarin, INR 2.0 (1.6-2.5)
65-75	Low	Warfarin, or ASA 325 mg/d
<65	Low	None, or ASA 325 mg/d

*High risk: age >75, HTN, poor LV function, history of stroke, TIA or systemic embolus;
(Amer Coll Chest Physic, *Chest* 1995; 108:352S-359S)

A 75 year-old man is verbally unresponsive in the ER, Moving only his left limbs to painful stimuli. BP is 210/106, pulse 85/min and afebrile. His lip is bleeding And there is blood in his Foley (urinary) collection bag.

He gradually becomes even less responsive.

What do you do?

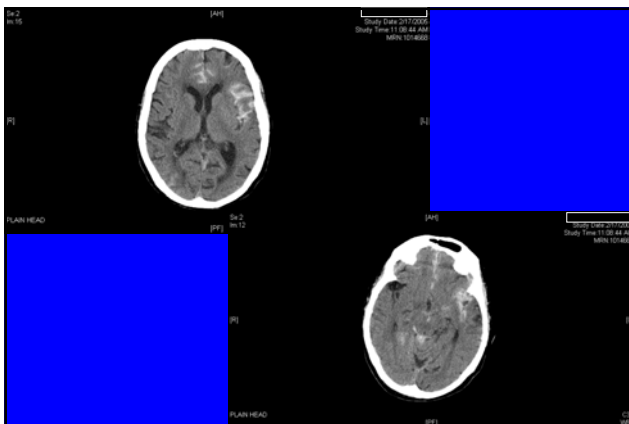


Increased intracranial pressure

- Hemorrhage, intracerebral
 - surgical evacuation for severe cerebellar bleeding, rarely elsewhere
 - trauma? bleeding disorder? HTN?
 - ventriculostomy drain
- Treatment of increased ICP
 - Hyperventilation ($pCO_2 < 25$ mm)
 - Mannitol (0.25 gm/kg q6 hrs if $S_{osm} < 310$)
 - Tumor, encephalitis, abscess: dexamethasone 4 mg IV q6 hrs
 - Acute hydrocephalus: shunt

A 32 year-old woman is found on the floor at work, unconscious, but spontaneously breathing. In the ER, BP is 146/75, pulse 80, afebrile. Her left pupil is 5 mm and sluggishly reacts to light; the right pupil is 2 mm and briskly reacts to light. She does not grimace or move to painful stimuli, nor attempt to speak.

What do you do?



Coma: subarachnoid hemorrhage

- Berry aneurysm commonest if no trauma
- Verify blood by CT, or LP if CT normal
- Emergent angio and neurosurgical clipping
- Treat vasospasm with
 - “Triple H:” Hypertension, Hypervolemia, Hemodilution after aneurysm clipped
 - Nimodipine 60 mg PO (NG) q4 hrs x 21 days
- Coils may be placed into inoperable aneurysms

Coma: bedside exam of patient

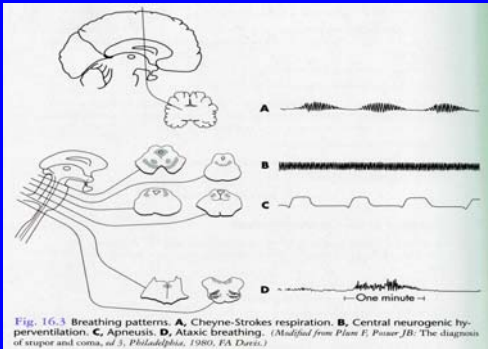
- Motor responsiveness or posturing
- Respiratory pattern
- Pupils
- Reflexive eye movements

Coma: motor responsiveness

- Encouraging responses to pain stimuli:
 - arousal, verbalization
 - localization and avoidance of stimulus
- Decorticate posturing (flexion of arm(s), extension of leg(s)): cortical level
- Decerebrate posturing (extension of arm(s) and leg(s)): midbrain level
- Myoclonic jerks: metabolic/anoxic state

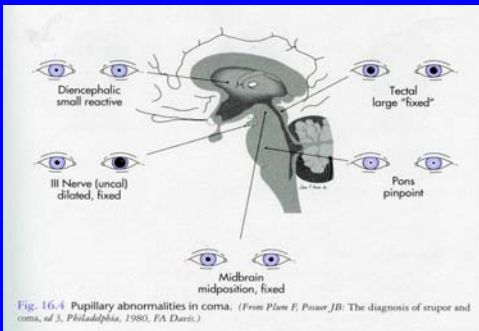
Coma: respiratory pattern

- Cheyne-Stokes (crescendo-decrescendo)
 - often seen in sick elderly, or CHF patients
 - can reflect bilateral cerebral problem
- Patterns may not localize “classically”
- Ataxic, irregular breaths
 - preterminal pattern preceding respiratory arrest, when dysfunction at level of medullary respiratory center



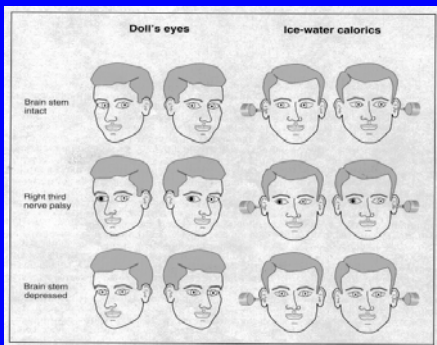
Coma: pupil size and reactivity

- Smaller, reactive pupils persist in metabolic coma
- Larger, unreactive pupil(s) reflect third cranial nerve or midbrain lesion
- Pinpoint, reactive pupils from pontine lesion (or narcotic overdose)
- Medicinal eyedrops may impair light reflex



Coma: Reflexive eye movements

- Oculocephalic (doll's eyes) reflex:
 - eyes roll opposite to lateral turn of head
- Oculovestibular (cold caloric) reflex:
 - eyes slowly deviate toward "cold ear"
- May be "falsely" absent in presence of
 - vestibulotoxic drugs (benzodiazepines, barbiturates, aminoglycosides)
 - previous otic disease



(modified from Collins RC: Neurology, Philadelphia, 1997, WB Saunders)

Coma: clinical guidelines

- Structural lesions causing coma
 - Asymmetrical motor, reflex or pupillary findings, preceding mental status changes
- Metabolic conditions causing coma
 - Mental status changes precede symmetrical motor or reflex findings
 - Pupillary light reflex relatively preserved
 - Myoclonic jerks, tremor, asterixis typical

Coma: emergent care

- Ensure adequate “A-B-Cs” (also rule out primary cardiopulmonary cause of coma)
- Immediately rule out hypoglycemia, or give 50% dextrose IV
- Urgent, noncontrast brain CT (rule out blood or edema) if head trauma or focal neuro deficit
- Correct any hypothermia
- Check metabolic panel, drug screens

Coma: emergent care---headache, fever, stiff neck

- Urgent LP to rule out bacterial meningitis
- If focal signs or papilledema, get brain CT first to verify abscess or other mass lesion
- Empirical ceftriaxone 2 gm IV q 12 hrs

- If viral encephalitis suspected, get brain MRI, EEG, CSF PCR for *Herpes simplex*

You are called to the ER to see a 45 year-old man, who had a generalized tonic-clonic seizure in a local restaurant, and was brought in by the paramedics. The seizure spontaneously stopped in the ambulance, but he remained unresponsive. Upon arrival in the ER, another generalized seizure began, which lasted 15 minutes. As you begin to examine him, another generalized seizure starts.

What do you do?

Status epilepticus: treatment (1)

- Maintain A-B-C's at onset and during therapy
- EKG and oximeter monitoring
- Start IV access (saline), draw CBC, lytes, glucose, BUN, creat, AST, ALT, ? anticonvulsant levels
- Rule out hypoglycemia with fingerstick, or give 50% dextrose bolus urgently
- Send toxicology screen on urine or blood

Status epilepticus: treatment (2)

- Lorazepam 0.05-0.1 mg/kg IVP (<2 mg/min) or diazepam 0.15-0.25 mg/kg IVP (<5 mg/min)
- Load phenytoin 20 mg/kg (IV saline) (<50 mg/min), or fosphenytoin 20 (PE) phenytoin equivalents/kg IV (<150 mg/min)
 - (fosphenytoin, a prodrug of phenytoin, has less risk of hypotension, arrhythmia and skin reactions than phenytoin given IV)

Status epilepticus: treatment (3)

- If seizures persist, give 1 or 2 extra boluses of 5 mg/kg phenytoin or 5 PE/kg fosphenytoin IV
- If more seizures, load phenobarbital 20 mg/kg IV (<50 mg/min)
- Intubation & ventilation may be needed now
- Check that anticonvulsant levels are therapeutic
- Emergent EEG if patient doesn't wake up

Refractory status epilepticus: therapy

- Midazolam 0.2 mg/kg IV bolus, then 0.75 to 10 microgm/kg/min infusion, or
- Propofol 1 mg/kg IV bolus (can repeat), then 1-15 mg/kg/hr infusion, or
- Pentobarbital 5-15 mg/kg loading dose, then 0.5-5 mg/kg/hr
- Suppress electrical seizure activity on continuous EEG monitoring, watch for hypotension

Generalized status epilepticus (GSE)

- As GSE persists longer, motor movements become more subtle, and control more difficult
- Survivors may have cognitive or memory loss
- Mortality related to pt age, cause and duration of GSE
- Evaluate cause of GSE once seizures controlled: LP, CT or MRI brain scan

Status epilepticus : etiology

- Remote (chronic epileptics tend to recover)
 - trauma
 - previous infarct or hemorrhage
- Acute
 - encephalitis
 - tumor
 - acute hemorrhage
 - drug effect, metabolic disorder or anoxia

A 62 year-old woman is found on the floor of her apartment, awake but unable to get up. She cannot move her lower or upper limbs, even after painful stimuli, but has minimal shoulder movement.

What types of lesions in the central or peripheral nervous system could cause her problem?

- 1.
- 2.
- 3.
- 4.

Acute quadriplegic paralysis

- Pontine ischemic infarction
- Spinal cord lesion
 - Traumatic injury, transverse myelitis, ischemic infarct
 - Epidural spinal cord compression
- Guillain-Barre syndrome
- Neuromuscular junction disorder
 - Myasthenic crisis
 - Botulism

What are the typical bedside findings expected for each of these different causes of acute quadriplegia?

Acute quadriplegic paralysis

- Pontine infarction
 - locked-in syndrome, normal blink/upgaze, brisk reflexes
- Epidural spinal cord compression
 - back pain, level of sensory loss, urinary retention/incont
- Guillain-Barre syndrome
 - areflexia, NO level of sensory loss, normal sphincters
- Myasthenic crisis
 - Normal reflexes and sensation, ptosis, bulbar weakness

Metastatic spinal cord compression

- Vertebral (thor>LS>cerv) metastasis expands
- Usually back pain initially present
- Poor recovery if severe paralysis already exists
- Is a primary cancer pre-existent?
- Dexamethasone (10 mg), 4 mg IV q6 hrs
- Surgery/radiotherapy vs radiotherapy

Guillain-Barre syndrome

- Ascending, areflexic paralysis
 - also facial, ocular, respiratory or bulbar muscles
- Nerve demyelination on EMG, CSF protein elevated
- ICU care
 - respiratory failure, orthostatic hypotension, arrhythmias
- Plasmapheresis or IV immunoglobulin to hasten recovery
- Most eventually have a good recovery

Myasthenia gravis

- Variable paralysis of limb, ocular, bulbar and respiratory muscles
- ICU care: mechanically ventilate if needed
- Treat any concurrent infection
- Abnormal Tensilon test, AChR antibody, EMG
- Transient improvement with plasmapheresis or IV immunoglobulin
