

Genito-Urinary Examination

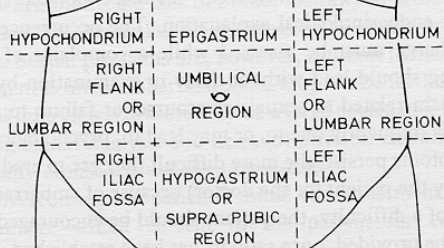
Robert C. Flanigan, MD

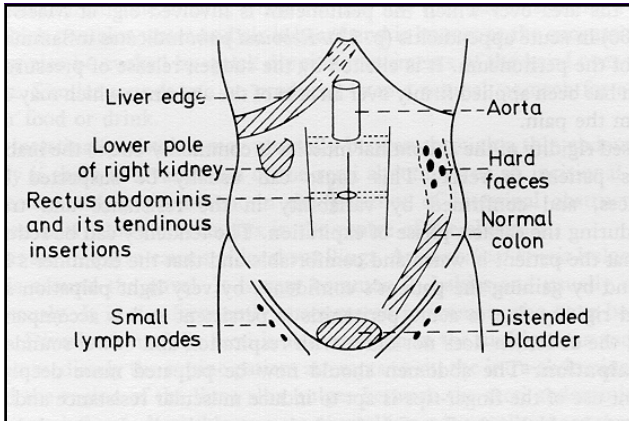
Albert J. Jr. and Claire R. Speh
Professor and Chairperson
Department of Urology
Loyola University Medical Center
Stritch School of Medicine

GU Organs

- ‡ Internal
 - Kidney
 - Ureter
 - Bladder
 - Prostate
 - Seminal vesicle
 - Vasal ampulla

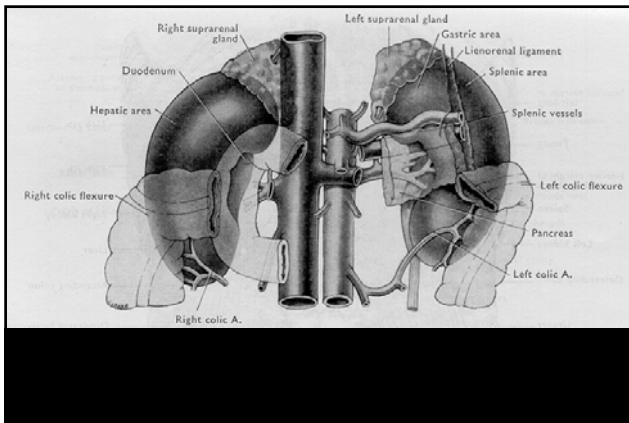
- ‡ External
 - Penis
 - Testis
 - Epididymis
 - Vas deferens
 - Spermatic cord

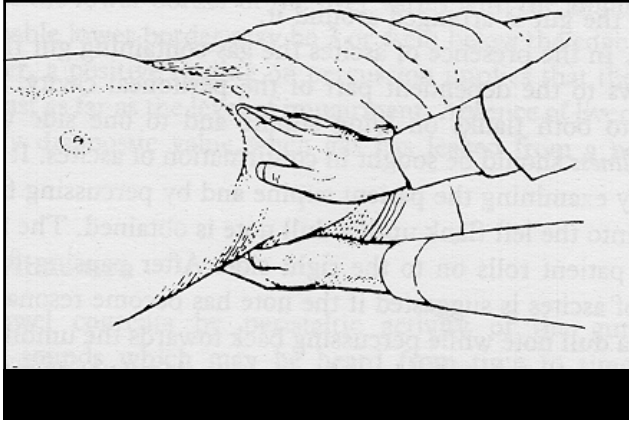


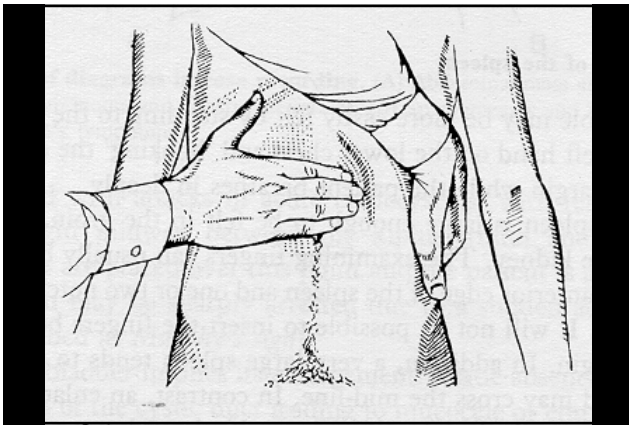


Kidney

- ‡ Palpable only in children and lean adults
- ‡ Enlargement
 - Hydronephrosis
 - Tumor
 - Perinephric pathology
- ‡ Renal pain
 - Palpate in CVA
 - Pyelonephritis
 - Urolithiasis





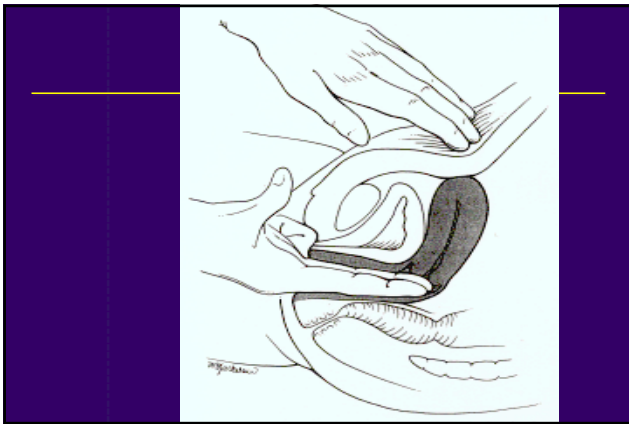


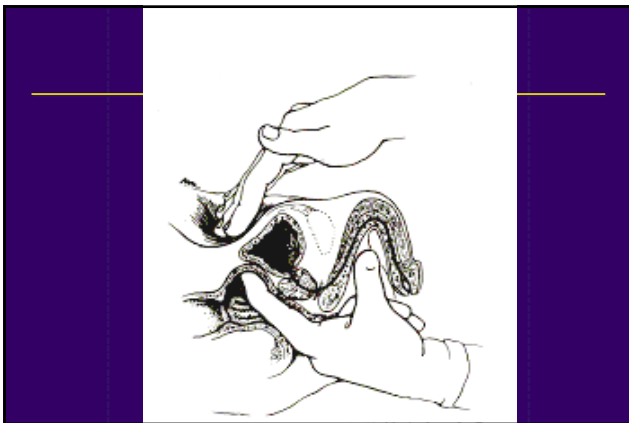
Ureter

- ⌘ Impalpable except when massively dilated in children
- ⌘ Traumatized by GSW and stabbing over a wide area of abdomen and back
- ⌘ Best examined radiologically

Bladder

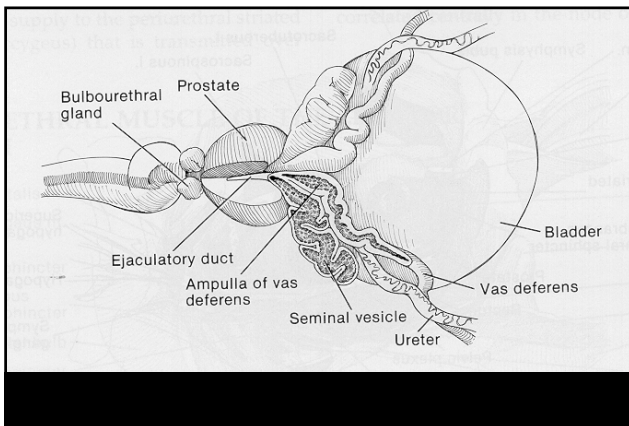
- ⌘ Extraperitoneal organ in adults
- ⌘ Palpable above pubis in midline
- ⌘ Dull to percussion
- ⌘ Compression elicits pain
- ⌘ Distension
 - Urinary retention
 - Displacement

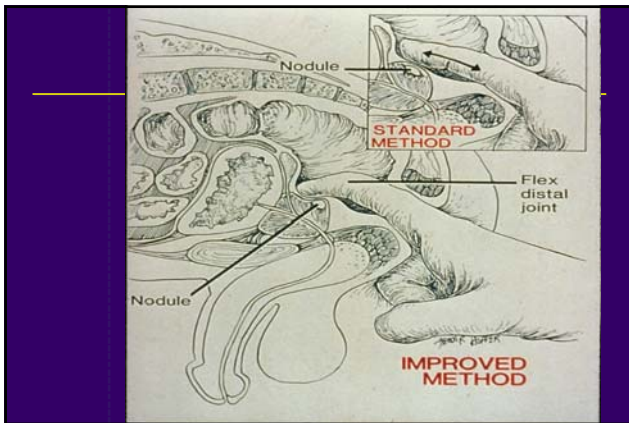


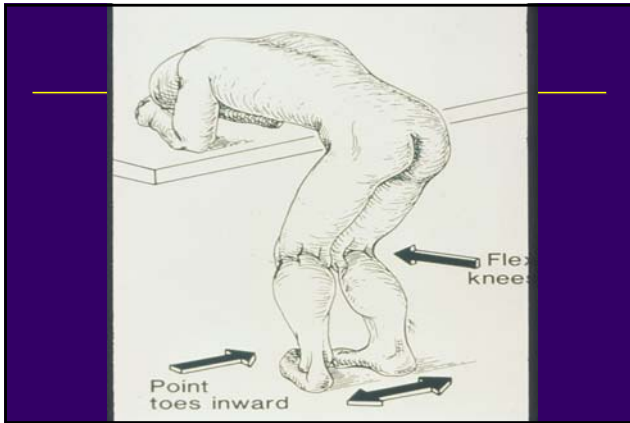


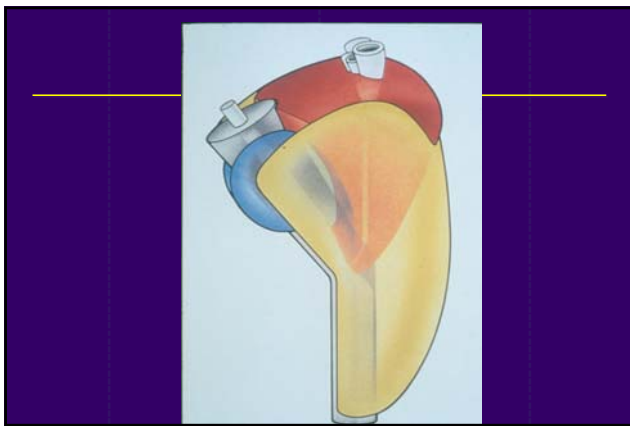
Prostate

- ⌘ Palpable by DRE
- ⌘ “Chestnut-sized, squash ball consistency”
- ⌘ Enlargement in 30’s
- ⌘ Examination
 - Position
 - Landmarks
 - Prostate features
- ⌘ Radiologic imaging









Seminal Vesicle

- ⌘ Impalpable except in rare cases
- ⌘ Lies postero-lateral to prostate
- ⌘ Function
- ⌘ Radiologic imaging
- ⌘ Enlargement
 - Tumor
 - Ejaculatory duct obstruction

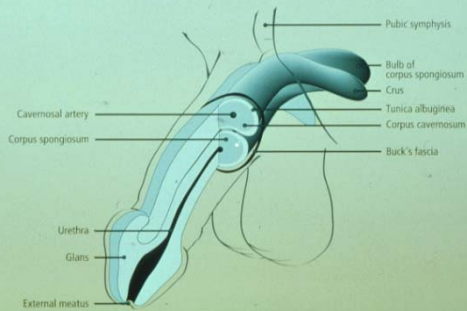
Vasal Ampulla

- ⌘ Impalpable except in rare cases
- ⌘ Lies posterior to prostate either side of midline

Penis

- ⌘ Anatomy
- ⌘ Abnormalities
 - Meatus
 - Prepuce
 - Skin
 - Erectile chambers

Penile Anatomy



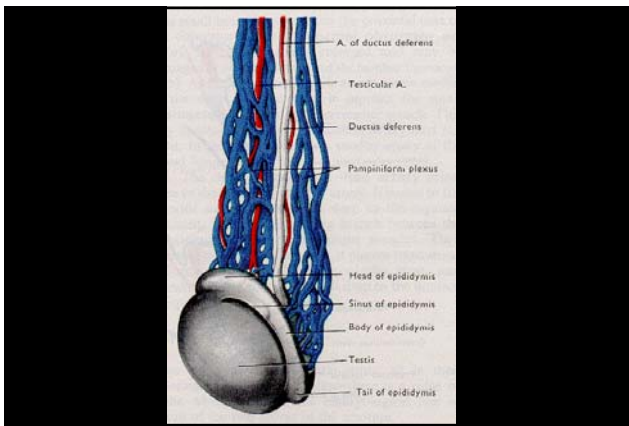
Testis

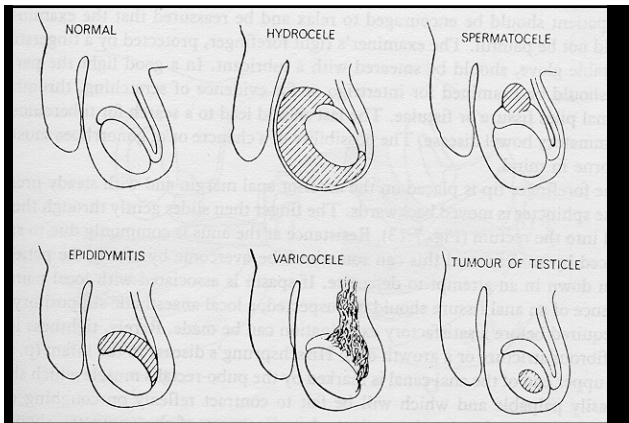
‡ Dimensions

‡ Consistency

‡ Enlargement

- Testis versus entire hemiscrotum?
- "Get above mass?"
- Tenderness?





Vas Deferens

- ‡ Difficult to palpate except through practice
- ‡ Fibrous, mobile cord
- ‡ Presence vs absence

Epididymis

- ‡ Posterolateral to testis
- ‡ Anatomic parts
- ‡ Enlargement
 - Inflammation/infection
 - Tumor
 - Obstruction

Spermatic Cord

- ‡ Varicose veins (Varicoceles)
- ‡ Lipoma
- ‡ Hernia

