

The Rheumatological Exam

R Kadanoff M.D
Loyola University Medical Center

History

- Acute vs Chronic
- Mono vs polyarticular
- Inflammatory or non-inflammatory

INFLAMMATION

- Pain
- Heat
- Red
- Swelling

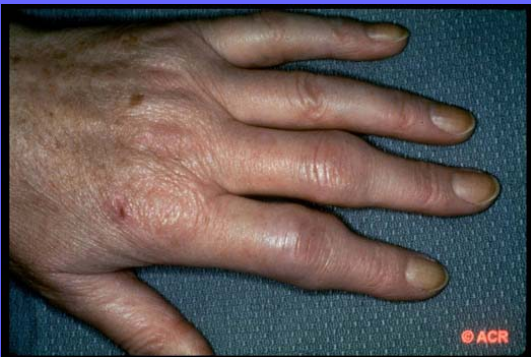- Duration of AM stiffness

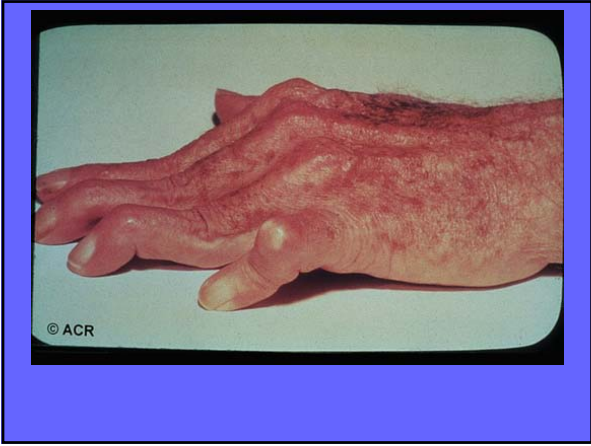Categories of Rheumatic Disease

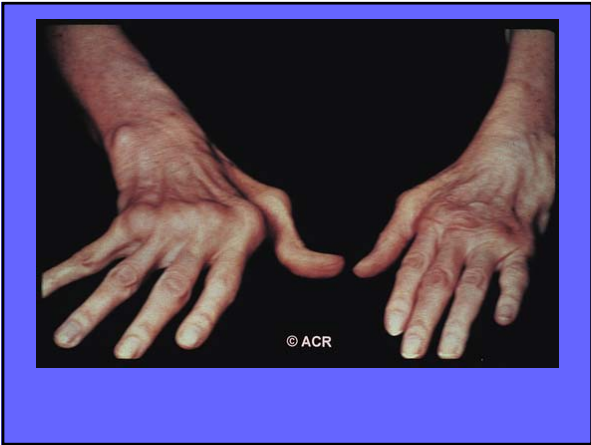Pathology	Prototype	Useful Test	Typical Rx
• Synovitis	RA	RF ESR	NSAID MTX
• Enthesopathy	A-S	S-I X-ray B27	Indocin
• Cartilage Deg.	OA	X-ray	Analgesic
• Crystal ind. Syn.	Gout	Fluid exam	Colchicine
• J. Infection	Staph	Fluid C&S	Antibiotics
• Myositis	PM	CK, Biopsy, EMG	Steroids
• Focal soft tissue	Tennis E.	None, X-Ray	Local
• General	Fibromyalgia	NONE	Exercise + Elavil + NSAID

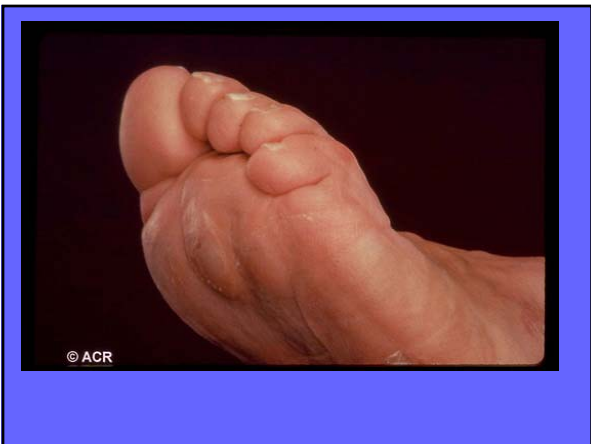RA

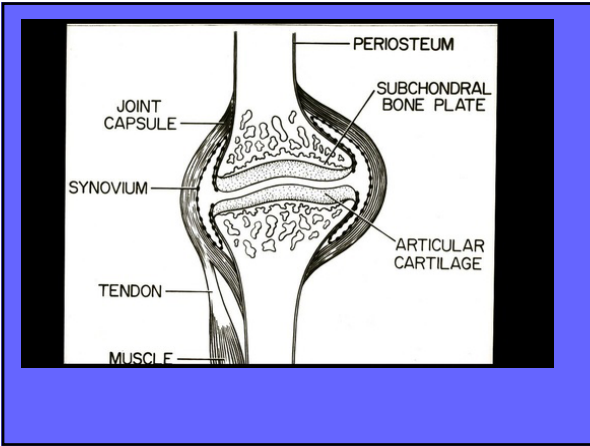
- **Inflammatory**
- systemic: anemia, tired, lack of energy
- polyarticular
- 70% insidious; 30% acute onset
- Distribution: symmetrical MCPs, PIPs, wrists
- Sjogren : sicca eyes, mouth, vagina, skin
- Felty spleen, low WBC, long standing RA
- Baker cyst
- CTS

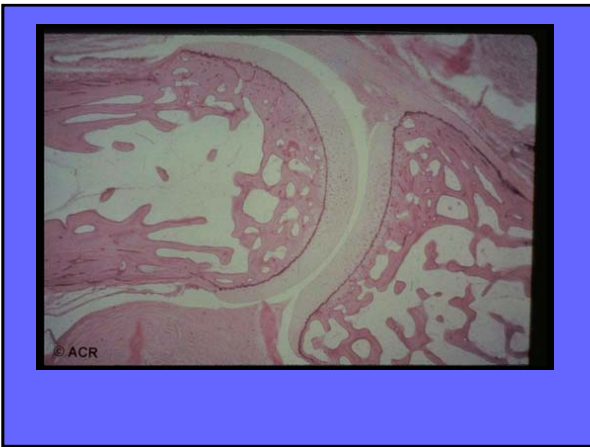


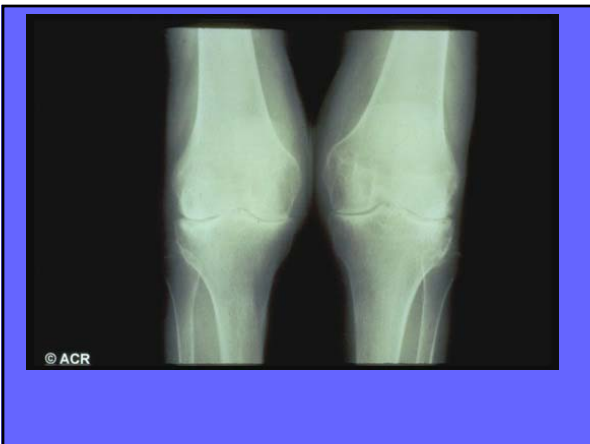











SLE

- Arthritis, Alopecia, Raynaud's, Photosensitivity
- Rashes; ANY but specifically malar (nasolabial fold sparing) and discoid.
- Easy bruising, anemia, low white count
- DVT, miscarriages, MI, strokes
- Mouth and nose sores
- Lung (SOB pain on inspiration), heart, and kidney (foaming urine, edema)
- Seizures, psychosis

PMR/TA

- Shoulder girdle stiffness and pain
- Bursitis in PMR in all by US
- Systemic: tired, anemic, etc
- Scalp tenderness, jaw claudication, temporal pain, visual changes in particular amaurosis fugax and HEADACHE
- RA questions
- Rx: steroid 10mg/day for PMR; 80 for TA
- Tinnitus (more Wegener)

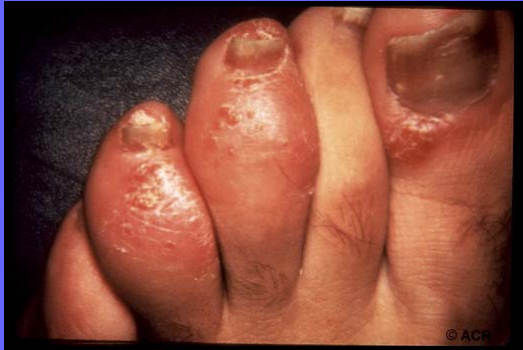Spondyloarthropathies

Associated conditions

- Psoriasis
- IBD, Erythema Nodosum
- STD, Dysentery
- Iritis, Enthesopathy
- Low back pain, stiffness
- S-I joint pain

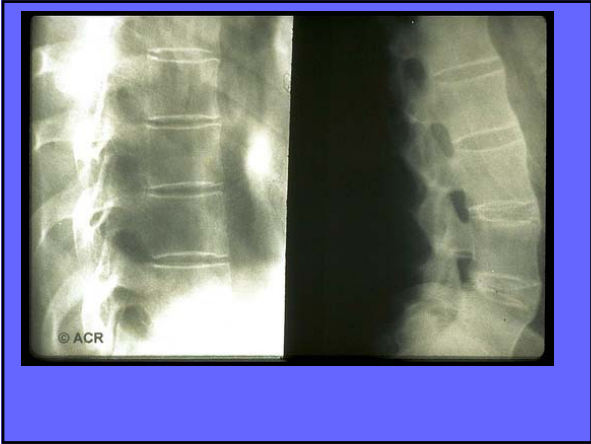Distribution in Spondyloarthropathy

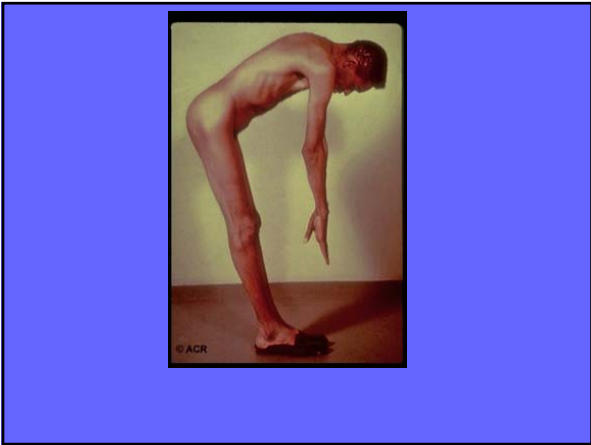- Psoriatic can be with/without back involvement
- Symmetric; like RA
- DIP with nail involvement
- Asymmetrical “sausage” digits
- Can be with or without skin involvement
- Peripheral arthritis activity correlates with skin or bowel disease activity.

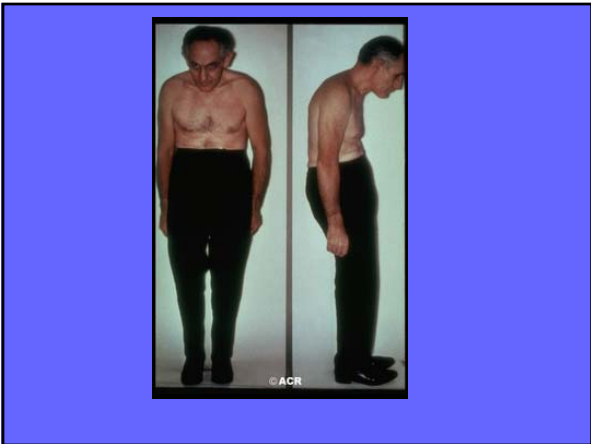

Back Pain in spondylo

- Improves with exercise
- IN A-S, IBD involvement goes from bottom to top. In PA and Reiter, skips
- Schober test positive
- S-I maneuvers positive
- S-I asymmetrical in R PA

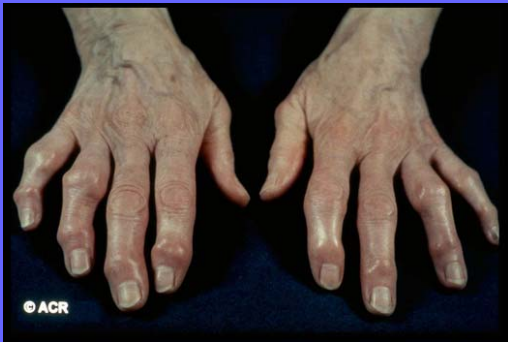


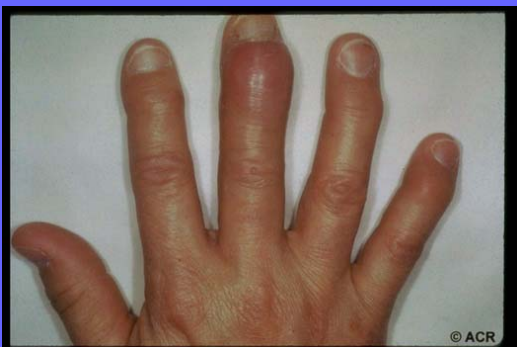


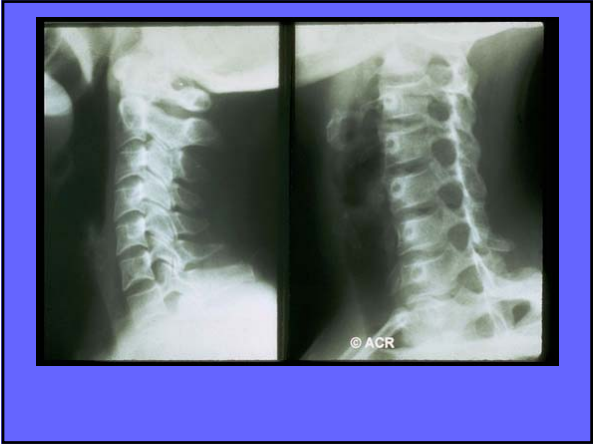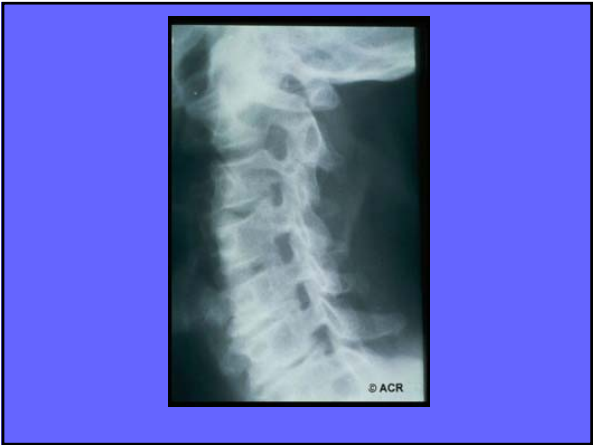OA-DJD

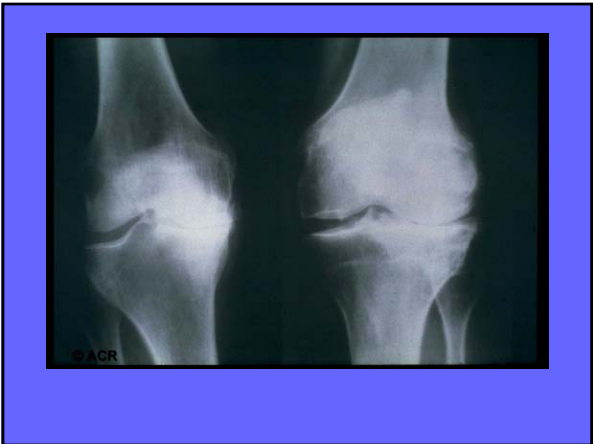- Distribution: knees, back, neck
- Traumatized joints
- Stiff 1/2 hour, jells
- Pain worse at end of day
- Early no night pain, no pain at rest
- Cartilage worn
- Treatment, gentle ROM, analgesics, injection, joint replacement





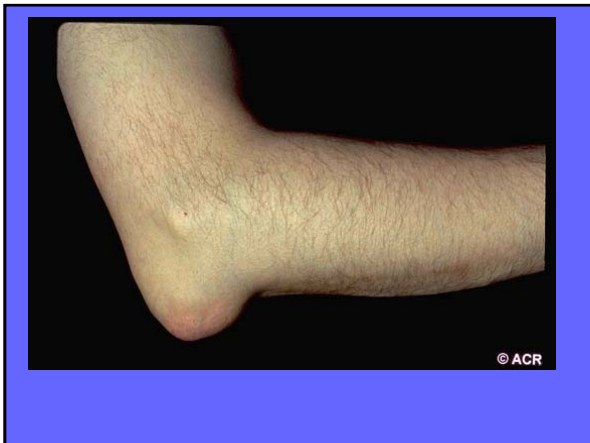





Gout & Pseudogout

- Gout is mostly acute; lasts 5-10 days
- Can be on top of chronic, intercritical
- Pseudogout acute lasts longer
- Is on top of OA and pseudorheumatoid, chronic.
- Surgery common antecedent.
- Distribution.



Joint Infection

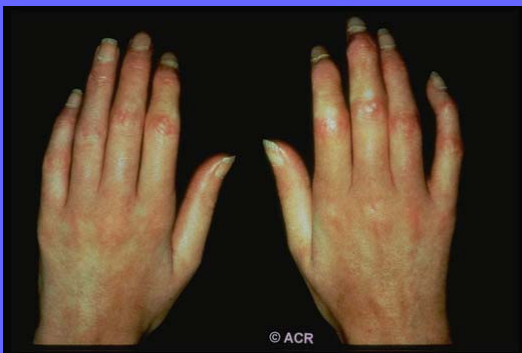- Non-Gonococcal; rapid, destructive
- Gonococcal; rapid, non-destructive
- TB and Fungal; slow, chronic, & destructive

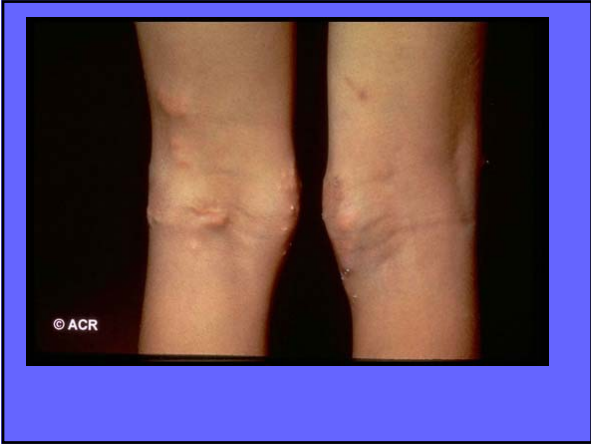
Synovial Fluid Analysis

	class I	class II	class III
color	Clear/yellow	Yellow/white	Yellow/white
clarity	transparent	Translucent/ opaque	opaque
viscosity	high	variable	low
Mucin clot	firm	variable	friable
WBC	<2000	2000- 100,000	>100,000
differential	<25%PMN	>50% PMN	>95% PMN
Culture	Negative	Negative	Positive
crystals	none	+/- crystals	+/- crystals

Myositis

- Polymyositis: proximal weakness, 40% time starts with some pain too. Combing hair, getting up from chair without hands.
- Dermatomyositis (path more perivascular) Gottron patches, heliotrope rash
- Myositis with SLE, Scleroderma
- PM & DM associated with malignancy; DM is at least 25%.
- Childhood dermatomyositis: more vasculitis, coxsackie infection related.





Focal conditions

- Tendonitis
- Bursitis
- Cervical radiculitis
- Carpal tunnel: TSH, ? Immune fixation, ascending
- De Quervain tenosynovitis
- Local measures: splints, PT, local injection of steroids, NSAIDs

Low back pain

- Schober will be positive too.
- Stiffness does not improve, is not worse in AM
- Worse with bending and standing
- Low back pain treatment: analgesic and rest a couple of days, then activity as tolerated.

- Age > 50: plain film to R/O cancer
- Neurological findings: MRI as may need surgery

Bone Pain

Thoracic spine

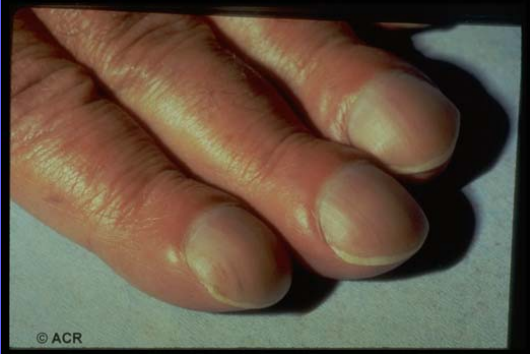- Metastatic cancer
- Multiple myeloma
- Osteoporosis and compression fractures

Long Bone

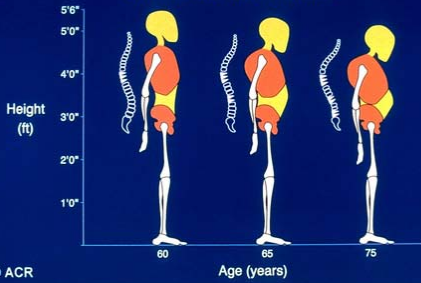
- Sarcoid

Periosteal Elevation

- Osteomyelitis
- Hypertrophic Osteodystrophy
 - lung cancer, liver disease, lung disease



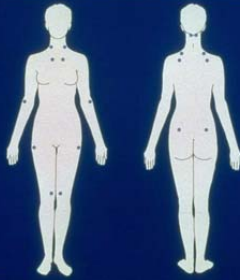
Spinal Osteoporosis Location of Bone Fractures



Fibromyalgia

- HA Hx
- Irritable BD
- Costochondritis
- Poor sleep
- No exercise
- Depression
- Family Hx

Fibrositis (Fibromyalgia): Tender Points



Extraarticular organs in rheumatological diseases

- Skin
- Eye
- Arteries
- Lung
- Heart
- Kidneys
- Muscle
- Bursae

Skin

- Rashes in SLE (ears)
- Sun sensitivity: SLE & dermatomyositis
- Erythema Nodosum: (strep, IBD, sarcoid)
- Erythema marginatum and circinatum
- Erythema chronicum migrans
- Purpura - (Henoch Schonlein)



Ocular

- Spondylo
- Behcet
- RA
- Temporal arteritis

Joint Exam

- Swelling
- Instability
- Deformity
- ROM
