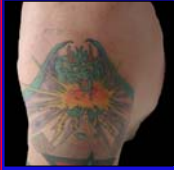

Examination of Shoulder & Elbow



Guido Marra MD
Department of Orthopaedic
Surgery and Rehabilitation



Shoulder Pathology

Common
Pain
Loss of function
↑ Incidence with age

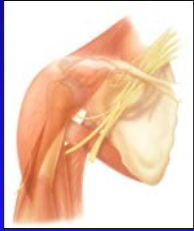
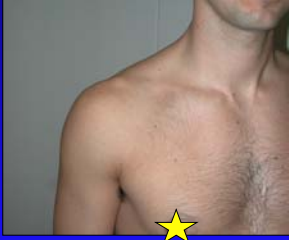Diagnosis NOT ALWAYS EASY

Physical Examination

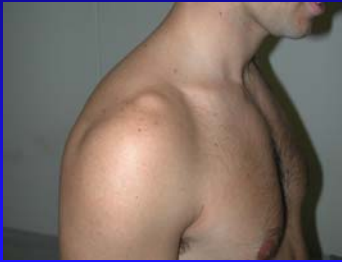- Inspection
- Range of motion
- Palpation
- Special testing
- Strength Grading



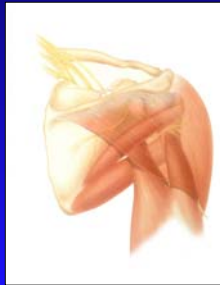Superficial Anatomy



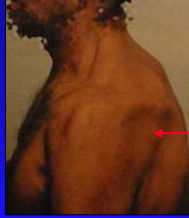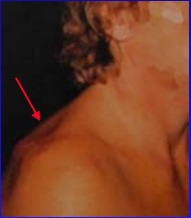Superficial Anatomy



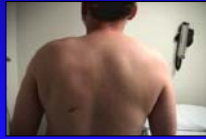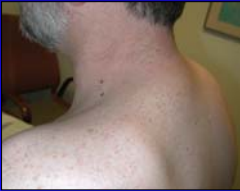Superficial Anatomy



Supraspinatus/ Infraspinatus Atrophy

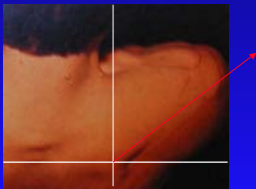

Trapezial Palsy



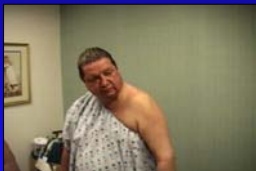Range Of Motion

Confusion



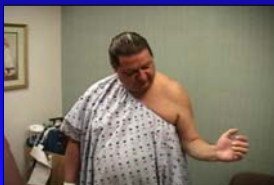Elevation

- Normal 0-180 degrees
- Plane of the scapula



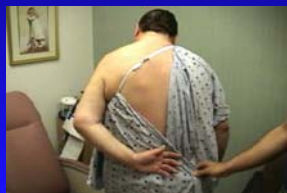External Rotation

- Measure in adduction
- Normal 0-80 degrees
- Restriction
 - Adhesive Capsulitis
 - Osteoarthritis



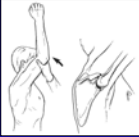Internal Rotation

- Measured from spine

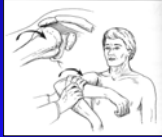

Rotator Cuff

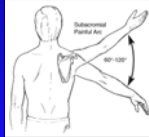
- Impingement signs



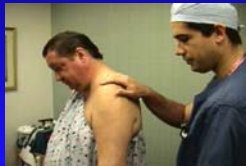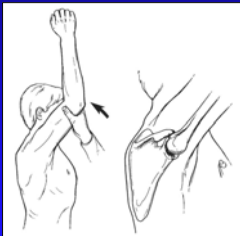
Neer

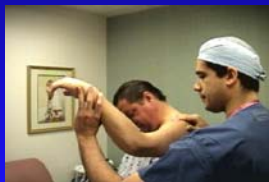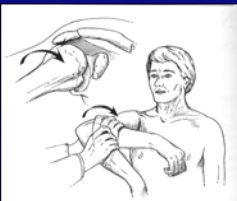


Hawkins



Painful arc



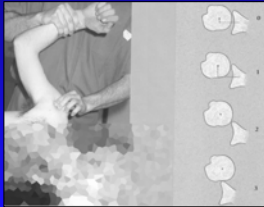

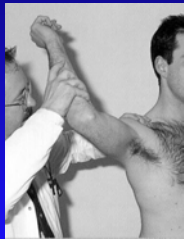Biceps tendon

Speed's Test
Yergason's Test

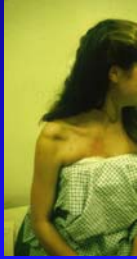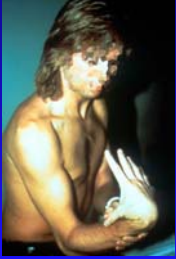Instability

- Load Shift

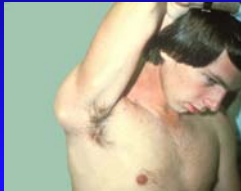
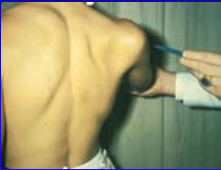


Hyperlaxity



Posterior Instability



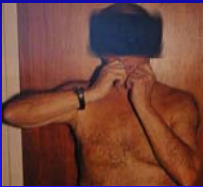Strength Grading

- Grade 5 Normal strength
- Grade 4 Decreased resistance
- Grade 3 Resist gravity, no resistance
- Grade 2 Motion with gravity eliminated
- Grade 1 No motion, palpable contracture
- Grade 0 No motion no contracture

Elevation

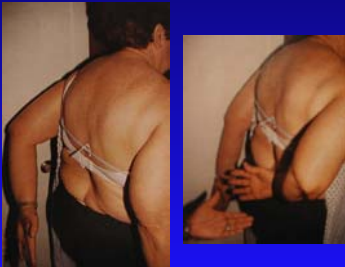- Rotator cuff
- Deltoid
- Can empty?

External Rotation

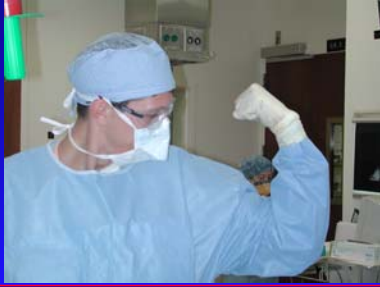

Internal Rotation

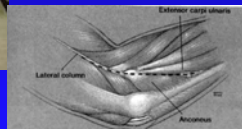
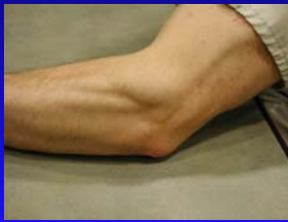- Lift-off



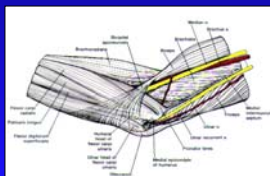
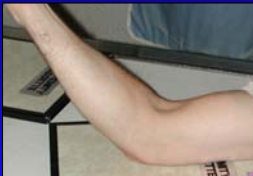Elbow



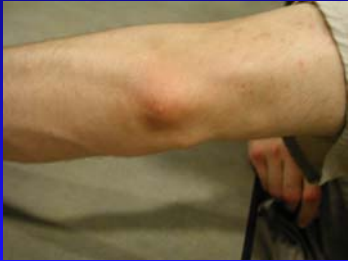Superficial Anatomy



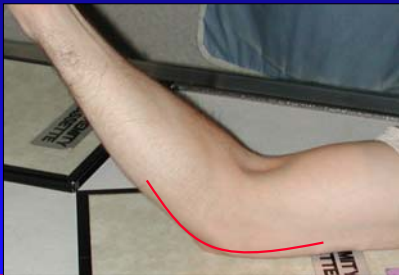Superficial Anatomy



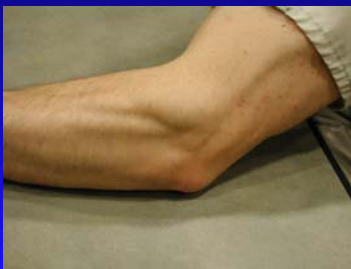Superficial Anatomy



Percussion of Ulnar Nerve



Tennis Elbow



Thank you

